

PRENATAL DEVELOPMENT OF THE GUINEA PIG KIDNEY QUANTITATIVE AND QUALITATIVE MORPHOLOGY

By

ZEINAB M. A. EL GOHARY

Department of Zoology, Faculty of Science, University of Qatar, Doha, Qatar

مراحل تكوين الكلية في أجنة أرنب غنيا : كماً وكيفاً

زينب محمود أحمد الجوهري

تناول هذا البحث فحص ودراسة المراحل الجنينية لكلىة أرنب غنيا كيفاً وكماً حيث تم تتبع مراحل نمو كريات ملبيجي والأنبوبة الكلوية القريبة على فترات تشمل الثلث الأخير من فترة الحمل لحيوانات التجارب . ولقد تمت مقارنة تركيب كرية ملبيجي من الناحية الهستولوجية وكذا تم تعيين معدل النمو الكلوي لأجنة أرنب غنيا بتحديد عدد كريات ملبيجي وقياس حجمها وطول الأنبوبة الكلوية القريبة على فترات متتالية ما بين يوم ٤٦ إلى يوم ٥٥ من الحمل . وقد اوضحت الدراسات ان عدد كريات ملبيجي وكذا حجمها الكلي يزداد زيادة ملحوظة في الفترة ما بين اليوم ٤٦ إلى اليوم ٥٥ من الحمل بينما كان زيادة طول الانبوبة الكلوية القريبة واضحاً من اليوم ٥٥ - ٦٦ من الحمل . وقد دلت المشاهدات أيضاً ان الوحدة الكلوية يكتمل نموها من الناحية التركيبية أثناء فترة النمو الجنيني لحيوانات التجارب أي ما قبل الولادة .

Key Words: Kidney intrauterine development mammals.

ABSTRACT

The normal prenatal development of the guinea pig kidney was investigated utilizing quantitative and qualitative histologic methods and microdissection technique during the last of the gestation period (day 46 to day 66). From day 46 up to day 55 of gestation, the differentiation of the newly formed nephrons within the superficial renal cortex was the main morphologic change. The number of glomeruli increased markedly during this period, while both the glomerular volume and the proximal tubular length of the juxtamedullary nephrons did not change. Several generations of glomeruli that surrounded by tubule sections were localized in the deeper cortex between day 55 and 60 of the gestation. Later (day 61 to 66) this region showed inward-growing loops in the area that became medullary rays. The tubular density as well as their diameters gradually increased in all cortical layers. From day 55 onward, the major morphologic change was the marked lengthening of the proximal tubules of the juxtamedullary and superficial nephrons. A subcapsular nephrogenic zone completely disappeared around day 56 to day 60 of gestation; indicating completion of nephrogenesis.

INTRODUCTION

The quantitative and qualitative morphology of the developing kidney has been extensively studied in the cat (Huber, 1905), the human (Huber, 1905 and Potter, 1972), the hamster (Leeson, 1961), the rabbit (Ishii, 1970), the rat (Larsson, 1975), the dog (Eisenbrandt and Phemister, 1979) and the pig (Friis, 1980). These studies revealed that nephrogenesis is not complete at birth in most mammals, resulting in a relatively lower efficiency of the kidney in new born animals than adults (Nash and Edelman, 1973 and Loggie *et al.*, 1975). Nephrogenesis is apparently complete at

about 10 days postnatally in rabbits (Perey *et al.*, 1967), rats (Goncharevskaya and Dlouha, 1975), and dogs (Eisenbrandt and Phemister, 1979) and at 21 days in pigs (Friis, 1980). In contrast, nephrogenesis in guinea pigs (Spitzer and Brandis, 1974; Merlet-Benichou *et al.*, 1981), like humans (Potter and Thierstein, 1943) and cattle (Cad-Treyer and Tsuji, 1975) is complete before birth, and functional renal maturation proceeds rapidly in the first postnatal month (Chevalier and Gomez, 1988).

Only single report concerning the quantitative morphology, along with functional pattern of the developing guinea pig

kidney (Merlet-Benichou *et al.*, 1981), presents data for prenatal and postnatal developing kidney. The purpose of the present work therefore, was to provide a more complete quantitative description of the morphology of the guinea pig kidney during prenatal development. Another purpose was to indicate the gestational age at which nephrogenesis was completed in the developing guinea pig kidney.

MATERIALS AND METHODS

1) Experimental animals:

Ten pregnant female guinea pigs of known mating dates were used. The pregnant guinea pigs were anesthetized with light ether and the kidneys were removed from 29 developing embryos at four different stages between days 46 and 66 of gestation.

2) Quantitative and qualitative studies:

Four groups of fetuses ranging in age from day (46-50), (51-55), (56-60) and day (61-66) of gestation were used. For histological study. Right kidneys of 3-5 fetuses of each studied stage were fixed in 10% neutral formaline, dehydrated in an ascending series of ethyl alcohol, cleared in xylol, embedded in paraffin wax and sectioned at 5-7 μ m thick. The sections were then stained with Harris's haematoxylin and eosin. Kidney sections were histologically examined, two right angle of 20 glomeruli of each studied stage were measured under a microscope fitted with an ocular micrometer eyepiece (Solomon, 1974). Glomerular volumes were calculated from glomerular diameters (the glomeruli were treated as spheres).

The total glomerular volume (as an index of the filtering surface area and consequently the glomerular filtration rate (GFR) was computed by multiplying the mean glomerular volume by the number of glomeruli in whole kidney.

The left kidneys were used for microdissection. Small blocks of neutral formaline fixed renal tissue were macerated in 50% HCl. The nephrons were dissected with thin needles under a dissecting microscope, after which the proximal tubules and glomeruli were drawn at a magnification of X 100 with the aid of a camera lucida attached the microscope. The proximal tubular length was measured on the drawings with the curvimeter.

For counting the nephrons, 50 mg. of renal tissue from the kidneys of two fetuses of each examined stage were macerated in equal parts of concentrated hydrochloric acid and water following Damadian's method (Damadian *et al.*, 1965).

RESULTS

1. Qualitative morphology:

The peripheral layer of the renal cortex between day 46 to day 55 of gestation still occupied only a thin nephrogenic zone in the outer one-fourth of the cortex. This zone consisted of two types of primitive nephrogenic cells several morphologic stages of forming nephrons, and differentiated interstitial tissue. The two types of primitive cells were ampullary cells and mesenchymal cells (Fig. 1). Ampullae were located in the outer portion of the nephrogenic zone and constituted the extremities of collecting tubules. Mesenchymal cells formed the metanephric blastema, metanephric caps, and differentiated into interstitial tissue. The morphologic stages of forming nephrons includes renal

vesicles and "S" shaped bodies (Fig. 2). The renal vesicles were oval in shape lining with large cells oriented radially. At a later developmental stage, indentation of the renal vesicle created an S-shaped structure. The lower indentation of the S-shaped structure became a definite cleft and the entire lower limb formed a double-layered hemisphere beneath the tubular, upper segment (Fig. 3). The cells of the outer layer of the hemisphere were flattened and thus began to resemble the future Bowman's capsule, while the cells of the inner layer, the future vesicular epithelial cells were columnar. The upper limbs of the S-shaped body consisted of the future tubular portion of the nephron. Small formed corpuscles were located immediately beneath the nephrogenic zone while corpuscles of increasing size and maturity were located in successively deeper cortical levels. From day 51 to day 55 of gestation the nephrogenic zone was reduced due to a decrease in nephrogenic activity (Fig. 4). Later, around the 60th day of gestation, several generations of glomeruli, all of them surrounded by renal tubule sections were observed within the renal cortex (Fig. 5). The glomerulus was spherical or oval and a distinct Bowman's space and a few capillary loops were present (Fig. 6). With the exception of the presence of inward-growing loops in areas that later became medullary rays (Fig. 7). The appearance of the deep cortex did not change greatly between 56th and 60th day of gestation. On the other hand, the most striking change observed in the peripheral cortex during this period was the total absence of the nephrogenic zone, indicating the completion nephrogenesis (Fig. 8). From day 61 to day 66, the outer layer of the renal cortex was occupied by well-differentiated glomeruli with very few renal tubular sections, after which the tubular density increased in all cortical layers. During this period, four sequential generations of nephron populations were found (Fig. 9). The glomeruli located closer to the juxtamedullary region were larger and stained more intensely. As the result of the growth of the convoluted tubules of the superficial nephrons, a subcapsular tubular zone without glomeruli was formed (Fig. 10). Glomerular differentiation followed centrifugal pattern. With increasing maturity the visceral epithelial cells of glomeruli became more squamous and the capillaries became more prominent. In addition to glomerular maturation, extensive tubular growth occurred during renal development.

2) Quantitative morphology:

a) Number and volume of glomeruli (Table 1):

The number of glomeruli increased markedly between days 46 and 55 but low between day 56 and day 66 of gestation. Although, the glomerular volume did not increase within the whole period studied, the total glomerular volume increased markedly during this period.

Table 1

Number of glomeruli (No. G), glomerular volume (Vol. G), and proximal tubular length of juxtamedullary (JM) and superficial (S) nephrons in fetal guinea pigs

Age days	No. G.	Vol. G. m ³	Length of (JM) mm	Length of (S) mm
(46-50)	38,231	(JM) 0.098 (S) 0.65	0.97	---
(51-55)	41,432	(JM) 0.21 (S) 0.19	1.5	1.1
(56-60)	81,102	(JM) 0.42 (S) 0.22	1.9	1.6
(61-66)	84,324	(JM) 0.51 (S) 0.28	2.3	1.9

Note: Length of proximal tubule of superficial nephrons was difficult to be measured at age 46-50 day of gestation.

b) Proximal tubular length:

The proximal tubular length of the juxtamedullary nephrons did not change between day 46 and so of 55 of gestation (Table 10), but the lengths of the proximal tubules of both superficial and juxtamedullary nephrons increased greatly from day 56 onward.

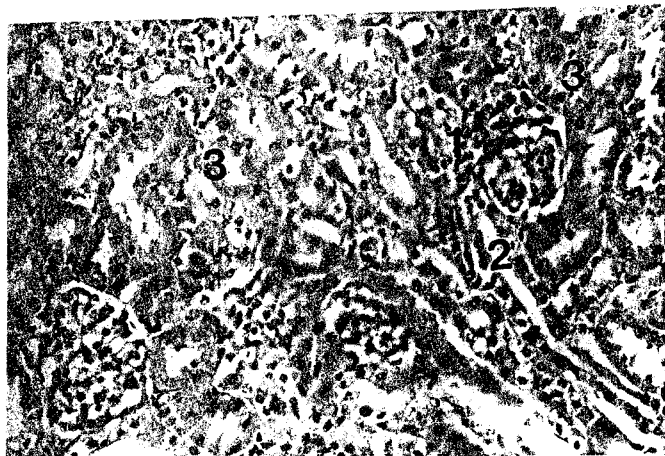


Fig. 1: Photomicrograph of a transverse section through subcapsular renal cortex of guinea pig embryo 46 day of gestation, showing the metanephric blastema (1) and collecting tubules (2) with terminal ampullae. Also renal vesicles (3) are presented. H & E

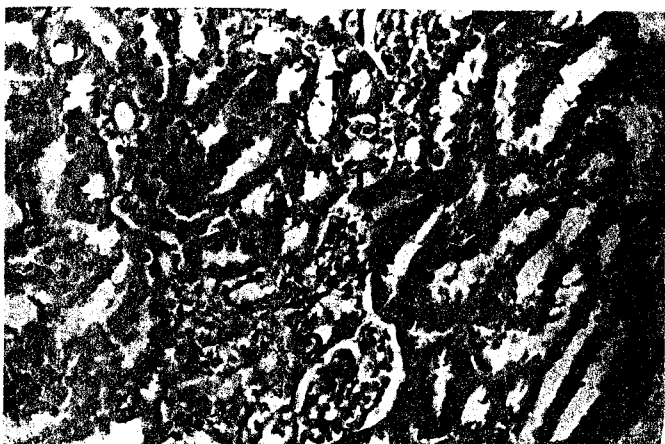


Fig. 2: Photomicrograph of a transverse section through the nephrogenic zone of guinea pig embryo at day 50 of gestation, showing renal vesicle (1) and an S-shaped structures (2). H & E

DISCUSSION

The mammalian kidney develops from the union of the ureteric bud with the metanephric blastema (Potter, 1972). The ureteric bud forming the ureter, pelvis and collecting tubules and inducing the formation of nephrons within the metanephric blastema. New nephrons arise by a very complex process of differentiation which involves well-defined developmental stages morphologically. The first nephron anlage, the renal vesicle, is transformed to the S-shaped body which connects to the collecting tubule and further differentiates into the mature nephron. The upper part of the S-shaped body (the prospective distal tubule) was connected to the collecting tubule, while the lower part formed the glomerular anlage.

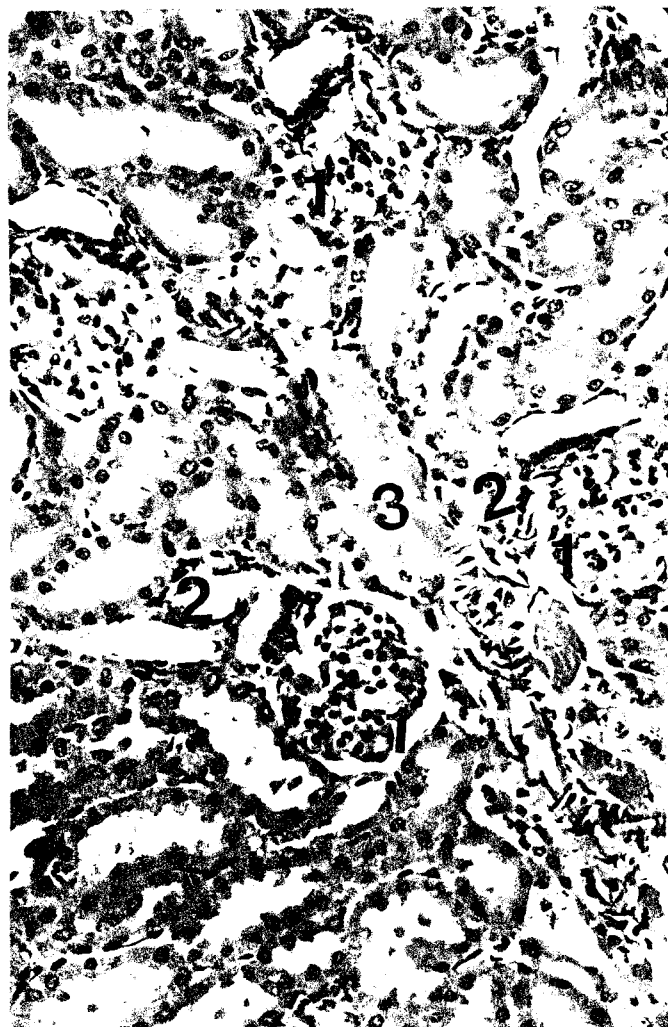


Fig. 3: Photomicrograph of a transverse section through the renal cortex of the guinea pig embryo at day 50 of gestation. Note the lower limb of the S-shaped structure forms a double-layered hemisphere (1) beneath the tubular upper segment (2). Note also the junction of the tubular segment of the S-shaped structure and ampulla (3). H & E

In the present study, new differentiated superficial glomeruli appeared from day 51 to day 55 of gestation. From day 56 to day 60, there was no great change in the appearance of the deep renal cortex, which was consistent with the finding that the glomerular volume of the juxtamedullary nephrons did not change throughout the period of study. From day 55 to day 66 of gestation, the morphologic pre-natal renal maturation involved marked lengthening of the proximal tubules of both superficial and juxtamedullary nephrons without changes in the volume of the glomeruli of both nephron populations. The nephrons showed a gradient in the degree of development with the mature nephrons in the juxtamedullary area and the immature nephrons toward the capsule. The results of the present study in the fetal guinea pig kidney revealed that the induction of new nephrons ceased by day 61 of gestation when no S-shaped forms persisted in the developing renal cortex. Therefore, the subcapsular nephrogenic zone in prenatal developing guinea pig kidney disappears around day 56 to day 60 of gestation. Similarly, Merlet-Benichou *et al.*, (1981) reported that nephrogenesis was complete around day 55 to 61 of gestation

in fetal guinea pig kidney. Also, new nephron formation does not occur after birth in either guinea pigs (Spitzer and Brandis, 1974) or cattle (Cader-Treyer and Tsuji, 1975). Moreover, nephrogenesis in humans ceases prior to birth if the infant is of average size and gestation is of average duration (Potter and Thierstein, 1943). On the other hand, nephrogenesis continuous until 10-14 days of postnatal age in mice (Guttman and Kohn, 1963), rabbits (Perey *et al.*, 1967), and rats (Goncharevskaya and Dlouha, 1975).

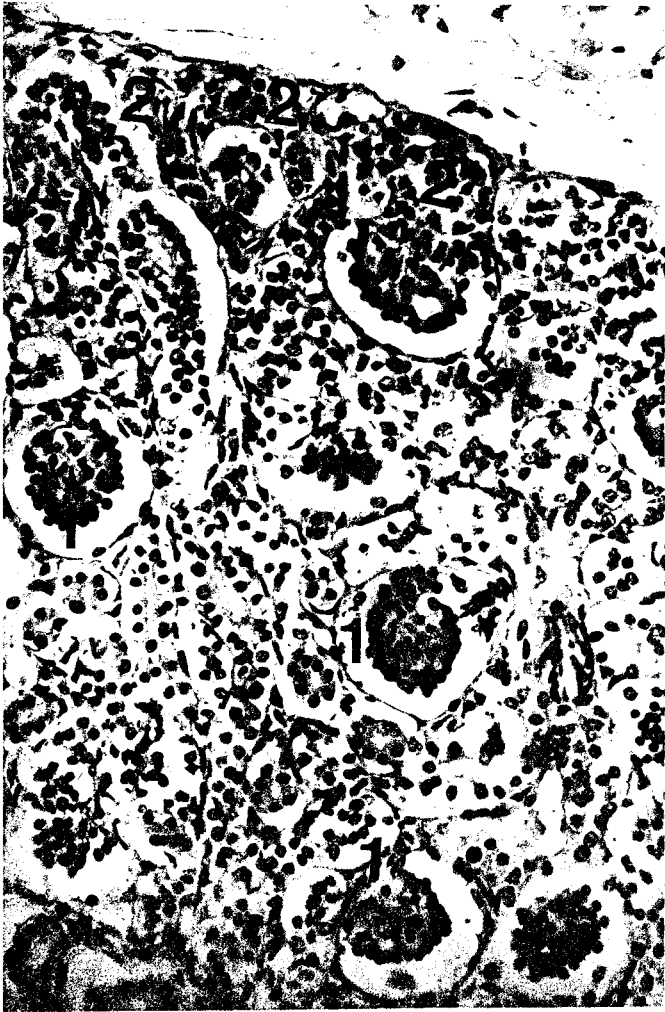


Fig. 4: Photomicrograph of a transverse section through the renal cortex of the guinea pig embryo at day 55 of gestation. Note renal corpuscles of increasing size and maturity (1) which localized in successively deeper cortical levels. Also note reduction of thickness and activity of nephrogenic zone (2). H & E

In the present study, the histologic features of nephrogenesis in the developing guinea pig are identical to those reported in man (Potter, 1972) and dogs (Eisenbrandt and Plemister, 1979). Within the subcapsular nephrogenic zone, the outer actively growing portion of the ureteral buds (ampullae) induce the metanephric mesenchyme to differentiate. Several stages of developing nephrons are recognized and include metanephric caps over ampullae, renal vesicles, and S-shaped structures, as well as immature renal corpuscles and tubules. Growth and maturation of the kidney continues long after nephrogenesis has ceased.

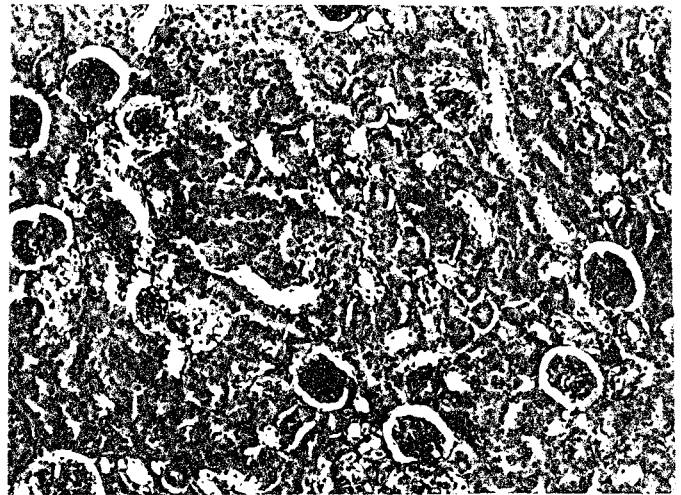


Fig. 5: Photomicrograph of a transverse section through the renal cortex of the guinea pig embryo at day 56 of gestation, showing the various generations of glomeruli, all of them surrounded by renal tubule sections. H & E

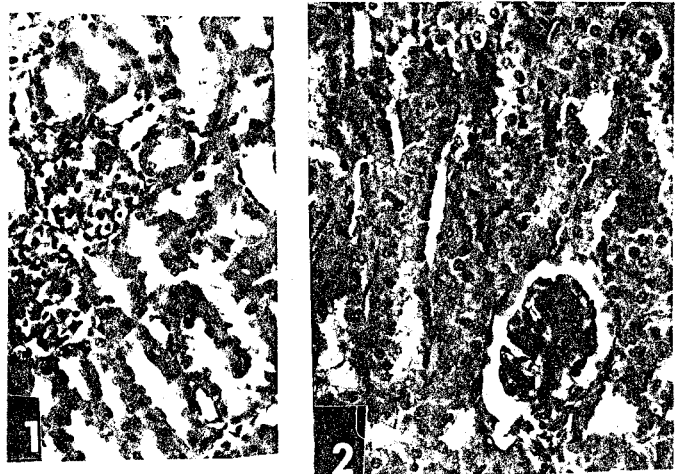


Fig. 6: Photomicrograph showing recently formed immature corpuscle (1) subjacent to the nephrogenic zone. The visceral epithelial cells are cuboidal to columnar and closely apposed. Also, note the mature renal corpuscle (2). H & E

Nephrogenesis proceeds in a centrifugal pattern; the oldest nephrons were located in the juxtamedullary area and the youngest in the superficial cortex. This renal pattern is similar to that seen in the developing rats (Bonvalet *et al.*, 1972; Nash and Edelmann, 1973) and dogs (Eisenbrandt and Plemister, 1979). The medulla consisted of tubules dispersed in a prominent matrix of immature connective tissue. The density of these tubules increased with age. Tubular growth was evident in the outer medulla. Growth and maturation of convoluted tubules in the outer cortex resulted in the formation of a subcapsular tubular zone devoid of corpuscles.

Histologic observation of the renal cortex in the 46 to 54-day fetus showed that the peripheral layer was still occupied by differentiating structures such as vesicles and S-shaped bodies. In the deeper cortex, several generations of glomeruli were present, all of them surrounded by tubule sections. Such results are in agreement with the observations

of (Huber, 1905; Jokelainen, 1963 and Merlet-Benichou *et al.*, 1981).

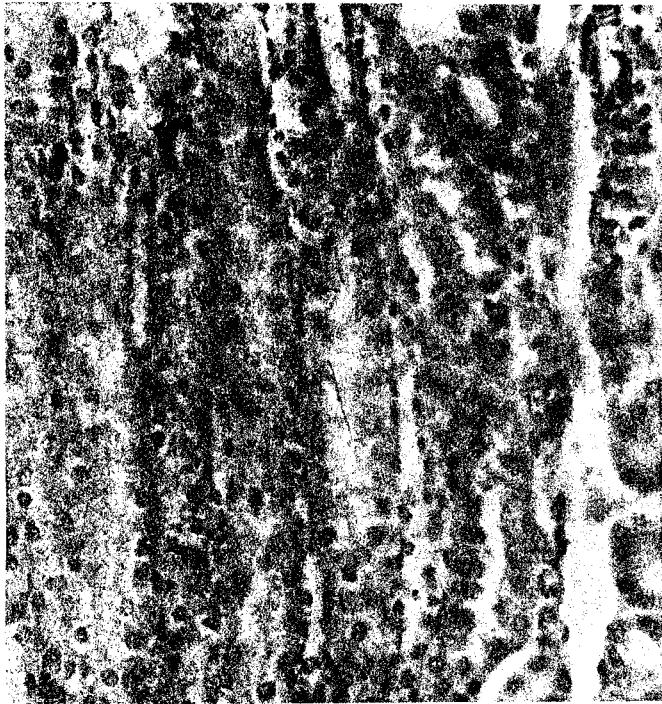

Fig. 7: Photomicrograph of a transverse section through the deep cortical region of guinea pig embryo at day 60 of gestation showing inward-growing tubules. H & E




Fig. 8: Photomicrograph of a transverse section through the cortical region of the kidney of guinea pig embryo at day 61 of gestation showing completely absence of the nephrogenic zone. H & E.

The anatomical data of the present study are consistent with the physiological observations of Merlet-Benichou *et al.* (1981) who found that a significant increment in both the filtered and the reabsorbed amounts of water, total solutes and sodium occurred during the period from 45th to 60th days of gestation in guinea pig; findings which suggest increased numbers, total volume of glomeruli and length of renal tubules during this period of development.

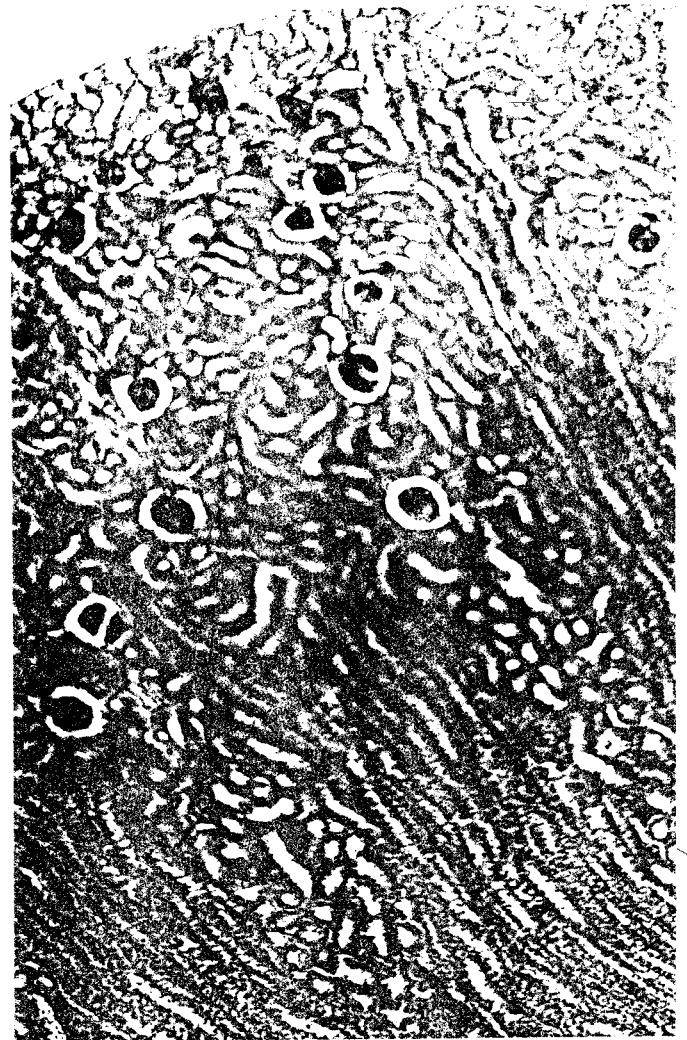


Fig. 9: Photomicrograph of a transverse section through the outer region of the renal cortex of guinea pig embryo at day 66 of gestation showing well differentiated glomeruli. Note three sequential generations of nephron populations according to their location within the renal cortex. H & E

Utilizing a kidney maceration technique, Dammadian *et al.*, (1965) estimated the number of nephrons in the fetal guinea pig kidney at different stages of development to be 38,231; 41,432; 81,102; and 84,324 for fetuses at day (46-50), (51-55), (56-60), and (61-66) of gestation respectively. The present results are in agreement with those of Merlet Benichou *et al.*, (1981).

In agreement with the study of Spitzer and Brandis (1974) on the guinea pig and Horster and Valtin (1971) and Eisenbrandt and Plemister (1979) on the young dog, and contrary to the study of McCrory *et al.*, (1952), Fetterman *et al.*, (1965) and Elemann *et al.*, (1967) on human infants, the present study demonstrated a morphologic balance between glomerular and tubular growth.

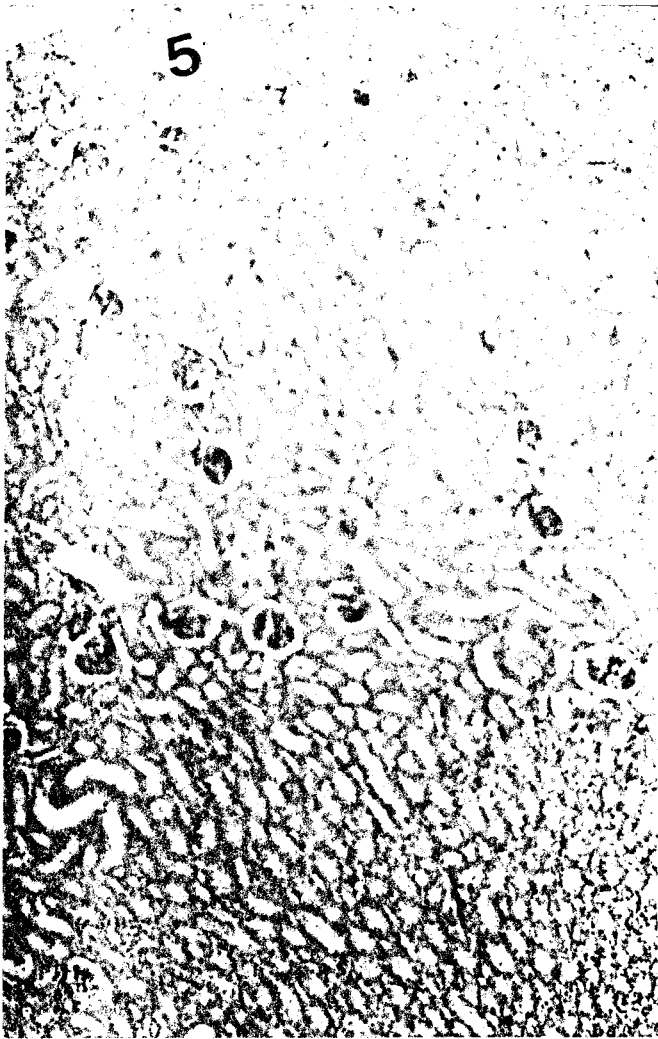


Fig. 10: Photomicrograph of a transverse section through the cortical region of the kidney of guinea pig embryo at day 66 of gestation showing subcapsular tubular zone which indicated tubular growth H & E

REFERENCES

- Bonvalet, I.P., M. Champion, F. Wanstock and G. Berjal, 1972. Compensatory renal hypertrophy in young rats: Increase in the number of nephrons. *Kidney Int.*, 1: 391-402.
- Cade-Treyer, D. and S. Tsuji, 1975. In vitro culture of the proximal tubule of the bovine nephron. *Cell Tissue Res.*, 163: 15-28.
- Chevalier, R.L. and R. A. Gomez, 1988. Response of the renin-angiotensin system to relief of neonatal ureteral obstruction. *Am. J. Physiol.*, 255: 1070-1077.
- Damadian, R.V., E. Shawayri and N. S. Bricker, 1965. On existence of non-urine forming nephrons in the diseased kidney of the dog. *J. Lab. Clin. Med.*, 65: 26-39.
- Eisenbrandt, D.L. and R. D. Phemister, 1979. Postnatal development of the canine kidney: Quantitative and Qualitative morphology. *Am. J. Anat.*, 154: 179-194.
- Edelmann, C.M., J. Rodriguez-Soriano, H. Boichis, A. B. Gruskin and M. I. Acosta, 1967. Renal bicarbonate reabsorption and hydrogen excretion in normal infants. *J. Clin. Invest.*, 46: 1309-1317.
- Feterman, G.H., N. A. Shuplock, F. L. Philipp and H. S. Gregg, 1965. The growth and maturation of human glomeruli and proximal convolutions from term to adulthood. *Pediatric*, 35: 601-619.
- Friis, C., 1980. Postnatal development of the pig kidney: Ultrastructure of the glomerulus and the proximal tubule. *J. Anat.*, 130: 513-526.
- Goncharevskaya, O.A. and H. Dlouha, 1975. The development of various generations of nephrons during postnatal ontogenesis in the rat. *Anat. Rec.*, 182: 367-376.
- Guttman, P.H. and H. I. Kohn, 1963. The mouse kidney after X-irradiation in early postnatal life. A study of immediate and delayed effects and their dependence on cellular differentiation and organ structure at the time of exposure. *Am. J. Pathol.*, 43: 809-824.
- Horster, M. and H. Valtin, 1971. Postnatal development of renal function: micropuncture and clearance studies in the dog. *J. Clin. Invest.*, 50: 779-795.
- Huber, G.C., 1905. On the development and shape of uriniferous tubules of certain of the higher mammals. *Am. J. Anat.*, 4: 1-98.
- Ishii, Y., 1970. An ultrastructural study of the intrauterine development of rabbit metanephric glomeruli. *Supporo Med. J.*, 37: 53-78.
- Jokelainen, P., 1963. An electron microscope study of the early development of the rat metanephric nephron. *Acta Anat.*, 52: 1-71.
- Larsson, L., 1975. The ultrastructure of the glomerular capillary wall during development of the rat renal glomerulus. *J. Ultrastruct. Res.*, 50: 374-375.
- Leeson, T.S., 1961. An electron microscope study of the postnatal development of the hamster kidney. *Lab. Invest.*, 10: 466-480.
- Loggie, I.M.H., L. I. Kleinman and E. F. Van Maanen, 1975. Renal function and diuretic therapy in infants and children. Part 1. *J. Pediat.*, 86: 485-496.
- McCrorry, W.W., C. Forman, H. Mcnamara and H. L. Barnett, 1952. Renal excretion of inorganic phosphate in newborn infants. *J. Clin. Invest.*, 31: 357-366.
- Merlet-Benichou, C., M. Pegorier, M. Muffat-Joly and C. Augeron, 1981. Functional and morphologic patterns of renal maturation in the developing guinea pig. *Am. J. Physiol.*, 241: 618-624.
- Nash, M.A. and C. M. Edelmann, 1973. The developing kidney. Immature function or inappropriate standard. *Nephron*, 11: 71-90.

Potter, E.L., 1972. Normal and abnormal development of the kidney. Chicago: Year Book Medical Publishers Incorporated, Chicago, p. 305.

Potter, E. L. and S. T. Theirstein, 1943. Glomerular development in the kidney as an index of fetal maturity. *J. Pediatr.*, 22: 695-706.

Solomon, S., 1974. Maximal gradients of Na and K across proximal tubules of kidneys of immature rats. *Biol Neonatic.*, 25: 327-339.

Spitzer, A. and S. Brandis, 1974. Functional and morphologic maturation of the superficial nephrons. Relationship to total kidney function. *J. Clin. Invest.*, 53: 279-287.