

Clinical Review

Extremity Ischemia After Jellyfish Envenomation: A Case Report and Systematic Review of the Literature

Saif Badran,^{*,†} Yazeed Eldos,^{‡,§} Robert J. Hoffman,^{‡,§} Sabeena Obaray,[‡] Bran Sivakumar,^{||} and Graeme E. Glass^{||,¶,♯}

^{*}Department of Plastic Surgery, Hamad General Hospital, Doha, Qatar, [†]Department of Population Medicine, College of Medicine, QU Health, Qatar University, Doha, Qatar, [‡]Department of Emergency Medicine, Sidra Medicine, Doha, Qatar, [§]Qatar Poison Center, Doha, Qatar, ^{||}Department of Surgery, Sidra Medicine, Doha, Qatar, [¶]Weill Cornell Medical College, New York, New York, and [♯]Weill Cornell Medicine-Qatar, Doha, Qatar

Reprint Address: Room C1-120, OPC, Sidra Medicine, Education City North Campus, Ar Rayyan, Doha, State of Qatar.

Abstract—Background: Extremity ischemia and necrosis after jellyfish envenomation can be mutilating and cause long-term functional deficits. The best way to manage these presentations is unknown. **Objective:** The aim of this review was to establish an evidence-based consensus for the management of extremity ischemia after jellyfish envenomation. **Methods:** A systematic review of cases of extremity ischemia and necrosis after envenomation by marine cnidarians was performed to clarify what is and what is not known about management and outcomes, to draw conclusions about how best to manage these rare presentations, and to establish an evidence-based algorithm. **Results:** The ischemic sequelae of envenomation typically evolves over a few days. Close medical supervision is necessary to react promptly to the evolving clinical scenario. In the literature, 15 different pharmacologic classes have been used to manage these presentations. Only IV infusions of prostaglandin derivatives and intra-arterial thrombolytics have been found to improve the clinical picture and avoid the need for surgical fasciotomy and debridement in some cases. Anticoagulants, antiplatelet agents, steroids, antibiotics, and nitrates, which are among the most commonly prescribed pharmacologic agents, have not been observed to alter the clinical picture. **Conclusions:** Surgery for compartment syndrome and necrosis are common sequelae of extremity envenomation by marine cnidarians. Only prompt use of IV prostaglandins or intra-arterial thrombolytics can halt ischemic progression and avoid the need for surgery. An algorithm is proposed

to guide management of these rare and mutilative presentations. © 2022 The Author(s). Published by Elsevier Inc. This is an open access article under the CC BY license (<http://creativecommons.org/licenses/by/4.0/>)

Keywords—Ischemia; Envenomation; Prostaglandin; Thrombolytic

Introduction

Jellyfish is a colloquialism for more than 4000 species of carnivorous invertebrates. Taxonomically, they represent the medusae (mature) life-cycle stage of the scyphozoan, cubozoan, and hydrozoan members of the subphylum Medusozoa of the phylum Cnidaria (1). The tentacles contain stinging cells called cnidocytes in which nematocysts develop—subcellular secretory organelles that are able to discharge venom on contact through a barbed, thread-like tube. The signs and symptoms of envenomation vary greatly and depend on the species, dose of venom, first aid given (with support for the use of hot as opposed to cold fresh water as a means of denaturing the toxins) and premonitory status of the afflicted patient (2). Localized symptoms of envenomation include pain (burning or stinging), erythema, urticaria, and vesicular or bullous eruptions. Systemic manifestations include nausea and

vomiting, headache, muscle cramps, cardiac dysrhythmia, hypersensitivity, anaphylaxis, and renal failure (3). Transient or prolonged neurologic manifestations are rare features of envenomation by some species (4). Although fatal envenomations are typically attributed to the most toxic species (typically the cubozoan group), the pathophysiological response to envenomation also depends on premorbid status, venom dose, and the consequent systemic immune response (5,6).

Envenomation syndromes manifest as delayed, persistent, or systemic symptom expression after previous envenomation (7). These manifestations typically exhibit delayed onset and follow resolution of the acute pain, erythema, and urticarial wheals that are indicative of acute envenomation (7). Extremity features include purpuric, necrotizing, or ulcerative lesions; fat atrophy; nerve paresis; ischemic necrosis; gangrene; and even compartment syndrome (6–10). Proposed pathophysiologic mechanisms include vasospasm, platelet aggregation, vasculitis, free-radical damage, and activation of the complement cascade and microthromboembolic insults (5). Satisfactory outcomes in these rare and potentially debilitating presentations require an evidence-based, algorithmic approach with input from emergency physicians, medical toxicologists, and hand surgeons. However, it is clear from the literature that absolutely no consensus exists on how best to manage these presentations, and an algorithmic approach has yet to be proposed.

We discovered this after an encounter with a 6-year-old boy who presented to our emergency department with a 48-h history of “stinging” pain in his left hand after brushing against an unidentified species of cnidarian while swimming in the Arabian Gulf. Examination by the emergency physician revealed erythema and an urticarial rash over the dorsal aspect of the left middle, ring, and little fingers (Figure 1A). The affected digits were noted to be swollen, cold, and tender to touch. There was no motor or sensory deficit. He was treated with a single dose of IV steroid and oral antihistamines, antibiotics, and analgesia. He was discharged with a short course of antibiotic and analgesia.

He returned 72 h later with increasing pain, exacerbated by flexion and extension of the ring and little fingers. Examination on this occasion revealed a well-demarcated purpuric rash over the dorsal aspect of the left ring and little fingers and along the ulnar border of the middle finger. In addition, the ring and little fingers were cold and cyanotic from the proximal interphalangeal joints (Figure 1B, C). A plastic surgery consult was sought.

After specialty evaluation, the patient was admitted for pain control, hand elevation, and warming, glyceryl trinitrate (GTN) patches, and subcutaneous injections of low-molecular-weight heparin. Twelve hours after admission, and due to the lack of improvement, a prostaglandin

E1 (alprostadil) infusion was initiated. The following morning, improvements in extremity temperature, color, swelling, and pain were noted. The infusion was continued for 5 days. At day 6, the patient was discharged with a 2-week course of analgesia and GTN patches. Examination 10 days later revealed patchy desquamation with underlying re-epithelialization, normal capillary refill, and good range of motion (Figure 1D, E). After another month, additional improvements were noted (Figure 1F–L). Ultimately, all digits survived and the hand is functionally normal at 18 months.

Prompted by this experience and our unease at the lack of direction afforded by the clinical literature, we conducted a systematic review with the aim of proposing an evidence-based algorithm for managing these mutilative and potentially limb-threatening presentations.

Materials and Methods

Study Design

A systematic review of the evidence for the management of extremity ischemia after envenomation by “jellyfish” (hereafter taxonomically referred to as cnidarians) was performed. PubMed (no date limit), Google Scholar (no date limit), OVID Medline (1946 to July 2021), the Cochrane Database of Systematic Reviews, and the Cochrane Central Register of Controlled Trials (searched July 3, 2021) were searched using medical subject heading terms and free text terms. The search strategy is summarized in Supplementary Table 1. Articles were cross-referenced to identify others of potential interest. The search strategy was conducted in accordance with the Cochrane highly sensitive search strategy in the *Cochrane Handbook for Systematic Reviews of Interventions* (11). The review was reported in line with the Preferred Reporting Items for Systematic Reviews and Meta-Analyses (Supplementary Table 2) (12). The study was registered prospectively on the PROSPERO database (registration number: CRD42021276245). Institutional Review Board approval for retrospective analyses of clinical data was not required by our institution. Consent was obtained from the patient’s parents for the publication of clinical images.

Inclusion Criteria

Case reports, case series, or clinical studies of extremity ischemia after envenomation by cnidarians in any language were included if both the clinical management was documented and the outcome described. In addition, the single case from our own experience was included.

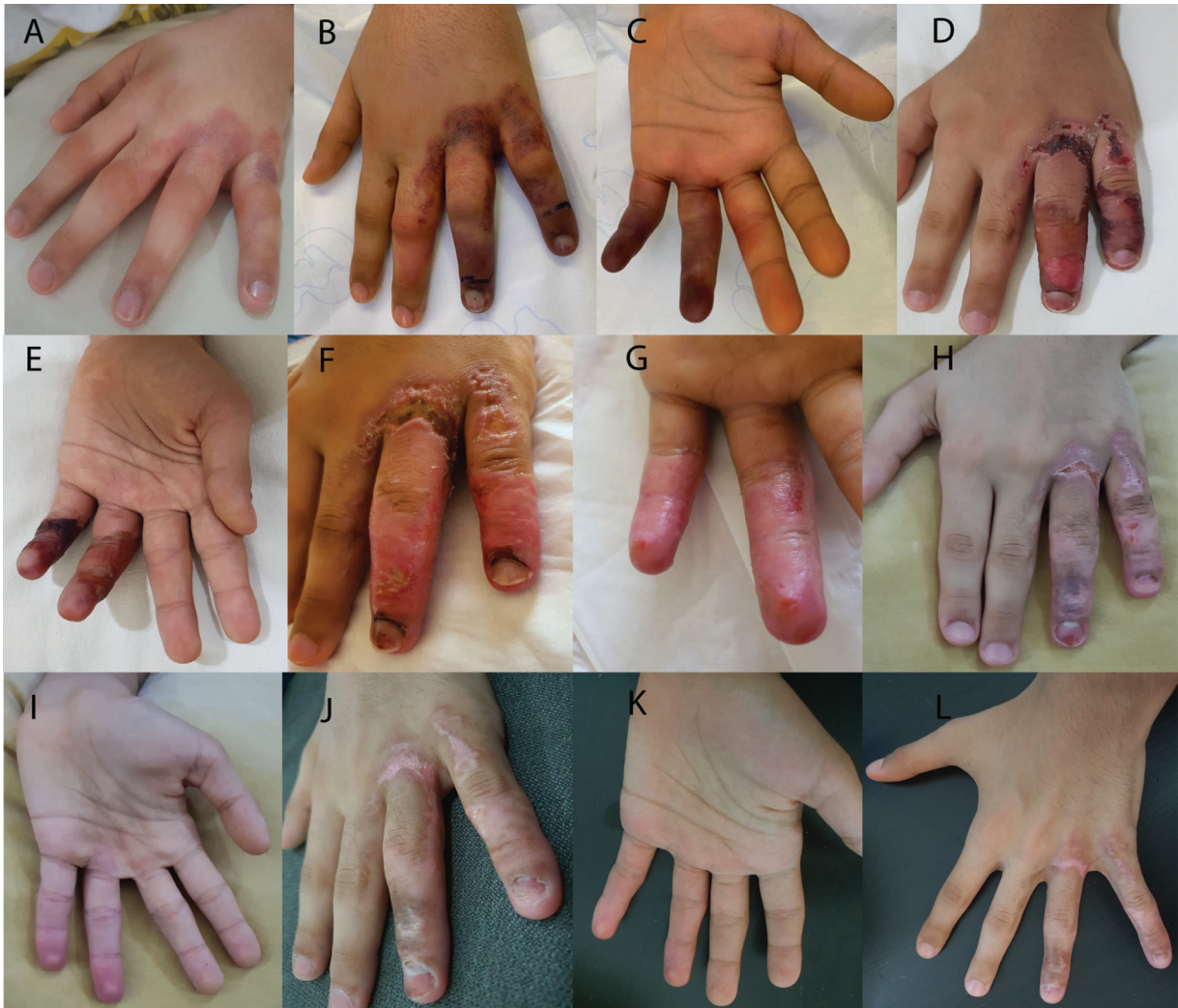

Figure 1. Digital ischemic changes over time following envenomation by an unidentified species of marine cnidarian. (A) Day 1. (B, C) Day 5. (D, E) Day 15. (F, G) Day 18. (H, I) Day 28. (J) Day 37. (K, L) Day 49.

Exclusion Criteria

Nonischemic local and systemic manifestations after envenomation by cnidarians (including anaphylaxis, cardiac dysrhythmias, and seizures) were not considered here. Ischemic events after envenomation by non-cnidarians (e.g., reptiles and insects) were similarly excluded. Extremity ischemia for which envenomation was not implicated (e.g., thromboembolic events, trauma, and iatrogenic causes) were also excluded from consideration.

Outcome Measures

The primary outcome measure sought was extremity survival. Secondary outcome measures included the residual functional potential of the affected extremity. All outcomes were considered in the context of the presenting

features and the medical and surgical management undertaken.

Study Selection

All data were retrieved from full-text articles accepted for analysis by 2 researchers (S.B., Y.E.). When necessary, a consensus was sought with the senior author (G.G.).

Data Extraction

For each individual case, the data collected included the year published; duration from envenomation to presentation; first aid given (if any); sequence and nature of emergency, medical, and surgical intervention; salvage status of the affected extremity; and, when available, any functional measures.

Data Analysis

All articles accepted for inclusion were either case reports or case series and there were sufficient variations in the emergency, medical, and surgical management that it was not possible to compile a quantitative synthesis of the data. As all source studies were case reports or case series, the quality of the source data was subject to standardized evaluation using the Joanna Briggs Institute's (JBI) critical appraisal checklist for case reports (13). The management algorithm was compiled as a summary of the qualitative synthesis of the evidence, taking into account the accepted principles of emergency care, including the acknowledgment of the possible need for resuscitation in some cases. As the principles of first aid after jellyfish envenomation continue to be debated and, as this debate falls outside the scope of this article, the algorithm has not made any specific recommendations in this regard. The case presentation was compiled by the physicians directly involved in the care of the illustrative case.

Results

We screened 545 records, and 59 full texts were assessed for eligibility. A total of 12 studies involving 15 patients were included for qualitative synthesis (5,6,8–10,14–20). Inclusive of our experience, a total of 16 cases were analyzed. The literature search and study selection is summarized in Figure 2. The case data are summarized in Table 1. Evaluation using the JBI's critical appraisal checklist for case reports was performed (Supplementary Table 3) (13).

All 16 cases occurred in the northern hemisphere, between 5° North (Penang, Malaysia, in the Malacca Strait of the Andaman Sea) and 40° North (Canakkale, Turkey, in the Dardanelles Strait of the Aegean Sea). Five cases occurred in the Arabian (Persian) Gulf, four in the Andaman Sea, four in the Indian Ocean, and one each in the Gulf of Thailand, Caribbean Sea, and Aegean Sea. Although the cnidarian responsible was observed and described in several cases, in only two cases was the species identified with a reasonable degree of certainty. In one case, the species was a *Physalia physalis*, or "Portuguese man o' war" and the other was a *Chironex fleckeri*, or "box jellyfish." Nine cases of envenomation involved the upper extremity, two cases involved the lower extremity, and both the upper and lower extremities were involved in the remaining five cases.

In almost all cases, the initial symptoms included a sudden, intense pain that was sometimes described as "burning" or "stinging." Erythema, an urticarial rash or inflammatory wheals, and, less commonly, a "vesicular"

eruption, pruritus, or paraesthesia were also described. In most cases some form of first aid, including the use of cold or hot water, topical ointments, oral analgesia, or antihistamines were described.

In each case, the initial presentation evolved to include edema, cyanosis, ischemia, and, in some cases, frank necrosis within a period of between 1 day and 4 weeks (but almost always within 10 days) after envenomation. Importantly, in all cases, cyanosis, ischemia, and necrosis, when observed, involved the fingers or toes of the envenomed extremity, even when the acute site of injury was above the elbow or knee. Data obtained from angiograms, when performed, revealed compromised blood flow distal to the envenomation site.

In nine cases, localized sensory impairment (paraesthesia) was described in tandem with the evolution of cyanosis and ischemia. In two cases, a severe and progressive motor paresis was described, in addition to sensory impairment. Systemic signs were rarer and included fever, hyperhidrosis, myalgia, dyspnea, hypertension, shock, and tonic-clonic seizures.

After presentation with cyanosis, ischemia, or necrosis, a total of 15 different classes of pharmacologic agents were prescribed, excluding analgesia. The most commonly prescribed therapy was corticosteroids, which were given in 11 cases, followed by anticoagulants (including low-molecular-weight and unfractionated heparin) in 8 cases. Antibiotics were prescribed in seven cases. Antihistamines and infusions of prostaglandin derivatives were given in five cases. Antiplatelet agents, nitrates, and intra-arterial thrombolytics were given in four cases. Xanthine derivatives (pentoxifylline) were given in three cases. Calcium channel blockers were given in two cases. The remaining four classes of pharmacologic agents were given in single cases. In addition, hyperbaric oxygen therapy was trialed in one case.

Nine of the 16 cases required surgical intervention by way of fasciotomies with or without debridement of necrotic tissue for failure of medical therapy. The prostaglandins iloprost (a synthetic analogue of prostacyclin) or alprostadil (prostaglandin E2) were prescribed in three cases. In all three cases, clinical improvement was noted after the commencement of the infusion and all 3 cases avoided surgery. In 2 additional cases, the thrombolytic urokinase was given intra-arterially and, again, improvement was observed after administration and surgery was avoided. In the two most severe clinical presentations (cases 10 and 15, Table 1) both prostaglandin and urokinase infusions were given, but surgery was required in both cases. This does not tell the full story, however. Both cases involved all four limbs and the combination of prostaglandin (E1) and urokinase was a qualified success, with rapid improvement in lower limb ischemia in both cases. The upper limbs, however,

Table 1. Summary of Reported Cases of Jellyfish Envenomation-Induced Extremity Ischemia.

Case	First Author	Location	Extremity	Initial Symptoms	Presentation (Delay)	Management		Outcome
						Medical	Surgical	
1	Present study	Arabian gulf	L hand/forearm	Pain/erythema and burning sensation in hand/forearm	Severe pain and cyanosis in ring and little fingers (day 5)	IV steroids, oral antihistamines, antibiotics, analgesia then LMWH, topical GTN, calcium channel blockers, and IV prostaglandin (alprostadi)	Not performed	Superficial skin necrosis with re-epithelialization and full hand function
2	Desax-Willer, 2018 (9)	Gulf of Thailand	R and L thighs and legs	Intense pain, erythematous wheals	Intense itching, fever, tachycardia, superficial dry gangrene (day 9)	Oral prednisone, silver sulfadiazine, and antibiotics (topical and systemic)	Debridement and VAC	Healed with split-thickness skin grafts
3	Mundkur, 2018 (14)	Arabian Sea (Indian Ocean)	R and L hands and legs	Erythema, rash	Cyanosis of the middle, ring, and little fingers of the R hand (day 1) hypertension (day 4) tonic-clonic seizure (day 5)	LMWH, IV steroids, and antiplatelet medications anticonvulsants	Not performed	Permanent skin discoloration R foot drop Long-term anticonvulsants
4	Lo, 2016 (5)	Malacca Strait, Andaman Sea	R arm/forearm	Burning pain, erythema, paraesthesia in R middle, ring, and little fingers	Pallor, coldness, paresthesia R middle, ring, and little finger (day 1) Cyanotic (day 3)	PO steroids Then aspirin, LMWH, and topical GTN patch Then IV prostaglandin (iloprost) for 7 days	Not performed	Perfusion improved after iloprost infusion Pulse was restored after 3 days

(continued on next page)

Table 1. (continued)

Case	First Author	Location	Extremity	Initial Symptoms	Presentation (Delay)	Management		Outcome
						Medical	Surgical	
5	Choong, 2015 (6)	Malacca Strait, Andaman Sea	R fore-arm/hand	Burning pain, urticarial rash, vesicles Sweating, tachycardia, muscle aches	Cyanosis and paraesthesia of the fingers of R hand Necrotic patches over R forearm	IM antihistamine and PO antibiotics LMWH	Fasciotomies	Permanent skin discoloration
6	Lam, 2014 (15)	Andaman Sea	R arm/thigh	Intense burning pain	Edema, cyanosis, paresthesia R hand (day 4)	Steroids, LMWH	Fasciotomies for compartment syndrome followed by repeated debridement	Delayed fingertip amputations and regional flap cover to dorsum of hand
7	Binnet-oglu, 2013 (16)	Aegean Sea	Both hands	Rash, fever	Severe pain and cyanosis in the fingers (day 10)	LMWH, aspirin, nifedipine, and sildenafil Then IV prostaglandin (iloprost), steroids and hyperbaric oxygen	Not performed	Middle fingertip necrosis treated conservatively
8	Giordano, 2005 (19)	Caribbean Sea	R foot	Intense burning pain	Edema, cyanosis, and paraesthesia (4 wk)	PO antibiotics, Then IV antibiotics	Debridement of necrotic tissue, skin graft	Healed uneventfully

(continued on next page)

Table 1. (continued)

Case	First Author	Location	Extremity	Initial Symptoms	Presentation (Delay)	Management		Outcome
						Medical	Surgical	
9	El Khatib, 2000 (8)	Arabian Gulf	L hand	Pain, erythema, pruritus, paraesthesia	Hand swelling, cyanosis of index and middle fingers (same day)	IV antibiotics, anticoagulants, steroids, analgesia	Hand fasciotomies	Healed uneventfully without tip necrosis
10	Williamson, 1988 (20)	Indian Ocean	R and L arms and legs	Severe burning pain, erythema, urticarial rash Shock	Severe edema, fingertip necrosis Paresthesia (day 4) Motor paresis, reduced peripheral pulses, more extensive ischemia (day 10)	Heparin, nitroglycerine, and systemic steroids IV prostaglandin (alprostadil) and urokinase	Upper limb fasciotomies and debridement (day 18)	Extensive upper limb skin and muscle necrosis eventually covered with skin grafts Poor long-term recovery of upper limbs—motor and sensory impairment Good recovery of lower limbs
11	—	Malacca Strait, Andaman Sea	L hand, R thigh, leg, foot	Severe pain, erythema, urticarial lesions	Worsening pain, thumb/index tip cyanosis (day 1) Edema, loss of radial pulse (day 2) Worsening ischemia of thumb, index, middle fingers (day 3–4)	PO antihistamines, analgesia; IM steroid, pentoxifylline, antibiotics PO dipyridamole	L hand fasciotomies (day 4)	long-term paresthesia of the thumb, index, middle and ring fingers of L hand

(continued on next page)

Table 1. (continued)

Case	First Author	Location	Extremity	Initial Symptoms	Presentation (Delay)	Management		Outcome
						Medical	Surgical	
12	—	Indian Ocean	L arm	Not recorded	Impalpable radial, ulnar, and brachial artery pulses (within 3 h) Angiogram–brachial artery spasm	Not recorded	Not performed	Healed uneventfully
13	Abu-Nema, 1988 (10)	Arabian Gulf	L arm/forearm	Severe pain/wheals in arm and forearm	Cyanosis and paresthesia in middle, ring, and little fingers (day 3)	antihistamine, antibiotics, heparin, and dextran IV pentoxifylline and IA reserpine IA urokinase	cervicodorsal sympathectomy	Patient improved after IA urokinase only Long-term minor paresthesia in the affected digits reported
14	—	Arabian Gulf	R forearm	Burning pain and erythema	Cyanosis and paresthesia in R hand (day 3)	IA tolazoline IA pentoxifylline IA urokinase	Not performed	Long-term paresthesia in the affected digits reported
15	Hach-Wunderle, 1987 (18)	Indian Ocean	R and L arms and legs; trunk	Pain, erythema, edema	Cyanosis hands and feet (day 4)	IV prostaglandin (alprostadi), steroids, nitroglycerin IA urokinase	Fasciotomies for compartment syndrome hands and forearms (day 13)	Complete resolution of lower limb ischemia Long-term sensory and motor impairment upper limbs
16	Drury, 1980 (17)	Arabian Gulf	R hand/forearm	—	Severe pain, edema, dyspnea	Antihistamines, analgesia IA 5HT2 receptor antagonists (naftidrofuryl oxalate)	Fasciotomies for compartment syndrome Thoracic sympathectomy	Fingertip amputations, split-thickness skin grafts to forearm

GTN = glyceryl trinitrate; IA = intra-arterial; L = left; LMWH = low-molecular-weight heparin; PO = per oral; R = right; VAC = vacuum-assisted closure.

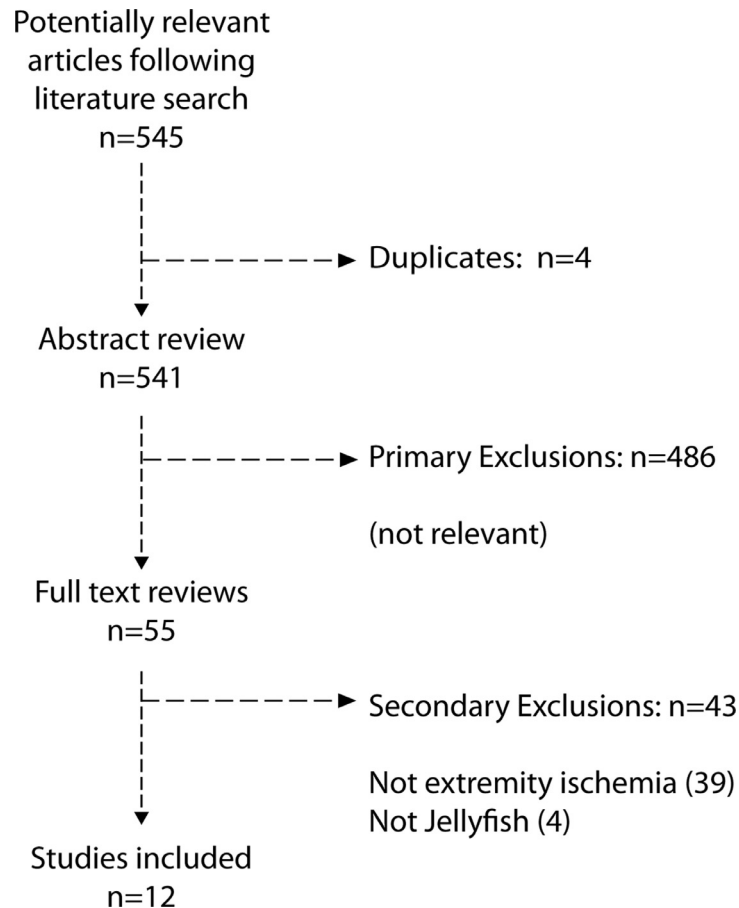


Figure 2. Literature search and study selection.

fares less well and both patients underwent upper limb fasciotomies (18).

In two cases, sympathectomies were performed as an adjunct to medical therapy, but in neither case was this intervention noted to have helped. One case was managed supportively. In this case an angiogram revealed a spasm of the brachial artery after envenomation of the arm. No further intervention was described. We may infer that the spasm resolved spontaneously, as healing was uneventful thereafter.

Discussion

We collated the collective experience of 16 cases of extremity ischemia after envenomation by marine cnidarians over 40 years in order to draw conclusions about how best to manage these rare but potentially mutilative presentations. All evidence has come by way of case reports and case series and all but one case involved envenomation by contact in the tropical northern hemisphere. Surgical decompression of the extremity compartments with or without debridement of skin, fat, or muscle (the con-

sequence of failed medical management) were thought necessary in more than one-half of the presentations reported. Importantly, the study confirmed the large number of pharmacologic agents used to treat these presentations. The four most common classes were anticoagulants, antiplatelet agents, steroids, and antibiotics, yet the use of these medications did not change the natural progression of the ischemic event and in all but one case, patients managed in this way eventually underwent surgery. By contrast, IV infusions of prostaglandin analogues (iloprost, alprostadil) or intra-arterial infusions of thrombolytics (urokinase) averted the need for surgery altogether in five of seven cases and were implicated in the avoidance of surgery in at least one involved extremity in the remaining two cases. These cases were particularly severe and extensive envenomations involving all four limbs. In both cases, lower limb fasciotomies were averted.

The extremity ischemia described in relation to envenomation was insidious and progressive in nature. Invariably, the hands and feet were the focus of the ischemic concern even when the envenomation site was more proximal. In one report, a computed tomography angiogram confirmed the presence of arterial narrowing and poor

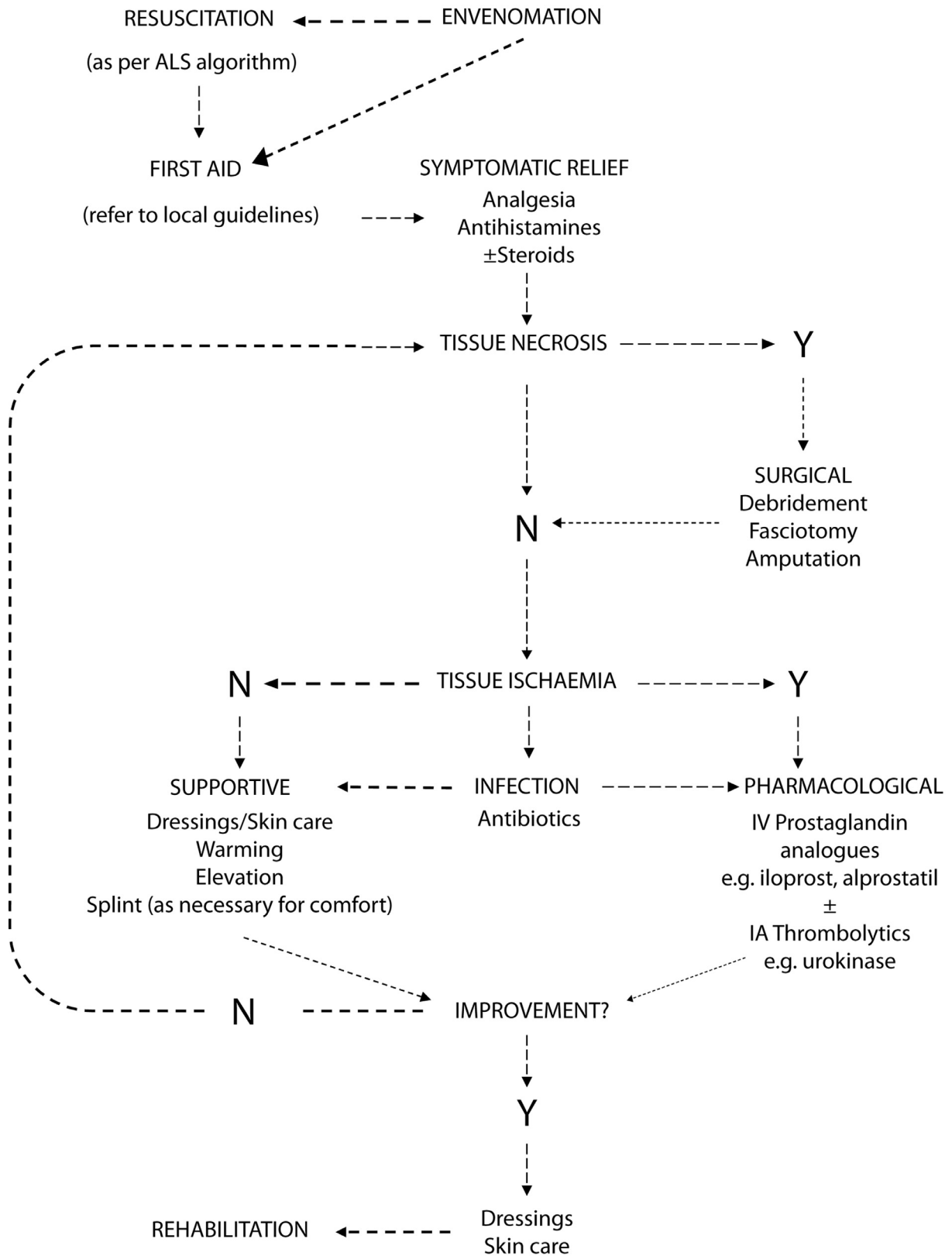


Figure 3. Algorithmic approach for the treatment of venom-induced extremity ischemia. ALS = Advanced Life Support; IA = intra-arterial.

distal flow in the absence of pre-existing atherosclerotic disease (6). This suggests vasospasm, supporting the view that vasodilators have an important role to play here. However, it does not rule out thromboembolism as either cause or consequence and does not disavow the use of intra-arterial thrombolytics in the event of vasodilators failing to restore distal circulation. In addition, long-term paraesthesia was reported in a number of these cases (20).

These observations reveal much about the pathophysiology of envenomation by marine cnidarians. A convincing case can be made to support the view that vasospasm, thromboemboli, and peripheral neuropathy are the three key features. Supportive circumstantial evidence includes the report of a case of acute myocardial infarction in an otherwise healthy individual after envenomation (21). If we are to accept this proposition, it is understandable why anticoagulants and medications that prevent platelet degranulation and aggregation are not effective in established extremity ischemia. By contrast, the fact that the only medications that were shown to be effective reversed vasospasm and microembolic blockage supports the conclusion of Burnett, which was based on the inferences he drew from a case report of foot ischemia after envenomation (22). This hypothesis also postulates why long-term sensory and motor neuropathies are described, even in cases when ischemia was promptly and comprehensively reversed.

Both iloprost and alprostadil are well-established drugs used in the treatment of Raynaud's phenomenon and systemic sclerosis. Roughly equivalent in terms of efficacy, the recommended dose of iloprost is titrated from 0.5 ng/kg/min up to a maximum of 2 ng/kg/min, subject to tolerance of the adverse effect profile, including hypotension and dizziness (23). By contrast, the recommended dose of alprostadil is 60 μ g/d. In the current series, this was equivalent to 4–7.5 ng/kg/min. The dose of urokinase depended on the method of administration. When given intra-arterially, 50,000 units were used. When given intravenously, between 2.5 and 6 million units were used. These dosing regimens were, in all cases, those advised for use in Raynaud's phenomenon.

Epinephrine is crucial for the management of associated anaphylaxis (24). Analgesia and antihistamines are used for symptom control. The rationale for the use of steroids is less clear cut and depends on the clinical manifestations of the case in question. Although steroids may be helpful in managing symptomatic edema and urticaria in the acute phase of envenomation, it remains unclear whether or not the use of steroids hinders the adaptive immune response to the venom. Hyperbaric oxygen may be useful for managing the spread of necrosis, but as it does not address the underlying problem, this option will continue to be of peripheral interest. Quite clearly, there is no justification for the routine use of antibiotics here. The

centrality of antibiotics in the acute management of these presentations reflects diagnostic error, whereby tissue erythema, edema, and burning pain are erroneously attributed to bacterial cellulitis. Other medications, including calcium channel blockers and phosphodiesterase inhibitors, were used insufficiently, often to draw conclusions about whether they are useful adjunctive measures.

The null hypothesis argues that outcome is only influenced by the dose and nature of, and immune response to, the toxin. If we were to accept this view, then the observations of improvement after the use of prostaglandins and urokinase simply reflect the natural clinical course of these individual envenomation incidents. Furthermore, it may be argued that, as we are dealing with different species of marine cnidarians, we are dealing with different venoms. If envenomation is pathophysiologically heterogeneous, this undermines our attempt to draw generalizable conclusions. The counter argument is that this study has observed trends that transcend patient demographics and geographic location.

Limitations

The limitations of this study are centered on the lack of authoritative data on which to draw conclusions. Although this is so, this remains, to our knowledge, the only study conducted that sought to comprehensively address the existing literature on the subject. In doing so, we must accept that the existing literature is sparse but this does not negate the findings so much as suggest a note of caution when interpreting the results. Moreover, the lack of studies from the Southern Hemisphere suggests an element of publication bias and it would have been desirable to have included the Southern Hemisphere experience were we to have found any relevant publications. In addition, it was not the purpose of this study to evaluate first-aid management after acute envenomation, as this has been evaluated extensively elsewhere.

Based on the analyses presented here, an algorithmic approach is proposed as shown in [Figure 3](#). Further research will center on establishing the validity of this algorithm and adjusting, as necessary, until such a time as the management of these rare cases is optimized.

Conclusions

Surgery for tissue necrosis and compartment syndrome are common sequelae of extremity envenomation by marine cnidarians, which can be both mutilative and functionally debilitating. Long-term sensory disturbance is common. Prompt use of IV prostaglandins or intra-arterial thrombolytics has been shown to reverse ischemic progression in some case reports and should be considered

as possible first-line therapeutic options. The most commonly prescribed medications, including anticoagulants, antiplatelet agents, steroids, antibiotics, calcium channel blockers, and topical nitrates, have not been observed to alter the clinical picture, and other options, including phosphodiesterase inhibitors and hyperbaric oxygen, were not used often enough to draw conclusions. The proposed algorithmic approach may serve to reduce uncertainty, avoid wasting crucial time, and salvage valuable tissue.

Supplementary materials

Supplementary material associated with this article can be found, in the online version, at doi:[10.1016/j.jemermed.2022.06.014](https://doi.org/10.1016/j.jemermed.2022.06.014).

References

- Cegolon L, Heymann WC, Lange JH, Mastrangelo G. Jellyfish stings and their management: a review. *Marine Drugs* 2013;11:523–50.
- Atkinson PRT, Boyle A, Hartin D, McAuley D. Is hot water immersion an effective treatment for marine envenomation? *Emerg Med J* 2006;23:503.
- Burnett JW. Clinical manifestations of jellyfish envenomation. *Hydrobiologia* 1991;216:629–35.
- Peel N, Kandler R. Localized neuropathy following jellyfish sting. *Postgrad Med J* 1990;66:953–4.
- Lo AH, Chan YC, Law Y, Cheng SW. Successful treatment of jellyfish sting-induced severe digital ischemia with intravenous iloprost infusion. *J Vasc Surg Cases* 2016;2:31–3.
- Choong C, Chan HZ, Faruk NA, Bea KC, Zulkiflee O. Jellyfish envenomation resulting in vascular insufficiency and neurogenic injury of upper limb. *Malays Orthop J* 2015;9:49–51.
- Burnett JW, Calton CJ. Jellyfish envenomation syndromes updated. *Ann Emerg Med* 1987;16:1000–5.
- El Khatib HA, al Basti HB. Finger ischemia following a jelly fish sting: a surgical approach. *Qatar Med J* 2000;9:64–5.
- Desax-Willer D, Krebs T, Christen S. Delayed deep dermal necrosis after jellyfish sting in a 4-year-old female infant. *Case Rep Plast Surg Hand Surg* 2018;5:75–9.
- Abu-Nema T, Ayyash K, Wafaii IK, Al-Hassan J, Thulesius O. Jellyfish sting resulting in severe hand ischemia successfully treated with intra-arterial urokinase. *Injury* 1988;19:294–6.
- Cumpston M, Li T, Page MJ, Chandler J, et al. Updated guidance for trusted systematic reviews: a new edition of the Cochrane Handbook for Systematic Reviews of Interventions. *Cochrane Database Syst Rev* 2019;10.
- Moher D, Liberati A, Tetzlaff J, Altman DG. Preferred Reporting Items for Systematic Reviews and Meta-Analyses: the PRISMA statement. *BMJ* 2009;339:332–6.
- Munn Z, Barker TH, Moola S, et al. Methodological quality of case series studies: an introduction to the JBI critical appraisal tool. *JBI Evid Synth* 2020;18:2127–33.
- Mundkur S, Shashidhara S, Hebbar S, Kumar A, Kanaparthi S. Jellyfish envenomation: a chilling toxidrome of seizures and cyanosis – a case report. *South Afr J Child Health* 2018;12:73–5.
- Lam SC, Hung YW, Chow ECS, Wong CQY, Tse WL, Ho PC. Digital ischemia: a rare but severe complication of jellyfish sting. *Hong Kong Med J* 2014;20:460–3.
- Binnetoglu FK, Kizildag B, Topaloglu N, Kasapcopur O. Severe digital necrosis in a 4-year-old boy: primary Raynaud's or jellyfish sting. *BMJ Case Rep* 2013.
- Drury JK, Noonan JD, Pollock JG, Reid WH. Jelly fish sting with serious hand complications. *Injury* 1980;12:66–8.
- Hach-Wunderle V, Mebs D, Frederking K, Breddin HK. [Jellyfish poisoning]. *Dtsch Med Wochenschr* 1987;112:1865–8.
- Giordano AR, Vito L, Sardella PJ. Complication of a Portuguese man-of-war envenomation to the foot: a case report. *J Foot Ankle Surg* 2005;44:297–300.
- Williamson JA, Burnett JW, Fenner PJ, Hach-Wunderle V, Hoe LY, Adiga KM. Acute regional vascular insufficiency after jellyfish envenomation. *Med J Aust* 1988;149:698–701.
- Salam AM, Albinali HA, Gehani AA, Suwaidi J. Acute myocardial infarction in a professional diver after jellyfish sting. *Mayo Clin Proc* 2003;78:1557–60.
- Burnett JW. Jellyfish foot injury-vasospasm. *J Foot Ankle Surg* 2006;45:58.
- Marassini B, Massarotti M, Bottasso B, et al. Comparison between iloprost and alprostadil in the treatment of Raynaud's phenomenon. *Scand. J Rheum* 2004;33:253–7.
- Campos-Pereira JC, Szpilman D, Haddad Jr V. Anaphylactic reaction/angioedema associated with jellyfish sting. *Rev Soc Bras Med Trop* 2018;51:115–17.

ARTICLE SUMMARY

1. Why is this topic important?

Extremity ischemia after jellyfish envenomation can lead to mutilative surgery and long-term functional impairment. The existing literature does not tell us how best to manage these presentations.

2. What does this study attempt to show?

This review aims to guide management of these rare presentations, thereby minimizing the need for surgery and complications associated with ineffective pharmacologic therapies.

3. What are the key findings?

Only IV prostaglandin infusions and intra-arterial thrombolytics have been shown to reverse ischemic changes.

4. How is patient care impacted?

The existing evidence seems not to support the use of antiplatelet agents, anticoagulants, steroids, or antibiotics. The proposed algorithm may preserve extremity form and function.