



# A loss-of-function *NCSTN* mutation associated with familial Dowling Degos disease and hidradenitis suppurativa

Ana Sofia Lima Esteveao de Oliveira<sup>1</sup>  | Roberta Cardoso de Siqueira<sup>2</sup> |  
 Cécile Nait-Meddour<sup>3</sup> | Paola Maura Tricarico<sup>4</sup> | Ronald Moura<sup>4</sup> |  
 Almerinda Agrelli<sup>5</sup> | Adamo Pio d'Adamo<sup>4,6</sup> | Stéphane Jamain<sup>3</sup> |  
 Sergio Crovella<sup>7</sup> | Maria de Fátima Medeiros Brito<sup>2</sup> | Michele Boniotto<sup>3</sup>  |  
 Lucas André Cavalcanti Brandão<sup>1,8</sup>

<sup>1</sup>Keizo Asami Institute-iLIKA, Federal University of Pernambuco, Recife, Brazil

<sup>2</sup>Hospital das Clínicas, Federal University of Pernambuco, Recife, Brazil

<sup>3</sup>Univ Paris Est Créteil, INSERM, IMRB, Translational Neuropsychiatry, Créteil, France

<sup>4</sup>Institute for Maternal and Child Health-IRCCS "Burlo Garofolo", Department of Advanced Diagnostics, Trieste, Italy

<sup>5</sup>Laboratory of Nanostructured Materials (LMNANO), Center for Strategic Technologies Northeastern (CETENE), Recife, Brazil

<sup>6</sup>University of Trieste, Department of Medical Surgical and Health Sciences, Trieste, Italy

<sup>7</sup>LARC Laboratory Animal Research Center, University of Qatar, Doha, Qatar

<sup>8</sup>Department of Pathology, Federal University of Pernambuco, Recife, Brazil

## Correspondence

Michele Boniotto, Translational Neuropsychiatry, Univ Paris Est Créteil, INSERM, IMRB, 61 Av. du Général de Gaulle, 94010 Créteil, France.  
 Email: [michele.boniotto@inserm.fr](mailto:michele.boniotto@inserm.fr)

## Funding information

Conselho Nacional de Desenvolvimento Científico e Tecnológico (CNPq); Coordenação de Aperfeiçoamento de Pessoal de Nível Superior - Brasil (CAPES); EraPerMed 2018-17 European Community funds (JTC\_2018); Fondation René Touraine; Italian Ministry of Health

## Abstract

Dowling Degos disease (DDD) is a rare autosomal dominant genodermatosis characterized by acquired, slowly progressive reticulated pigmented lesions primarily involving flexural skin areas. Mutations in *KRT5*, *POGLUT-1* and *POFUT-1* genes have been associated with DDD, and loss-of-function mutations in *PSENEN*, a subunit of the gamma-secretase complex, were found in patients presenting with DDD or DDD comorbid with hidradenitis suppurativa (HS). A nonsense mutation in *NCSTN*, another subunit of the gamma-secretase, was already described in a patient suffering from HS and DDD but whether *NCSTN* could be considered a novel gene for DDD is still debated. Here, we enrolled a four-generation family with HS and DDD. Through Whole Exome Sequencing (WES) we identified a novel nonsense mutation in the *NCSTN* gene in all the affected family members. To study the impact of this variant, we isolated outer root sheath cells from patients' hair follicles. We showed that this variant leads to a premature stop codon, activates a nonsense-mediated mRNA decay, and causes *NCSTN* haploinsufficiency in affected individuals. In fact, cells treated with gentamicin, a readthrough agent, had the *NCSTN* levels corrected. Moreover, we observed that this haploinsufficiency also affects other subunits of the gamma-secretase complex, possibly causing DDD. Our findings clearly support *NCSTN* as a novel DDD gene and suggest carefully investigating this co-occurrence in HS patients carrying a mutation in the *NCSTN* gene.

## KEYWORDS

Dowling Degos disease, genetic mutation, gentamicin, hidradenitis suppurativa, *NCSTN*

Ana Sofia Lima Esteveao de Oliveira and Roberta Cardoso de Siqueira should be considered joint first author' and Michele Boniotto and Lucas André Cavalcanti Brandão should be considered joint senior authors.

This is an open access article under the terms of the [Creative Commons Attribution-NonCommercial-NoDerivs](https://creativecommons.org/licenses/by-nc-nd/4.0/) License, which permits use and distribution in any medium, provided the original work is properly cited, the use is non-commercial and no modifications or adaptations are made.

© 2023 The Authors. *Experimental Dermatology* published by John Wiley & Sons Ltd.

## 1 | INTRODUCTION

Dowling-Degos disease (DDD) (ORPHA:79145) is a rare autosomal dominant genodermatosis characterized by slowly progressive reticulated pigmented lesions in flexural skin areas.<sup>1</sup> The first gene associated with DDD was *KRT5*.<sup>2</sup> Mutations in the head region of keratin 5 (*KRT5*) protein are found in ~1/3 of DDD patients, usually presenting an acantholytic variant named Galli-Galli Disease (GGD).<sup>3,4</sup> Loss-of-function (LOF) mutations in the genes encoding the protein O-fucosyltransferase 1 (*POFUT1*) and the protein O-glucosyltransferase 1 (*POGLUT1*) have been found in sporadic cases and families suffering from DDD.<sup>5,6</sup>

Hidradenitis suppurativa (HS), also known as Acne Inversa, is a chronic inflammatory skin disease clinically characterized by recurrent painful nodules and abscesses on body areas containing apocrine glands.<sup>7</sup> In severe HS phenotypes, recurrent nodular rupture leads to sinus tract formation, a hallmark that severely impacts patients' quality of life.<sup>8</sup> HS may appear in a sporadic, familial or syndromic form and is associated with a mutation in *NCSTN*, *PSEN-1* or *PSENEN* in 5% of patients.<sup>9</sup>

The first patient suffering from DDD and HS was described in 1990<sup>10</sup> and, ever since, several patients have been reported raising the hypothesis that this co-occurrence is due to a shared pathogenic mechanism rather than a simple coincidence. Interestingly, mutations in *PSENEN* were first associated with HS and only later found in patients suffering from DDD alone or DDD and HS,<sup>11-14</sup> thus confirming the pathogenic link between DDD and HS. Even if the molecular events leading to HS and DDD are not well elucidated, the common hypothesis is that a reduced NOTCH signalling in keratinocytes and melanocytes could be responsible for both diseases. In fact, most of the mutated proteins in HS or DDD are involved in NOTCH Receptors processing or maturation. Presenilin enhancer (*PEN-2* -encoded by *PSENEN*) together with nicastrin (*NCSTN*), presenilins 1 or 2 (*PSEN*) and anterior pharynx defective 1 A or B (*APH1*) compose the gamma-secretase complex,<sup>15</sup> a high molecular weight transmembrane enzyme complex that is involved in intramembrane cleavage of the NOTCH Receptors.<sup>16</sup> In addition, *POFUT1* and *POGLUT1* add O-fucose and O-glucose, respectively, to most of the EGF-like repeats of NOTCH Receptors.<sup>17</sup> Why mutations in certain genes are associated with HS and others with DDD is not known. In this respect, even if mutations in *NCSTN* have already been found in patients suffering from both HS and DDD, *NCSTN* remains not recognized as a gene for DDD.

In this paper, we report the genetic study of a four-generation family from Brazil where HS and DDD co-segregate as an autosomal dominant trait. Whole exome sequencing (WES) performed in two affected and one non-affected family member allowed the identification of a novel nonsense mutation in the *NCSTN* gene that was found in all affected individuals. Functional studies conducted on outer root sheath keratinocytes isolated from plucked hairs showed that the mutation caused haploinsufficiency of *NCSTN* triggered by nonsense-mediated decay (NMD) and also affected other subunits of the gamma-secretase complex. Interestingly, this haploinsufficiency could be corrected by gentamicin, a read-through stimulating antibiotic.

## 2 | MATERIALS AND METHODS

### 2.1 | Patients

In October of 2019, a Brazilian family was recruited in a multidisciplinary ambulatory of HS at Hospital das Clínicas-Federal University of Pernambuco, situated in Recife, Brazil. This study, managed in accordance with the Declaration of Helsinki standards, has been approved by the local and federal ethical committee (CAAE: 03096118.1.0000.5208/Approval number 3.588.204). To be included in the study, written consent from all the patients has been collected after a scrupulous explanation of the research's purpose.

HS clinical diagnosis was given by a dermatologist based on the European guidelines (S1) of Dessau.<sup>18</sup> DDD diagnosis was later confirmed in two patients through a 5 mm biopsy punch and histopathologic analysis stained with haematoxylin and eosin. Biopsies were only performed on patients that went through HS surgery. Although histopathologic analyses were not performed in the remaining patients, similar clinical DDD lesions were observed.

### 2.2 | Whole exome sequencing analysis

Subsequent to diagnosis, patients' blood samples were collected for DNA isolation. DNA was isolated from peripheral venous blood using the Wizard® Genomic DNA Purification Kit (Promega), following the instructions provided in its protocol. DNA WES was performed through outsourcing sequencing (Macrogen) with a 150x average coverage. WES was performed in two patients diagnosed with HS and DDD (the proband III-2 and the family member III-4) as well as one healthy individual from the family (II-3). Briefly, the exonic sequencing reactions were done using the Illumina® HiSeq 2500 system with the library SureSelect Human all Exons V7 kit in the pair-ended configuration (150 base pairs). After checking the sequencing quality, Illumina adapters were removed with Trim Galore 0.6.1 and FASTQ files were aligned with Software Package Burrows-Wheeler Aligner (BWA) 13 to the Human Genome version 38 (GRCh.38) as a reference. Finally, variants were annotated using ANNOVAR and visualized using the R software v. 4.2.2.

To assess the segregation between the variant and the disease, Sanger sequencing was performed for all the affected individuals using BigDye terminator v3.1 cycle sequencing kit (ThermoFisher Scientific) according to manufacturer's instructions, and analysed with SeqStudio Genetic Analyser (ThermoFisher Scientific). Primers used are indicated in Table 1.

### 2.3 | Cells isolation and culture

Outer root sheath (ORS) keratinocytes were isolated from 10 patients' hairs in anagen phase. Cells were isolated by enzymatic digestion using 0.25% trypsin with 0.03% EDTA at 37°C following the protocol by Rochat et al.<sup>19</sup> To obtain a cell suspension, the isolated

TABLE 1 Primers used in the study.

	Gene	Primer	Sequence (5'-3')	Sequence ID
Sanger sequencing	NCSTN	Forward	ACGATAAGTGTGTGCCCAAG	ENST00000294785
		Reverse	GGTTGGGGTTGTATGAGATGC	
qPCR	OAZ1	Forward	ACTTATTCTACTCCGATGATC	NM_004152.3
		Reverse	GAGAATCCTCGTCTTGTC	
	NCSTN	Forward	GCGTCTACTAGCAGGTTTGT	NM_015331
		Reverse	AAGGACACTGCAAGACCAGC	

Note: qPCR denotes quantitative real-time PCR; NCSTN, nicastrin; OAZ1, ornithine decarboxylase antizyme 1.

cells were filtered through a 40-mm-pore nylon mesh cell strainer (BD Falcon). Cells were grown and maintained following the protocols by Rheinwald and Green<sup>20</sup> in the presence of feeder cells 3T3-J2 (kindly donated by Dr Y. Barrandon). Cells were further amplified and maintained in DermaCult Keratinocyte Expansion Medium (STEMCELL Technologies).

## 2.4 | Cells treatment by read-through agents

ORS keratinocytes from patient III-2 ( $1.5 \times 10^6$  cells) were seeded at ~80% confluency and cultured in DermaCult Keratinocyte Expansion Medium (STEMCELL Technologies) for 24h. Cells were then left untreated or treated with Amlexanox (33.4mM) or Gentamicin (50µM) for additional 24h and lysed for RNA extraction. The experiment was repeated three times.

## 2.5 | Quantitative PCR

About  $2 \times 10^5$  cells were seeded and cultured in DermaCult Keratinocyte Expansion Medium (STEMCELL Technologies) for 3 days to reach confluency. Cells were lysed and RNA extracted using the PureLink RNA Mini Kit (ThermoFisher Scientific), following manufacturer's instructions. NCSTN expression level was measured by quantitative real-time PCR using the kit Takyon™ ROX SYBR 2X MasterMix dTTP blue (Eurogentec). The NCSTN relative expression level was calculated using the  $2^{-\Delta\Delta CT}$  method, and OAZ1 as a house-keeping gene (Table 1).

## 2.6 | Western blot

About  $2 \times 10^5$  cells were seeded and cultured in DermaCult Keratinocyte Expansion Medium (STEMCELL Technologies) for 3 days to reach confluency. Cells were then lysed in RIPA buffer (ThermoFisher Scientific) supplemented with the Halt Protease Inhibitor Cocktail (ThermoFisher Scientific). The protein contents in cell lysates were determined using the Pierce™ BCA Protein Assay Kit (Thermo Fisher Scientific), and the concentrations were adjusted with sample buffer (250mM Tris-HCl, 10% (v/v)

SDS, 50% (v/v) Glycerol, 0.5M β-mercaptoethanol, 0.5% (w/v) Bromophenol blue, pH 6.8) prior to samples boiling 5 min at 95°C. Equal amounts of protein lysates were loaded on 4%–12% Bis-Tris gels (NuPage, Invitrogen) and transferred to 0.2µm pore-size nitrocellulose membranes (ThermoFisher Scientific). Membranes were blocked 30min in PBS supplemented with either 0.1% (v/v) Tween-20 and 4% (w/v) non-fat dried milk or 0.1% (v/v) Tween-20 and 5% (w/v) BSA and incubated up to 12h at 4°C with respective primary antibodies, and 45 min with secondary antibodies diluted in PBS/ 0.1% Tween-20. Membranes were washed 30min at least twice in PBS/ 0.1% Tween-20, developed using ECL Plus western blotting detection system (GE Healthcare) and visualized by Amersham Hyperfilm ECL (GE Healthcare). All molecular weights (MW) were in kDa. Antibodies used in this study: beta Actin Loading Control Monoclonal Antibody (Thermo Fisher Scientific Cat# MA5-15739, RRID:AB\_10979409-1/20000), Invitrogen; Mouse antibody against NCSTN (R and D Systems Cat# MAB53781, RRID:AB\_11128467-1/500); Rabbit antibodies against PSEN1-C (Cell Signaling Technology Cat# 5643, RRID:AB\_10706356-1/1000), PSEN1-N (Cell Signaling Technology Cat# 87146, RRID:AB\_2800100-1/1000); PSEN2 (Cell Signaling Technology Cat# 9979, RRID:AB\_10829910-1/1000), PEN2 (Cell Signaling Technology Cat# 8598, RRID:AB\_11127393-1/1000), and HRP conjugated secondary antibodies against mouse (Cell Signaling Technology Cat# 7076, RRID:AB\_330924-1/2000) and rabbit (Cell Signaling Technology Cat# 7074, RRID:AB\_2099233-1/2000). Densitometry values were obtained using the ImageJ software<sup>21</sup> for proteins of interest and β-actin, as a control protein. Data from at least three different experiments are reported as the ratios of protein of interest/β-actin. This ratio was normalized to wild-type values (individual II-3), which was set to the value of 1.

## 2.7 | Statistical analyses

Statistical analyses were performed using GraphPad Prism (version 9, GraphPad Software) in all experiments that were repeated at least three times. Results were reported as mean ± standard error of the mean (SEM). Statistical analyses between two sets of data were performed by using the two-tailed unpaired Student's *t*-test. Significant

differences between control or treated samples are indicated as \*\*\*\* $p < 0.0001$ , \*\*\* $p < 0.001$ , \*\* $p < 0.01$ , \* $p < 0.05$ . Only  $p < 0.05$  was considered as statistically significant.

### 3 | RESULTS

#### 3.1 | Clinical features

We identified a four-generation family with five affected patients with DDD comorbid with HS (Figure 1). The proband (III-2) was classified with a severe phenotype of HS (Hurley III) characterized by inflammatory nodules, abscess, comedones, interconnected tunnels, scars, sebaceous cysts, follicular hyperkeratosis and folliculitis in several body areas. Apart from her, the other HS/DDD family members have a mild HS phenotype (Hurley I) characterized by several sebaceous cysts ranging in size from small to large, nodules, follicular papules, folliculitis, pyogenic granuloma, scars and single and double comedones in different areas of the body (Figure 2). Some of them also presented inactive pilonidal cyst. In particular, the individual II-2 was also diagnosed with invasive ulcerated squamous cell carcinoma (SCC) located between the inguinal and scrotum regions of the right side. At the time of the examination, patient II-1 did not show active typical HS lesions. Thus, the diagnosis was made based on the scars that were present, and family reports. DDD was characterized by reticulated pigmentations in the armpits and groin, and crateriform/ciribiform scars on the back, nasal dorsum and lip philtrum (Figure 2).

As depicted in Figure 1, one family patient (IV-3) may be affected by HS only. In this case, HS may be presented in an HS conglobate-like type that presents itself like conglobate acne, a severe acne that mainly occurs on a patient's back<sup>22</sup>. However, the patient did not meet the criteria for HS diagnosis, which includes the involvement of HS typical areas of the body: axilla, genitofemoral area, perineum and gluteal area.<sup>18</sup> He reported a history of inflammatory lesions located on the face and back since he was 12 years old. Clinical analysis revealed the presence of erythematous papules, pustules, small nodules, atrophic scars, and simple and double-ended open comedones (pseudocomedones) along the entire length of the back, lumbosacral region and face. A linear lesion was also observed in the right lumbar region, below the waistline, which could correspond to a fistula or a scar. Such findings can occur both in the conglobata HS subtype<sup>23</sup> and in acne, and it is also known that these two conditions can coexist.

#### 3.2 | Identification of a novel variant associated with DDD and HS

We performed WES in two patients of the family affected by HS and DDD, III-2 and III-4, as well as in one healthy individual, II-3. We identified a novel *NCSTN* heterozygous single nucleotide variation (SNV) (NM\_015331.3:c145T>A) located in exon 2, predicted to create a premature stop codon (NP\_056146.1:Leu44Ter[p.L44\*]). The

segregation of this variant was confirmed by Sanger sequencing in all family members. Note that all affected subjects carried the p.L44X variant (Table 2). It is noteworthy that the three unaffected individuals of the fourth generation who have the SNV, have not yet reached puberty, the period associated with HS development.<sup>24</sup> There was also no sign of DDD in these patients, a progressive disease that is acquired over the years.<sup>1</sup>

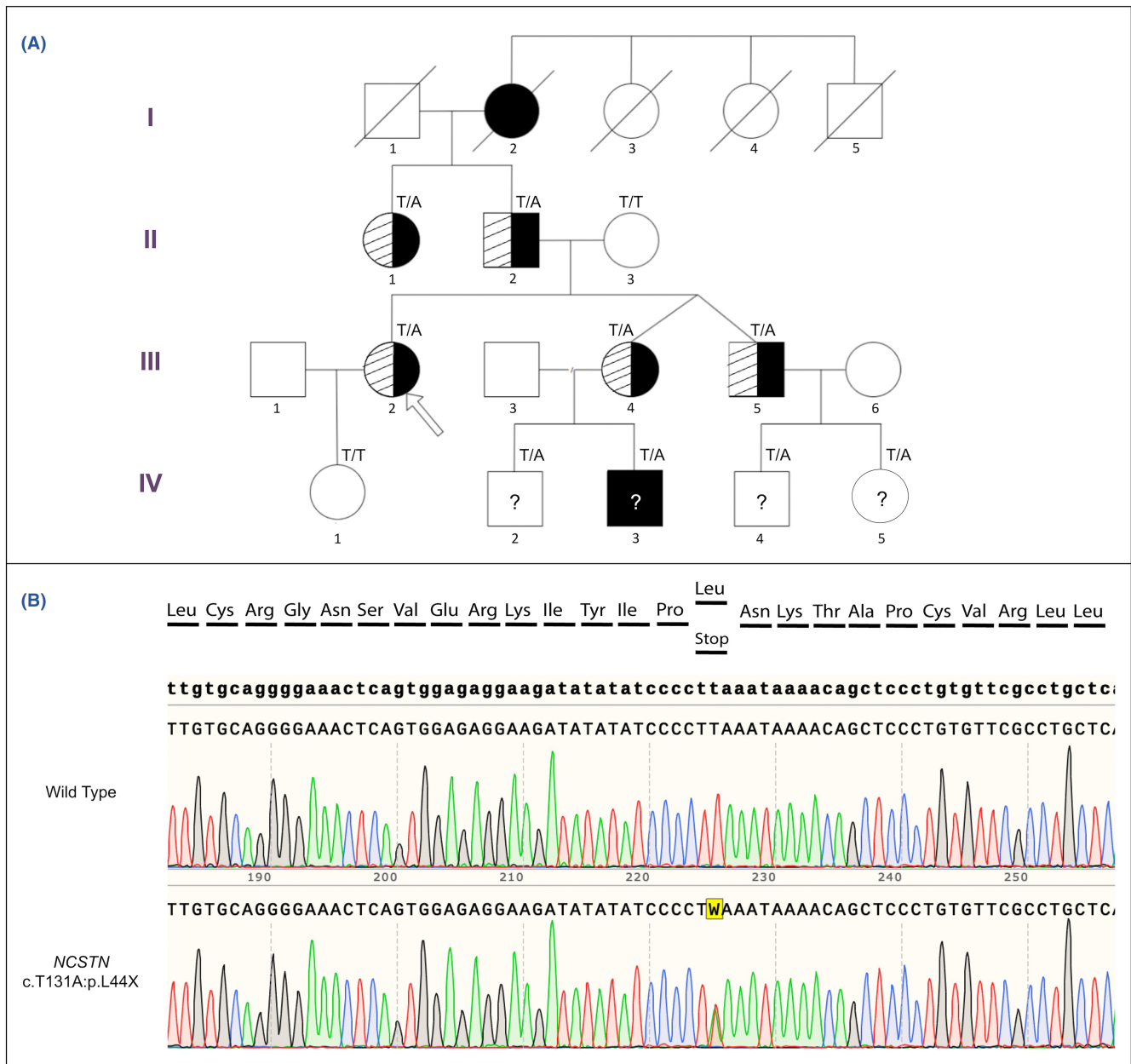
In order to evaluate the impact of this SNV, ORS cells were isolated from plucked hairs of subjects II-3 (healthy control), III-2, III-5 and IV-2 (cases). A significant decrease in both *NCSTN* mRNA and protein level was observed by qPCR and western-blot assays in subjects carrying the heterozygous premature stop codon when compared with the unmutated individual (Figure 3). This suggests that the phenotype observed in mutated individuals results from haploinsufficiency of *NCSTN*.

After confirming *NCSTN* haploinsufficiency in three mutated subjects, we questioned if lower levels of *NCSTN* could be a consequence of NMD surveillance. Since the SNV is predicted to generate a premature termination codon (PTC), a strategy to skip NMD is through the inhibition of this mechanism or through the incorporation of a random amino-acid at the PTC position, causing a PTC read-through.<sup>25</sup> A few commercially available molecules that target NMD have been described.<sup>26,27</sup> To answer this question, we treated the III-2 ORS cells with two of these compounds, amlexanox and gentamicin (Figure 3C). As seen in Figure 3C, after treating cells, levels of *NCSTN* mRNA were significantly increased, corroborating that the mutation was activating the NMD mechanism in these cells.

#### 3.3 | Evaluation of gamma-secretase subunits stability

Since pathogenic mutations in genes that were previously associated with DDD namely *KRT5*, *POGLUT1*, *POFUT1* and *PSENEN*, were not found (Table S1), it is safe to assume that the *NCSTN* mutation was associated with both conditions in this family. *NCSTN* belongs to the gamma-secretase complex alongside *PSENEN* and other genes. As mutations in *PSENEN* have already been reported in subjects with both HS and DDD, we wondered whether haploinsufficiency of *NCSTN* could lead to gamma-secretase complex instability or degradation of its subunits. We thus evaluated mRNA and protein relative expression levels of *PSEN1*, *PSEN2* and *PSENEN* in mutated and non-mutated subjects' ORS cells. There was no statistically significant difference between patients and control regarding the mRNA levels of these genes (not shown). However, protein levels of these gamma-secretase subunits were significantly lower in two out of three mutated individuals when compared with the unmutated one (Figure 4). This suggests that *NCSTN* haploinsufficiency may result in protein degradation of the other subunits of the gamma-secretase complex. Interestingly, the individual IV-2, who carries the mutation but has not developed HS yet, has significantly lower levels of *NCSTN* mRNA and the



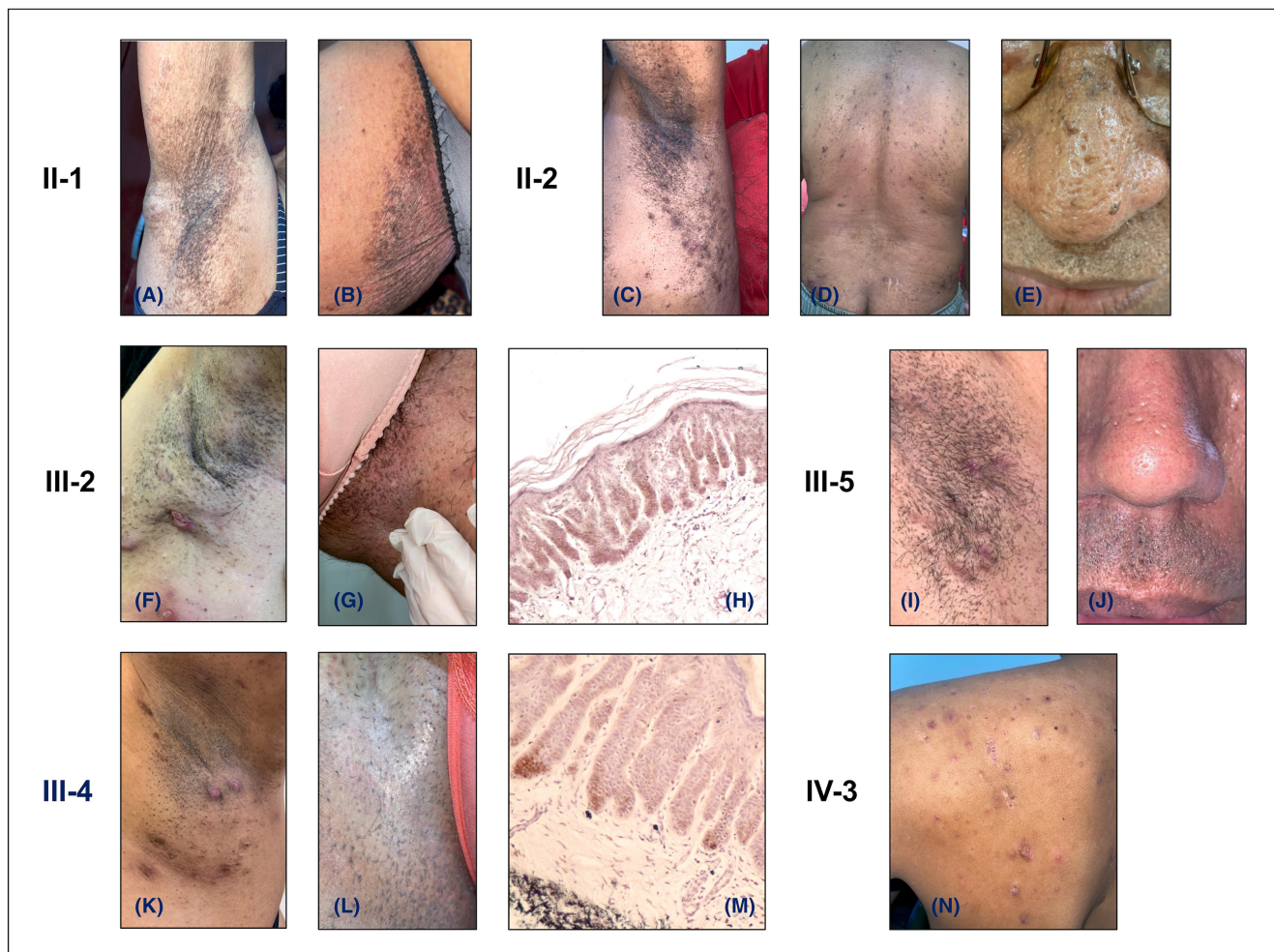


**FIGURE 1** (A) Family pedigree of the four-generation Brazilian family affected by HS and DDD. The arrow refers to the proband. Males are shown with squares and females with circles. A diagonal line indicates deceased individuals. HS and DDD are shown with solid and hatched patterns, respectively, whereas unaffected individuals are shown with clear symbols. T/A genotype indicates the presence of the variant at the *NCSTN*, NM\_015331.3:c145T>A; NP\_056146.1:Leu44Ter[p.L44\*], while T/T indicates the wild type. Patients with question marks carry the mutation but have not yet developed the disease or have an inconclusive diagnosis. (B) Partial sequence of the exon 2 of the *NCSTN* gene. The top electrogram belongs to the control (II-3), whereas the bottom one belongs to the patient III-2, indicating the mutation, NM\_015331.3:c145T>A.

immature form of the protein but normal levels of its mature form. In this patient, the protein levels of the other gamma-secretase subunits were not significantly different from the unmutated subject, corroborating the hypothesis that the HS and DDD phenotypes may result from a lower level of the whole gamma-secretase complex. Altogether, our results support the hypothesis that the *NCSTN* mutation is not only responsible for HS onset in these patients; it is also associated with gamma-secretase instability that causes DDD.<sup>28</sup>

## 4 | DISCUSSION

To date, LOF mutations in *KRT5*, *POGLUT1* and *POFUT1* have been associated with DDD and its acantholytic form GGD.<sup>3,29</sup> LOF mutations in *PSENFEN* were first associated with HS<sup>11</sup> and then found in patients affected by DDD or presenting DDD comorbid with HS.<sup>1,14</sup> The opposite holds true for *POFUT1*, whose mutations were first associated with DDD and later described in sporadic patients presenting both HS and DDD.<sup>30,31</sup> Recently, sporadic patients suffering



**FIGURE 2** (A–K,M,N) Skin images of the affected family members. (A) hyperpigmented macules in a reticulate pattern in the axillary region; (B) hyperpigmented macules in a reticulate pattern in the groin and inner thigh; (C) hyperpigmented macules in a reticulate pattern, comedones, follicular papules and nodules in the axillary region; (D) cribriform scars on the back; (E) cribriform scars on the nasal dorsum and lip philtrum; (F) hyperpigmented macules in a reticulate pattern, nodules and sinus tracts in the axillary region; (G) hyperpigmented macules in a reticulate pattern in the groin and inner thigh; (I) hyperpigmented macules in a reticulate pattern, nodules and atrophic scars in the axillary region; (J) cribriform scars on the nasal dorsum and lip philtrum; (K) nodules in the axillary region; (L) hyperpigmented macules in a reticulate pattern in the groin; (N) nodules and cribriform scars on the back. (H, M) Histologic images of DDD biopsies show filiform acanthosis in an ‘antler-like’ pattern with hyperpigmentation in the basal layer; haematoxylin and eosin stain, magnification (H) 5 $\times$  and (M) 10 $\times$ .

from HS and DDD have been described with damaging mutations in *NCSTN*.<sup>32</sup> Garcovich et al.<sup>28</sup> have also identified a nonsense *NCSTN* mutation associated with familial HS where the older father also suffered from DDD. Even with those results, the *NCSTN* role in DDD remains debated for the lack of sufficient evidence.

Here, we describe the first family where HS and DDD cosegregated across two generations. All patients carried a nonsense mutation in the *NCSTN* gene (NM\_015331.3:c145T>A; NP\_056146.1:Leu44Ter[p.L44\*]), including five of them with HS and DDD. This demonstrates that *NCSTN* should be considered as a gene associated with DDD comorbid with HS. It remains to be understood whether, in the case of mutations in *NCSTN*, DDD is a subphenotype of HS or the opposite is true.

In this family, affected members suffer from a follicular HS phenotype and developed folliculitis and opened and closed comedones,

which are characteristics of HS patients carrying *NCSTN* mutations.<sup>33</sup> Interestingly, out of the five family members with a conclusive diagnosis of HS and DDD, only the proband was diagnosed with a severe HS phenotype. The others have a mild HS phenotype, thus supporting the hypothesis by Garcovich et al. that DDD lesions become clinically evident when HS skin inflammation is kept at bay.<sup>28</sup> As for the onset age, these five individuals suffering from DDD and HS developed HS symptoms around the age of 15, 5 years earlier than the age reported by Xu et al.<sup>33</sup> while DDD lesions probably arose later as they usually have an age of onset between 20 and 50 years.<sup>34</sup> This could be recapitulated by the clinical history of the patient IV-3, who has not been diagnosed with HS but has been suffering from conglobate acne since the age of 12 and still does not show any DDD lesions at the age of 17. Moreover, his clinical history indicates that the *NCSTN* nonsense mutation NM\_015331.3:c145T>A causes HS

TABLE 2 Clinical features of the HS and DDD family individuals.

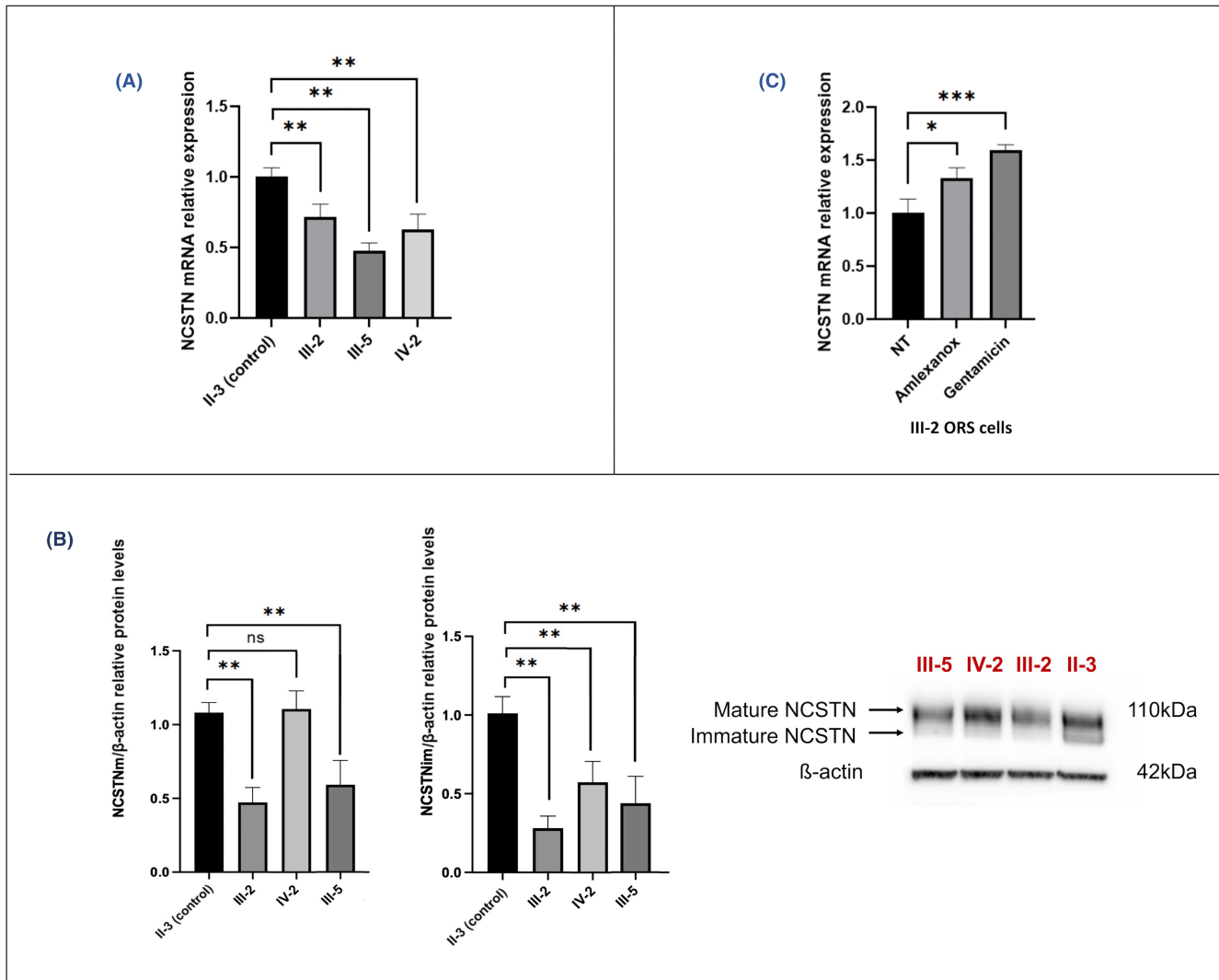
ID	II-1	II-2	II-3	III-2	III-4	III-5	IV-1	IV-2	IV-3	IV-4	IV-5
Sex	F	M	F	F	F	M	F	M	M	M	F
Age	60	65	68	37	36	36	15	11	17	12	10
Age when HS started	NA	17	-	15	15	15	-	-	12	-	-
BMI	NA	37.52	NA	27.13	37.98	33.22	NA	NA	18.7	NA	NA
Smoker	NA	-	NA	-	-	+	NA	NA	-	NA	NA
NCSTN, c.T131A:p.L44X	+	+	-	+	+	+	-	+	+	+	+
DDD	+	+	-	+	+	+	-	-	-	-	-
Face	-	+	-	-	-	+	-	-	-	-	-
Trunk	-	+	-	+	-	-	-	-	-	-	-
Axillae	+	+	-	+	-	+	-	-	-	-	-
Inguinal folds	+	NA	-	+	+	-	-	-	-	-	-
DDD histology	-	-	-	+	+	NA	-	NA	NA	NA	NA
HS	+	+	-	+	+	+	-	-	?	-	-
Axillae	+	+	-	+	+	+	-	-	-	-	-
Inframammary region	NA	-	-	-	+	-	-	-	-	-	-
Inguinal folds	NA	+	-	+	+	-	-	-	-	-	-
Genitals	NA	+	-	-	-	-	-	-	-	-	-
Trunk	NA	+	-	-	-	-	-	-	+	-	-
Sebaceous cyst	NA	+	-	NA	+	-	-	-	+	-	-
Hurley	I	I	-	III	I	I	-	-	Acne conglobata?	-	-
Comorbidities											
Metabolic syndrome	NA	+	NA	-	-	NA	NA	NA	NA	NA	NA
Type 2 diabetes mellitus	+	+	NA	-	-	-	NA	NA	-	NA	NA
Systemic hypertension	+	+	NA	-	-	+	NA	NA	-	NA	NA
Squamous cell carcinoma	-	+	-	-	-	-	NA	NA	-	NA	NA
Pilonidal cyst	NA	+	NA	+	+	+	NA	NA	-	NA	NA
Acne	-	-	NA	-	+	-	NA	NA	+	NA	NA

Note: F denotes female; M, male; NA, information is not available; +, presence of a feature; -, absence of a feature.

even in the absence of predisposing factors such as obesity, present in the adults with HS and DDD of this family, and cigarette smoking. Finally, patient II-2 showed the association of HS, DDD and ulcerated SCC that has been reported in many patients suffering from HS and DDD.<sup>35,36</sup>

Regarding the pathogenic mechanisms, *NCSTN* deficiency has been found to impact keratinocyte differentiation and proliferation, responsible for cyst formation and hyperkeratosis commonly observed in HS patients.<sup>33</sup> Patients with HS and DDD carrying *PSENEN* mutations were also distinguished by follicular hyperkeratosis,<sup>12</sup> suggesting a potential link between gamma-secretase dysfunction and keratinocyte proliferation. Wild-type mice treated with a gamma-secretase inhibitor corroborate the association between this enzymatic inhibition and epidermal abnormalities.<sup>37</sup> Moreover, since most of the genes mutated in DDD and HS encode for proteins with roles in ligand-dependent NOTCH receptors processing or their post-translational

maturation, the common hypothesis is that a decreased NOTCH signalling is the common pathogenic mechanism leading to both HS and DDD. However, NOTCH signalling-deficient mice showed a coat colour dilution and hair greying that resulted from abnormally localized and differentiated melanocyte stem cells and melanoblasts in the hair follicles.<sup>38,39</sup> The association of *NCSTN* with pigmentation defects was studied mainly in zebrafish (ZF). A *Ncstn* LOF mutation induced tyrosinase leakage out of melanosomes causing the necrotic death of melanophores and mis-pigmentation of ZF.<sup>40</sup> Another recent study showed that knock down *Ncstn* larvae had a defect in melanophore migration, shape and number resulting in non-homogenous body pigmentation<sup>41</sup> as already shown for *Psenen* knock down larvae.<sup>12</sup> Noteworthy, in humans, no difference in melanocytes number or tissue distribution were associated with DDD; instead, an atypical biogenesis of melanosomes in melanocytes and their subcellular distribution or retention in basal keratinocytes are key features



**FIGURE 3** Quantification of *NCSTN* mRNA (A) and protein levels (B) present in patients' ORS cells through real-time PCR and western-blot, respectively. Mature (left) and immature (right) *NCSTN* have been quantified separately. (C) III-2 ORS cells were treated either with Amlexanox (33.4 mM) or Gentamicin A (50  $\mu$ M). *NCSTN* mRNA levels were then evaluated by qPCR and compared with non-treated (NT) III-2 ORS cells. Expression levels were compared using Student *t*-tests. Bar graphs represent the mean  $\pm$  standard deviation,  $n=3$ . \* $p < 0.05$ ; \*\* $p < 0.01$ ; \*\*\* $p < 0.001$ ; ns, non-significant.

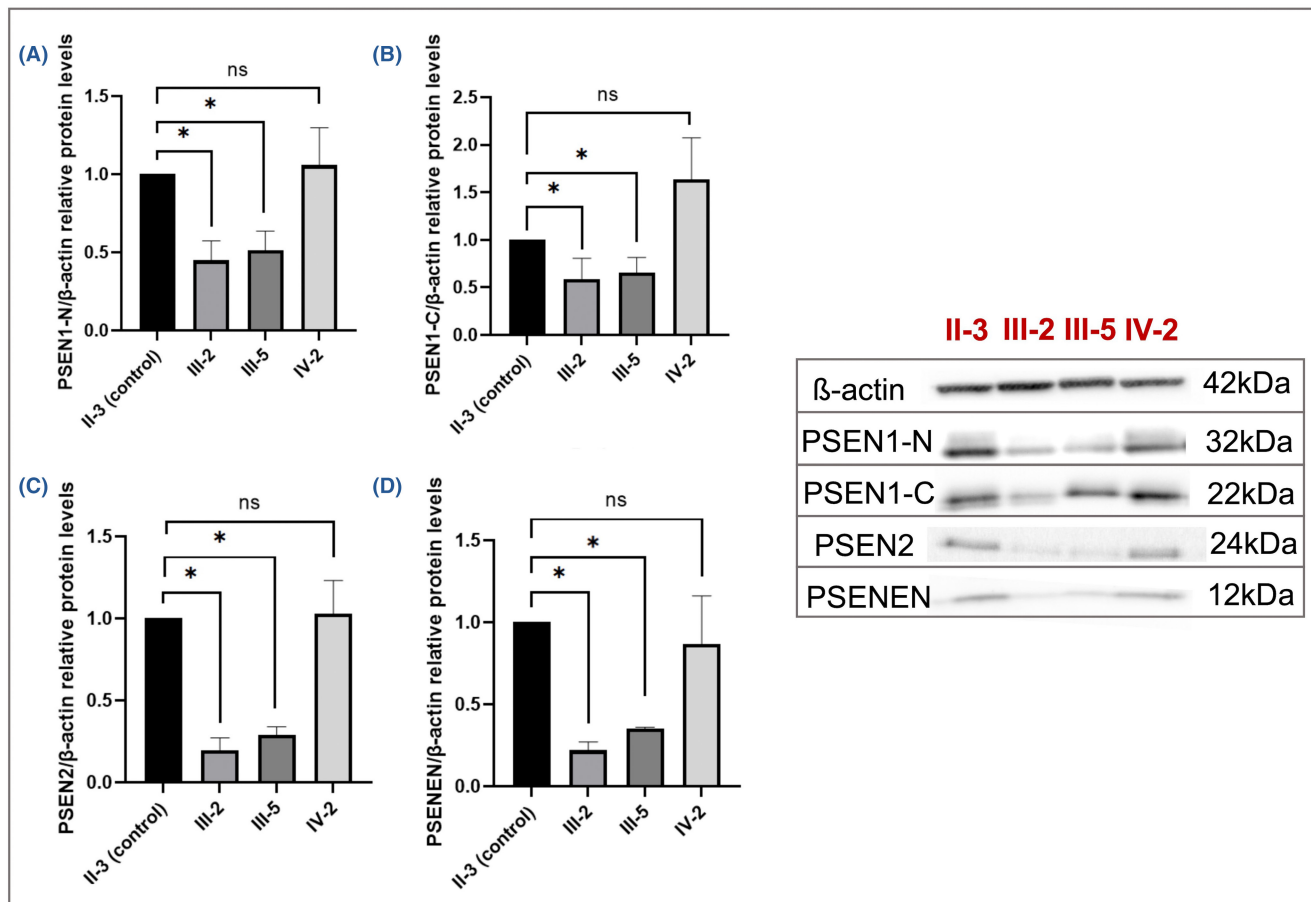
of the disease.<sup>42,43</sup> Therefore, we can hypothesize that other biological activities of *NCSTN* may be responsible for DDD in these patients as it is known that *NCSTN* is localized in melanosome membranes in all their maturation stages<sup>44</sup> and its role in their biogenesis and degradation requires a deeper investigation. We can also conjecture that the deficiency of *NCSTN* mature form led to the degradation of other gamma-secretase subunits such as *PSEN-1*, *PSEN-2* and *PSENEN*. Thus, *NCSTN* deficiency may mimic the effect of *PSENEN* LOF mutations reducing its expression that was recently correlated with increased melanin content in human melanocytes.<sup>45</sup>

Finally, in an attempt to restore *NCSTN* expression in ORS keratinocytes isolated from the patient with the most severe phenotype, we used two Food and Drug Administration (FDA) approved read-through agents: gentamicin and amlexanox. These 2 compounds have been successfully used to treat severe genodermatoses.<sup>46,47</sup>

Gentamicin, in particular, has been shown to reduce infections in HS patients undergoing surgical excision with primary closure without negative side effects.<sup>48</sup>

These findings support the hypothesis that DDD and SCC are complications that may arise in HS patients with mutations in *NCSTN* and should be paid careful attention by dermatologists during clinical exams. Why some patients with *NCSTN* mutations do not develop such complications is not yet understood. In our family, the two HS/DDD-affected members analysed by WES harboured a relatively frequent SNV in the *KRT5* gene (rs61747180), and we cannot rule out that this polymorphism or other common genetic polymorphisms may account for the co-occurrence of HS and DDD. In this respect, it is intriguing that in the individual IV-2, the *NCSTN* SNV was associated with a significant decrease of its mRNA but the quantity of the gamma-secretase proteins was comparable to the healthy family member II-3. This indicates that





**FIGURE 4** (A) Quantification of PSEN1 N-terminal protein; (B) PSEN1 C-terminal protein; (C) PSEN2 protein; (D) presenilin enhancer protein 2 (PEN-2) (encoded by *PSENEN*) levels present in subjects' ORS cells. Expression levels were compared using Student t-tests. Bar graphs represent the mean  $\pm$  standard deviation,  $n=3$ . \* $p < 0.05$ ; ns, non-significant.

genetic variants in other biological pathways may affect the quantity of the gamma-secretase subunits, even in the presence of a pathogenic variant.

In conclusion, our study shows the possibilities of genetic and functional analyses for precision medicine in our patients. Herein, *NCSTN* expression in ORS keratinocytes isolated from a severe patient was increased upon treatment with an FDA-approved antibiotic that acts as a readthrough agent. Therefore, to ease the clinical course of the disease, the use of gentamicin should be investigated in individuals bearing this mutation.

#### AUTHOR CONTRIBUTIONS

Ana Sofia Lima Estevao de Oliveira, Roberta Cardoso de Siqueira, Cécile Nait-Meddour, Michele Boniotto and Lucas André Cavalcanti Brandão designed and performed experiments, analysed the data, and wrote the manuscript. Almerinda Agrelli, Paola Maura Tricarico, Sergio Crovella and Stéphane Jamain reviewed and edited the paper. Stéphane Jamain, Cécile Nait-Meddour and Ronald Moura provided technical support and performed statistical analyses. Paola Maura Tricarico, Maria de Fátima Medeiros Brito, Sergio Crovella and Adamo Pio d'Adamo analysed the data and

contributed essential reagents, tools, and funding acquisition. All authors have read and approved the final version of the manuscript. All authors contributed substantially to the conception and the design of the study, data analysis, manuscript writing, and final revision.

#### ACKNOWLEDGEMENTS

This work was supported by 'Conselho Nacional de Desenvolvimento Científico e Tecnológico (CNPq)' (311415/2020-2 and 430353/2018-9), by Fondation René Touraine, by Starting Grant (SG-2019-12369421) founded by the Italian Ministry of Health, by grants (RC16/2018 and RC03/2020) from the Institute for Maternal and Child Health IRCCS 'Burlo Garofolo' funded by the Italian Ministry of Health, and by EraPerMed 2018-17 European Community funds (JTC\_2018). A.S.L.E.O is supported by Coordenação de Aperfeiçoamento de Pessoal de Nível Superior-Brasil (CAPES)-Finance Code 001, and L.A.C.B is supported by CNPq (311415/2020-2).

#### CONFLICT OF INTEREST STATEMENT

The authors have no conflicts of interest to declare.



## DATA AVAILABILITY STATEMENT

The data that supports the findings of this study are openly available in the Sequence Read Archive (SRA) database, <https://www.ncbi.nlm.nih.gov/sra/PRJNA801118>. Further enquiries can be directed to the corresponding author.

## ORCID

Ana Sofia Lima Estevas de Oliveira  <https://orcid.org/0000-0001-9540-6756>

[org/0000-0001-9540-6756](https://orcid.org/0000-0001-9540-6756)

Michele Boniotto  <https://orcid.org/0000-0002-9548-2254>

## REFERENCES

- Ren J, Zeng LY. Scrotal Dowling-Degos disease caused by a novel frameshift variant in gamma-secretase subunit presenile enhancer gene. *Australas J Dermatol*. 2020;61(4):e399-e402.
- Betz RC, Planko L, Eigelshoven S, et al. Loss-of-function mutations in the keratin 5 gene lead to Dowling-Degos disease. *Am J Hum Genet*. 2006;78(3):510-519.
- Schmieder A, Pasternack SM, Krahl D, Betz RC, Leverkus M. Galli-Galli disease is an acantholytic variant of Dowling-Degos disease: additional genetic evidence in a German family. *J Am Acad Dermatol*. 2012;66(6):e250-e251.
- Hanneken S, Rutten A, Pasternack SM, et al. Systematic mutation screening of KRT5 supports the hypothesis that Galli-Galli disease is a variant of Dowling-Degos disease. *Br J Dermatol*. 2010;163(1):197-200.
- Basmanav FB, Oprisoreanu AM, Pasternack SM, et al. Mutations in POGUT1, encoding protein O-glucosyltransferase 1, cause autosomal-dominant Dowling-Degos disease. *Am J Hum Genet*. 2014;94(1):135-143.
- Li M, Cheng R, Liang J, et al. Mutations in POFUT1, encoding protein O-fucosyltransferase 1, cause generalized Dowling-Degos disease. *Am J Hum Genet*. 2013;92(6):895-903.
- Dunstan RW, Salte KM, Todorovic V, et al. Histologic progression of acne inversa/hidradenitis suppurativa: implications for future investigations and therapeutic intervention. *Exp Dermatol*. 2021;30(6):820-830.
- Matusiak L. Profound consequences of hidradenitis suppurativa: a review. *Br J Dermatol*. 2020;183(6):e171-e177.
- Duchatelet S, Miskinyte S, Delage M, et al. Low prevalence of GSC gene mutations in a large cohort of predominantly Caucasian patients with hidradenitis suppurativa. *J Invest Dermatol*. 2020;140:2085-2088.e14.
- Weber LA, Kantor GR, Bergfeld WF. Reticulate pigmented anomaly of the flexures (Dowling-Degos disease): a case report associated with hidradenitis suppurativa and squamous cell carcinoma. *Cutis*. 1990;45(6):446-450.
- Wang B, Yang W, Wen W, et al. Gamma-secretase gene mutations in familial acne inversa. *Science*. 2010;330(6007):1065.
- Ralser DJ, Basmanav FB, Tafazzoli A, et al. Mutations in gamma-secretase subunit-encoding PSENEN underlie Dowling-Degos disease associated with acne inversa. *J Clin Invest*. 2017;127:1485-1490.
- Zhou C, Wen GD, Soe LM, Xu HJ, Du J, Zhang JZ. Novel mutations in PSENEN gene in two Chinese acne Inversa families manifested as familial multiple comedones and Dowling-Degos disease. *Chin Med J (Engl)*. 2016;129(23):2834-2839.
- Pavlovsky M, Sarig O, Eskin-Schwartz M, et al. A phenotype combining hidradenitis suppurativa with Dowling-Degos disease caused by a founder mutation in PSENEN. *Br J Dermatol*. 2017;178:502-508.
- Wolfe MS. Structure and function of the gamma-secretase complex. *Biochemistry*. 2019;58(27):2953-2966.
- Gratton R, Tricarico PM, Moltrasio C, et al. Pleiotropic role of notch signaling in human skin diseases. *Int J Mol Sci*. 2020;21(12):1-29.
- Takeuchi H, Yu H, Hao H, et al. O-glycosylation modulates the stability of epidermal growth factor-like repeats and thereby regulates notch trafficking. *J Biol Chem*. 2017;292(38):15964-15973.
- Zouboulis CC, Desai N, Emtestam L, et al. European S1 guideline for the treatment of hidradenitis suppurativa/acne inversa. *J Eur Acad Dermatol Venereol*. 2015;29(4):619-644.
- Rochat A, Kobayashi K, Barrandon Y. Location of stem cells of human hair follicles by clonal analysis. *Cell*. 1994;76(6):1063-1073.
- Rheinwald JG, Green H. Epidermal growth factor and the multiplication of cultured human epidermal keratinocytes. *Nature*. 1977;265(5593):421-424.
- Schneider CA, Rasband WS, Eliceiri KW. NIH image to ImageJ: 25 years of image analysis. *Nat Methods*. 2012;9(7):671-675.
- Pink AE, Simpson MA, Desai N, Trembath RC, Barker JN. Gamma-secretase mutations in hidradenitis suppurativa: new insights into disease pathogenesis. *J Invest Dermatol*. 2013;133(3):601-607.
- van der Zee HH, Jemec GB. New insights into the diagnosis of hidradenitis suppurativa: clinical presentations and phenotypes. *J Am Acad Dermatol*. 2015;73(5 Suppl 1):S23-S26.
- Napolitano M, Megna M, Timoshchuk EA, et al. Hidradenitis suppurativa: from pathogenesis to diagnosis and treatment. *Clin Cosmet Investig Dermatol*. 2017;10:105-115.
- Sharma J, Du M, Wong E, et al. A small molecule that induces translational readthrough of CFTR nonsense mutations by eRF1 depletion. *Nat Commun*. 2021;12(1):4358.
- Morais P, Adachi H, Yu YT. Suppression of nonsense mutations by new emerging technologies. *Int J Mol Sci*. 2020;21(12):1-14.
- Keeling KM, Xue X, Gunn G, Bedwell DM. Therapeutics based on stop codon readthrough. *Annu Rev Genomics Hum Genet*. 2014;15:371-394.
- Garcovich S, Tricarico PM, Nait-Meddour C, et al. Novel nicastatin mutation in hidradenitis suppurativa-Dowling-Degos disease clinical phenotype: more than just clinical overlap? *Br J Dermatol*. 2020;183(4):758-759.
- Wilson NJ, Cole C, Kroboth K, et al. Mutations in POGUT1 in Galli-Galli/Dowling-Degos disease. *Br J Dermatol*. 2017;176(1):270-274.
- Garcia-Gil MF, Monte Serrano J, Ramirez-Lluch M, Valero Torres A, Lopez-Gimenez MT, Lezcano BV. A novel mutation in POFUT1 gene associated with Dowling-Degos disease and hidradenitis suppurativa. *Int J Dermatol*. 2021;60(1):e25-e27.
- Gonzalez-Villanueva I, Gutierrez M, Hispan P, Betlloch I, Pascual JC. Novel POFUT1 mutation associated with hidradenitis suppurativa-Dowling-Degos disease firm up a role for notch signalling in the pathogenesis of this disorder. *Br J Dermatol*. 2018;178(4):984-986.
- González-Villanueva I, Álvarez-Chinchilla P, Gutiérrez M, Ramírez JCP. Hidradenitis suppurativa/Dowling-Degos disease (DDD) phenotype associated with mutations in NCSTN gene. 2019 Poster presented at 8th European Hidradenitis Suppurativa Foundation (EHSF) February 2019; Wrocław, Poland.
- Xu H, Xiao X, Hui Y, et al. Phenotype of 53 Chinese individuals with nicastatin gene mutations in association with familial hidradenitis suppurativa (acne inversa). *Br J Dermatol*. 2016;174(4):927-929.
- Georgescu EF, Stanescu L, Popescu CF, Comanescu M, Georgescu I. Dowling-Degos disease. *Rom J Morphol Embryol*. 2010;51(1):181-185.
- Li M, Hunt MJ, Commens CA. Hidradenitis suppurativa, Dowling-Degos disease and perianal squamous cell carcinoma. *Australas J Dermatol*. 1997;38(4):209-211.
- Ujihara M, Kamakura T, Ikeda M, Kodama H. Dowling-Degos disease associated with squamous cell carcinomas on the dappled pigmentation. *Br J Dermatol*. 2002;147(3):568-571.
- Li T, Wen H, Brayton C, et al. Epidermal growth factor receptor and notch pathways participate in the tumor suppressor function of gamma-secretase. *J Biol Chem*. 2007;282(44):32264-32273.

38. Aubin-Houzelstein G, Djian-Zaouche J, Bernex F, et al. Melanoblasts' proper location and timed differentiation depend on notch/RBP-J signaling in postnatal hair follicles. *J Invest Dermatol.* 2008;128(11):2686-2695.
39. Schouwey K, Delmas V, Larue L, et al. Notch1 and Notch2 receptors influence progressive hair graying in a dose-dependent manner. *Dev Dyn.* 2007;236(1):282-289.
40. Hsu CH, Liou GG, Jiang YJ. Nicastrin deficiency induces tyrosinase-dependent depigmentation and skin inflammation. *J Invest Dermatol.* 2020;140(2):404-414 e413.
41. Hermasch MA, Janning H, Perera RP, et al. Evolutionary distinct roles of gamma-secretase subunit nicastrin in zebrafish and humans. *J Dermatol Sci.* 2022;105(2):80-87.
42. Yu W-T, Su Y-S, Lee C-H. A Taiwanese woman with Dowling-Degos disease: an electron microscopic study with pathophysiological significance. *Dermatologica Sinica.* 2014;32(1):33-36.
43. Zhang RZ, Zhu WY. A study of immunohistochemical and electron microscopic changes in Dowling-Degos disease. *J Dermatol.* 2005;32(1):12-18.
44. Chi A, Valencia JC, Hu ZZ, et al. Proteomic and bioinformatic characterization of the biogenesis and function of melanosomes. *J Proteome Res.* 2006;5(11):3135-3144.
45. Bajpai VK, Swigut T, Mohammed J, et al. A genome-wide genetic screen uncovers novel determinants of human pigmentation. *bioRxiv.* 2021;2021.09.29.462413.
46. Wang S, Yang Z, Liu Y, et al. Application of topical gentamicin-a new era in the treatment of genodermatosis. *World J Pediatr.* 2021;17(6):568-575.
47. Atanasova VS, Jiang Q, Prisco M, et al. Amlexanox enhances premature termination codon read-through in COL7A1 and expression of full length type VII collagen: potential therapy for recessive dystrophic epidermolysis bullosa. *J Invest Dermatol.* 2017;137(9):1842-1849.
48. Buimer MG, Ankersmit MF, Wobbles T, Klinkenbijn JH. Surgical treatment of hidradenitis suppurativa with gentamicin sulfate: a prospective randomized study. *Dermatol Surg.* 2008;34(2):224-227.

## SUPPORTING INFORMATION

Additional supporting information can be found online in the Supporting Information section at the end of this article.

**Table S1** Variants found in genes associated with DDD by WES analysis in the affected patients III-2 and III-4 but absent in the healthy individual II-3.

**How to cite this article:** de Oliveira ASLE, de Siqueira RC, Nait-Meddour C, et al. A loss-of-function *NCSTN* mutation associated with familial Dowling Degos disease and hidradenitis suppurativa. *Exp Dermatol.* 2023;00:1-11. doi:[10.1111/exd.14919](https://doi.org/10.1111/exd.14919)