

ON TWO NEW HAEMOGREGARINES (PROTOZOA: APICOMPLEXA) FROM COLUBRID AND ELAPIDAE SNAKES IN EGYPT

By

MOHAMMAD FATHY A. SAOUD,^{1,2} NADIA F. RAMDAN,¹
SHADIA H. MOHAMMED¹ AND SAMIA M. FAWZI¹

¹Department of Zoology, Faculty of Science, University of Ain Shams, Cairo, Egypt

²Department of Zoology, Faculty of Science, University of Qatar, Doha, State of Qatar

نوعان جديدان من الهيموجريجارينات في دم نوعين من الثعابين في مصر

محمد فتحي عبد الفتاح سعود و نادية فريد رمضان
شادية حسن محمد و سامية محمود فوزي

وصف المؤلفون نوعين من طفيليات الدم الأولية التي تصيب نوعين من الثعابين في مصر ، هما هيموجريجارينا جارنامي الذي يصيب ثعبان أبو السيور شوكرى الجبلي ، هيموجريجارينا أسواننسز الذي يصيب ثعبان الكوبرا . ويتضمن البحث وصفا كاملا لمختلف مراحل نمو الهيموجريجارينات في خلايا الدم الحمراء وكذلك في أنسجة الرئتين أو / والكبد ، كما ناقش المؤلفون الأسس التي تم الاعتماد عليها في تمييز النوعين الجديدين عن الأنواع الأخرى المشابهة التي سبق التعرف عليها من الثعابين .

Key Words: New Haemogregarines, Colubrid and Elapid snakes, Egypt.

ABSTRACT

Two species of colubrid and elapid snakes collected from different localities in Egypt were examined for protozoan blood parasites. Two new species of *Haemogregarina* sensu lato are described: *Haemogregarina garnhami* n.sp. is described from 65.2% of *Psammophis schokari aegyptius* collected from El-Faiyum, El Bahariya Oases and Aswan and *Hg. aswanensis* n.sp. is reported in one specimen out of four *Naja haje* collected from Aswan in Upper Egypt. Blood and tissue stages are described for the two species of haemogregarines and are compared with eight species of haemogregarines reported previously from snakes in Egypt.

INTRODUCTION

Haemogregarines of snakes have attracted the attention of several investigators working in Africa, e.g. Laveran [1], Billet [2] and Sergent [3] in North Africa; Sambon and Seligman [4, 5], Wenyon [6], Hoare [7], Garnham [8], Bell *et al.* [9] and Landau *et al.* [10] in East Africa and Pierce [11] in Central Africa.

In Egypt, some snakes were surveyed for protozoan blood parasites by Mohammed and Mansour [12] who reported unnamed haemogregarines in *Eryx colubrina*, *Malpolon moilensis*, *Cerastes vipera* and *Naja haje*. Ramadan [13] described three new species of haemogregarines which were named tentatively: *Haemogregarina arabi*, *Hg*. matruhensis* and *Hg*. malpoloni*

* *Hg.* and *Hp.* are used throughout the text for the two genera *Haemogregarina* and *Hepatozoon* respectively.

from *Telescopus dhara obtusus*, *Psammophis schokari* and *Malpolon monspessulanus insignitus* respectively. Bashtar *et al.* [14,15] identified and described the life cycle of *Hepatozoon aegypti* from *Spalerosophis diaderma* by light and electron microscopy. Abdel Ghaffar [16] described by both light and electron microscopy a haemogregarine infecting *Cerastes vipera*. A similar study was also published on the life cycle of *Haemogregarina najae* in *Naja nigricollis nigricollis* [17]. Abdel Ghaffar *et al.* [18,19] described erythrocytic, exoerythrocytic and sporogony stages of *Hepatozoon seurati* Laveran and Pettit, 1911 from *Cerastes cerastes* in Egypt. Recently, *Hepatozoon mehlhorni* has been described together with its complete development in *Echis carinatus* and *Culex pipiens* [20].

During the present work, two new haemogregarines are described from *Psammophis schokari aegyptius* and *Naja haje* at certain localities in Egypt.

MATERIAL AND METHODS

Twenty three specimens of *Psammophis schokari aegyptius*, collected from Aswan, El Faiyum and El Bouaty Oasis in El Bahariya Oases, and four snakes of *Naja haje haje*, collected from Aswan, were examined for blood parasites. Blood smears were made from living and freshly killed animals, and smears were stained with Giemsa's stain [21].

The lungs and liver of heavily infected specimens were fixed in Bouin's fluid for 24 hours or in Carnoy's solution for 2 hours, then washed, dehydrated, cleared, embedded in paraplast and sectioned. Sections, 5 μm thick were stained with Delafield's haematoxylin and eosin for detecting the parasite stages. Measurements were taken from original drawings made by a camera lucida, using a calibrated divider. Photomicroscopy was made using Nikon AFX research microscope.

DESCRIPTION

I -HAEMOGREGARINA GARNHAMI N.SP.

Out of twenty three *Psammophis schokari aegyptius* examined for blood parasites, fifteen specimens were found positive for haemogregarines with an overall prevalence of 65.2%. Different blood forms were seen in erythrocytes, while tissue stages were observed only in the lungs of infected snakes.

1. Blood forms (Plates I and II)

Two developmental stages occurred in red blood corpuscles; trophozoites and gametocytes.

1.1 Trophozoites (Figs. 1-8 and 15-19).

Giemsa - stained trophozoites appeared as sausage-shaped intra-erythrocytic bodies that lied parallel to the longitudinal axes of the blood cells. Some trophozoites had slightly tapering ends (Figs. 3 and 17); they measured 10-20 μm long and 2-5 μm broad. The nucleus was elongate, filling the whole width of the central

part of the parasite (Figs. 1 and 4), but sometimes it was slightly pushed towards one of the two ends (Figs. 6,7 and 17). The nucleus measured 2.5 - 7.5 μm long and 2 - 5 μm broad. It stained red with Giemsa's stain and often appeared as a rough transverse band containing some dark granules. The parasite's cytoplasm usually stained faint pink to light red, containing some scattered red - staining fine granules which appeared condensed at the two ends (Fig. 5).

1.2 Gametocytes (Figs. 9-13 and 20-21)

Gametocytes were slender and crescent - shaped, usually curved towards the host cell nucleus, being blunt at one end while the other end appeared as a bent recurved structure. They measured 15 - 20 μm long and 1.5 - 2.5 μm broad. Some of these gametocytes were enclosed in delicate capsules (Fig. 13) while in most other cases no such capsule was discernible. The nucleus was elongate, dense and compact; it was centrally situated, causing the swelling of the parasite at its location (Figs. 10 and 12). It measured 5 - 9 μm long and 1.5 - 3 μm broad. The cytoplasm was finely granulated and contained fine reddish - stained granules scattered throughout the gametocytes (Figs. 9, 11 and 20).

1.3 Effect of the Parasite on the Host Cell

The host cell was affected by the presence of various blood forms; hypertrophy was the most obvious effect. Erythrocytes showed considerable distortion and the nucleus of the host-cell was displaced laterally to the opposite side of the parasite.

2. Schizogony (Plate III)

Schizogony was traced in serial sections of both liver and lungs of heavily infected snakes but only lung sections were positive. Schizonts in different developmental phases were observed in the endothelial cells of blood capillaries as well as in the lumen of the lung capillaries. As the parasite invaded the endothelial cell, a parasitoporous vacuole appeared which enclosed the parasite. Two types of schizonts were observed:

2.1 Macromeroschizonts

The earliest schizont encountered was a uninucleate oval structure (Fig. 22) with one end being narrower than the other; it measured 12.6 μm long and 5.4 μm broad. A round nucleus, surrounded by a clear zone occupied the broad central part of the early schizont; it measured 3 μm in diameter. The nucleus was seen to be distinctly vesicular, with chromatin granules distributed throughout the nucleus and along the nuclear membrane. Nuclear division resulted in an oval four-nucleated schizont (Fig. 23) which measured 25 μm long and 12 μm broad. Octanucleated schizonts (Fig. 24) were later produced with rounded nuclei and vacuolar cytoplasm. These octanucleated schizonts were oval, measuring 21 - 30 μm long and 11.4 - 12.6 μm broad. Successive nuclear divisions led to the production of multinucleate, mostly oval schizonts (Figs. 25 and 27), measuring 27 - 33 μm long and 11.4 - 12.6 μm broad. Mature macromeroschizonts (Figs. 28 and 29) produced a limited number of merozoites which were sausage-shaped, measuring 16.2 - 19.2 μm long and 2.4 - 5.4 μm

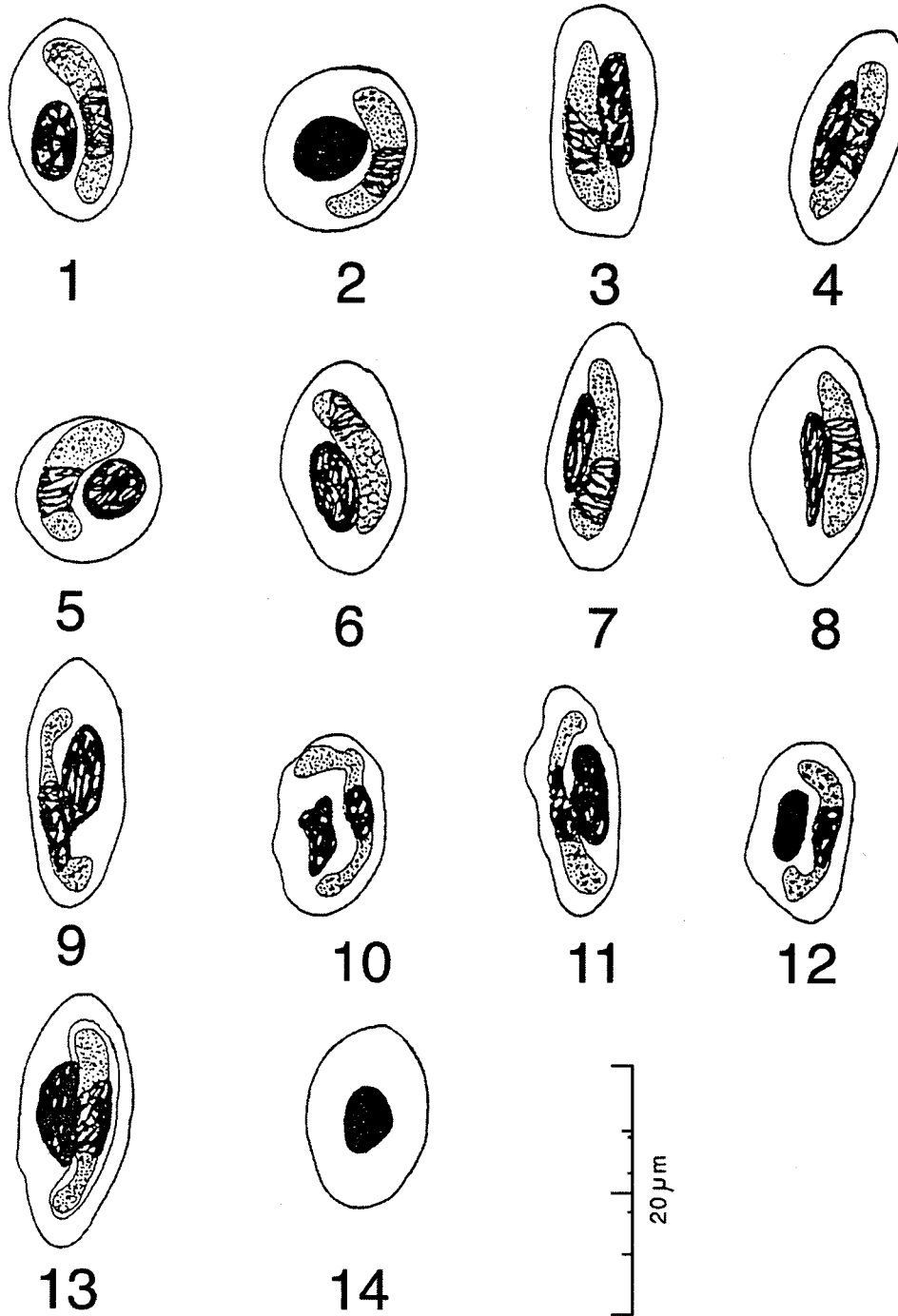


PLATE I

Haemogregarina garnhami

Camera lucida drawings of dry-fixed blood smears, stained with Giemsa's stain.

- Figs. 1-8 : Trophozoites
- Figs. 9-13 : Gametocytes
- Fig. 14 : An uninfected host erythrocyte

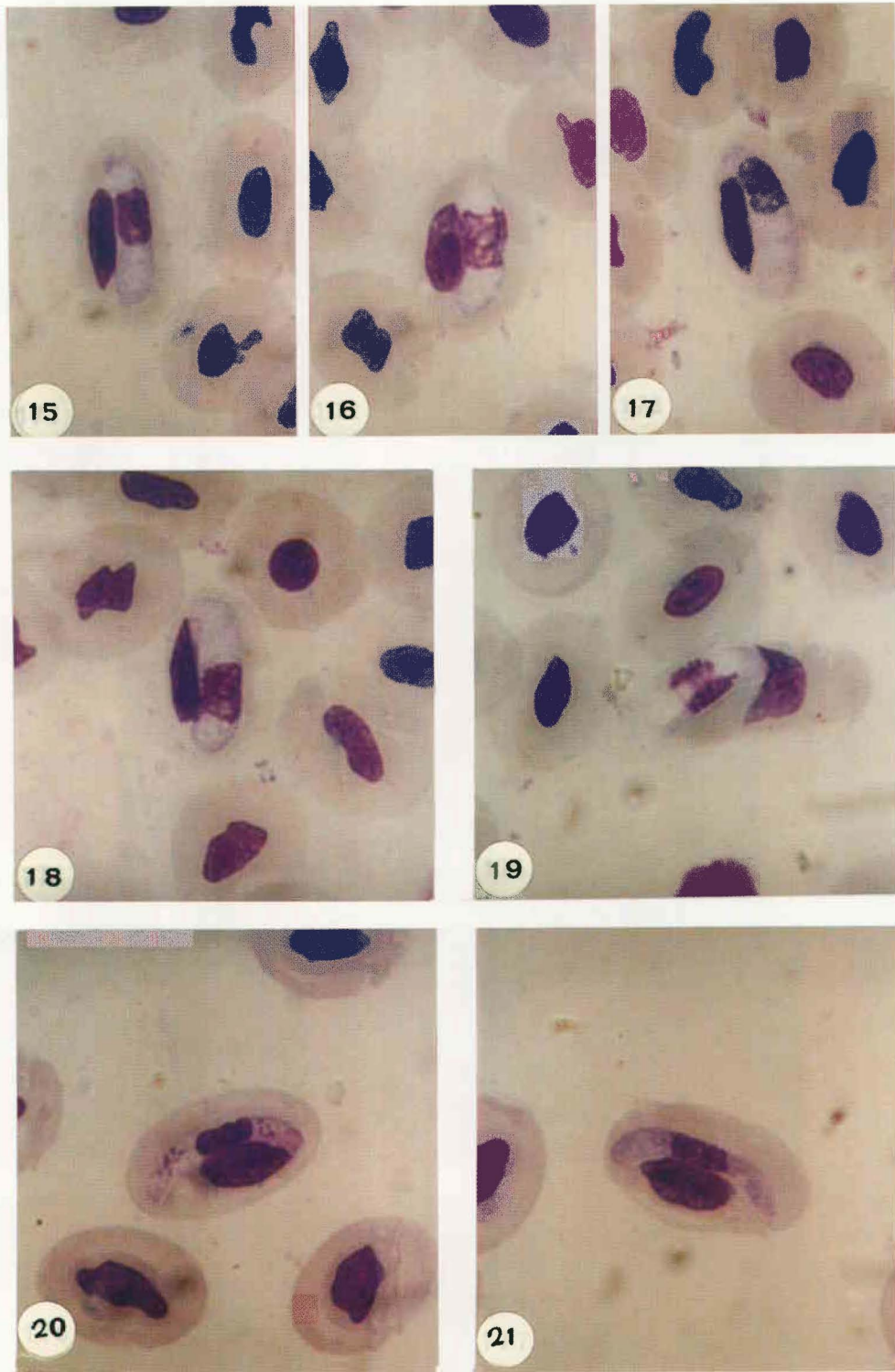


PLATE II

20 μm

Haemogregarina garnhami n.sp

Photomicrographs of permanent preparations of dry-fixed blood smears stained with Giemsa's stain.

Figs. 15-19 : Trophozoites

Figs. 20-21 : Gametocytes

broad. Their cytoplasm was vacuolar and their nuclei were rounded, centrally located and measured 2.4 μm in diameter.

2.2 Micromeroschizonts

They were oval structures (Figs. 30 and 32) measuring 17.4 - 21 μm long and 10.2 - 14.4 μm broad. Mature micromeroschizonts had up to 25 oval nuclei, measuring about 1.8 x 1.3 μm . The resulting micromerozoites were arranged in a comb-like pattern and a residual mass was also observed. These micromerozoites were elongate with two similar rounded ends and elongate nuclei. Micromerozoites (Fig. 33) measured 2.4 - 5.4 μm , long and 1.2 - 4.8 μm broad.

II-HAEMOGREGARINA ASWANENSIS N.SP.

During the present investigation, four snakes identified as *Naja haje haje* were caught from Aswan. One of them was found to be moderately infected with a haemogregarine which is described below.

1. Blood forms (Plates IV and V)

These forms were only encountered in the host's erythrocytes. Two forms were recognized: trophozoites and gametocytes.

1.1 Trophozoites.

1.1.1 Young forms

The earliest young forms (Fig. 34) were ovoid, measuring 7.7 μm long and 5 μm broad with a rectangular nucleus lodged at one end of the parasite; it measured 1.5 μm long and 4.5 μm broad. When stained with Giemsa's, the cytoplasm took a faint blue colouration. Some other young forms (Fig. 35) were spindle-shaped, with one end rounded while the other was pointed. They measured 10 μm long and 5 μm broad. The nucleus was oval, centrally situated and measured 3 μm long and 2 - 3 μm broad.

1.1.2 Growing forms (Trophozoites)

They were oval (Figs. 38 and 42) to sausage-shaped (Fig. 51) forms that measured 10 - 13.5 μm long and 5.5 - 8 μm broad. The nucleus was rounded or rectangular and was usually situated near one of either extremities; it measured 2.5 - 5 μm long and 2.5 - 7 μm broad. It was formed of thin chromatin filaments staining pale pinkish blue with Giemsa's. Sometimes a few red granules could be noted in the cytoplasm.

1.2 Gametocytes

These were slender elongated forms with the nucleus found closer to one end of the parasite. They measured 12.5 - 17.5 μm long and 2.5 - 6 μm broad. The compact reticular nucleus measured 3.7 μm x 2.6 μm broad. The cytoplasm was almost completely clear and homogeneous (Fig. 48), but sometimes vacuolated and contained a variable number of reddish staining granules which showed no particular orientation (Fig. 46).

1.3 Effect of the Parasite on the Host Cell

Infected erythrocytes showed considerable distortion. The presence of the parasite caused extensive changes in the appearance of the host cell. The cytoplasm or what remained of it, lost

almost completely its staining properties and was hardly recognized in blood preparations. Growing trophozoites caused marked changes in the host's corpuscles. They damaged the nucleus and caused dehaemoglobinization of the infected cell (Figs. 40 and 41). Gametocytes also affected the infected erythrocytes, although the damage could be less extensive. Anisocytosis was observed. The location of trophozoites vis-a-vis the nucleus of the infected erythrocytes was frequently noted, pushing the red blood cell nucleus laterally to the periphery (Fig. 45). The nuclei of infected erythrocytes were seen partially superimposing the parasite (Figs. 37, 40 and 47), splitting of the host cell nucleus was also observed (Figs. 37 and 48); where the nucleus could be divided up to 3 fragments.

2. Schizogony (Plate VI)

Schizogony was studied in sections of the liver and lungs, but those of the latter had more schizogonic stages.

2.1 Macromeroschizonts

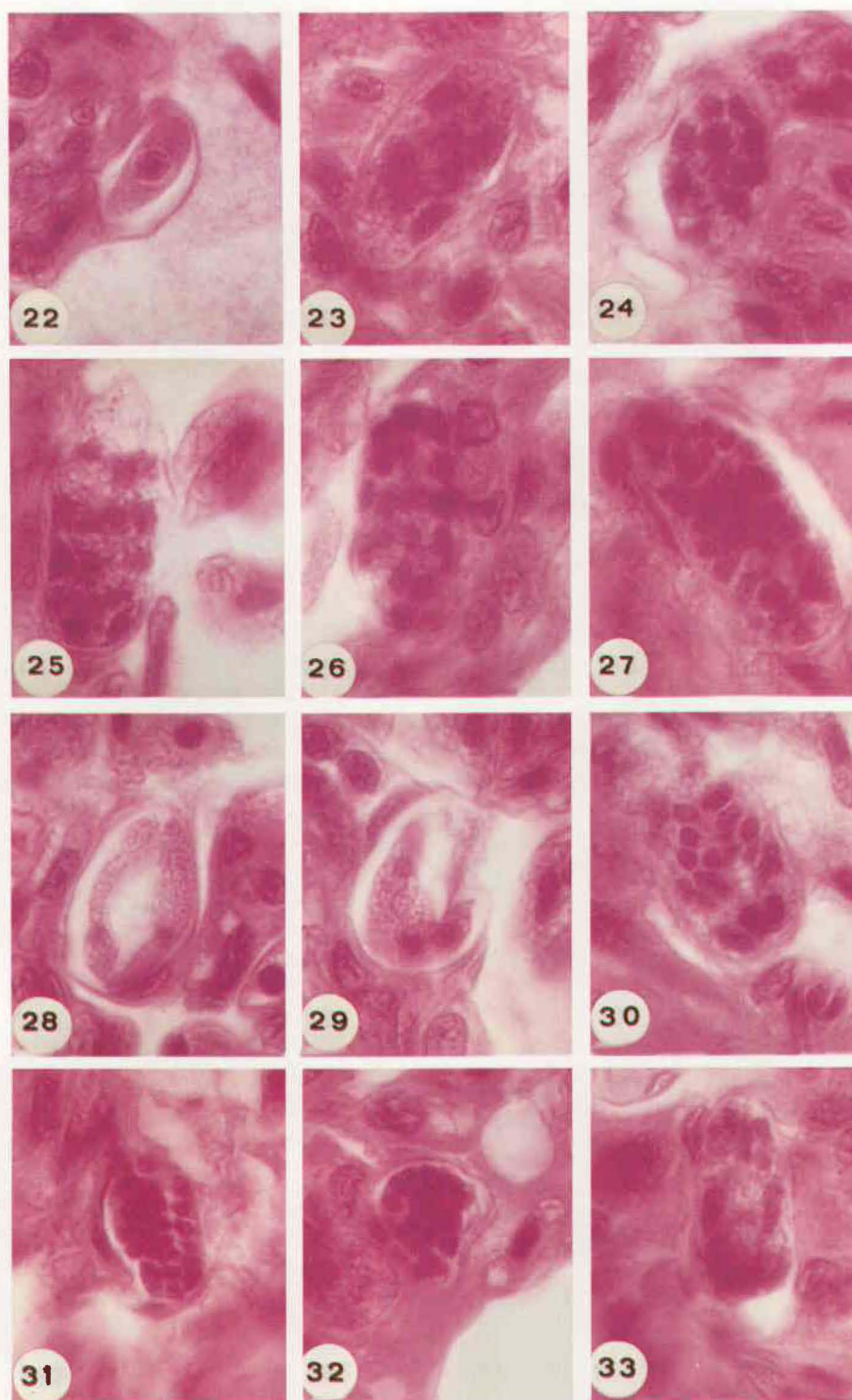
The earliest schizont observed was an oval uninucleate form (Fig. 57) measuring 7.2 μm long and 5.4 μm broad with a spherical nucleus measuring 2.4 μm in diameter and a granular cytoplasm. These schizonts were followed by oval binucleated ones (Fig. 58) which measured 8.8 μm long and 6 μm broad. They grew to quadrinucleate schizonts (Fig. 59) measuring 11.7 μm long and 7 μm broad, then to eight nucleated ones (Fig. 60) measuring 15.2 μm long and 10 μm broad. The multinucleate schizonts were either rounded (Fig. 61), measuring 25.2 μm in diameter or ovoid (Fig. 62), measuring 20.4 - 32.4 μm long and 14.4 - 24 μm broad and contained a maximum of 20 nuclei. Macromerozoites were sausage-shaped with similar rounded ends and had centrally situated nuclei. They measured 16.2 μm long and 5.4 μm broad (Fig. 63).

2.2 Micromeroschizonts

These were either rounded (Fig. 64), measuring 16.2 - 24 μm in diameter or ovoid (Fig. 65 and 67), measuring 27 - 30 μm long and 16.8 - 18 μm broad. They contained a maximum of 22 nuclei. Mature micromeroschizonts had about 22 merozoites and a residual cytoplasm. Micromerozoites (Figs. 67-69) were small and elongate with one broad rounded end while the other was much narrower. They measured 5.4 - 7.2 μm long and 1.8 - 2.4 μm broad. Each had a centrally situated oval nucleus, measuring 3 μm long and 2.1 μm broad and a granular cytoplasm. Micromeroschizonts were surrounded by a parasitophorous vacuole.

DISCUSSION

Haemogregarines are heteroxenous apicomplexans in which gamonts infect red blood cells of reptiles and other vertebrates, merogony takes in certain internal organs of the vertebrate host while sporogony occurs in invertebrate hosts [22]. These blood parasites are included in the family *Haemogregarinidae* which contains the genera: *Haemogregarina*, *Hepatozoon*, *Karyolysus* and *Cyrtilia* [23]. Relating species of haemogregarines to one of these genera always poses certain practical problems [21]. Al-



20 μ m

PLATE III

Haemogregarina garnhami n.sp

Photomicrographs of permanent preparations of thin lung sections stained with Haemtoxylin and eosin.

Fig. 22 : Uninucleate schizont
Fig. 23 : Four-nucleated schizont
Fig. 24 : Octanucleated schizonts

Fig. 25-27 : Mature macromeroschizonts
Figs. 28-29 : Macromerozoites
Figs. 30-32 : Micromeroschizonts
Fig. 33 : Micromerozoites

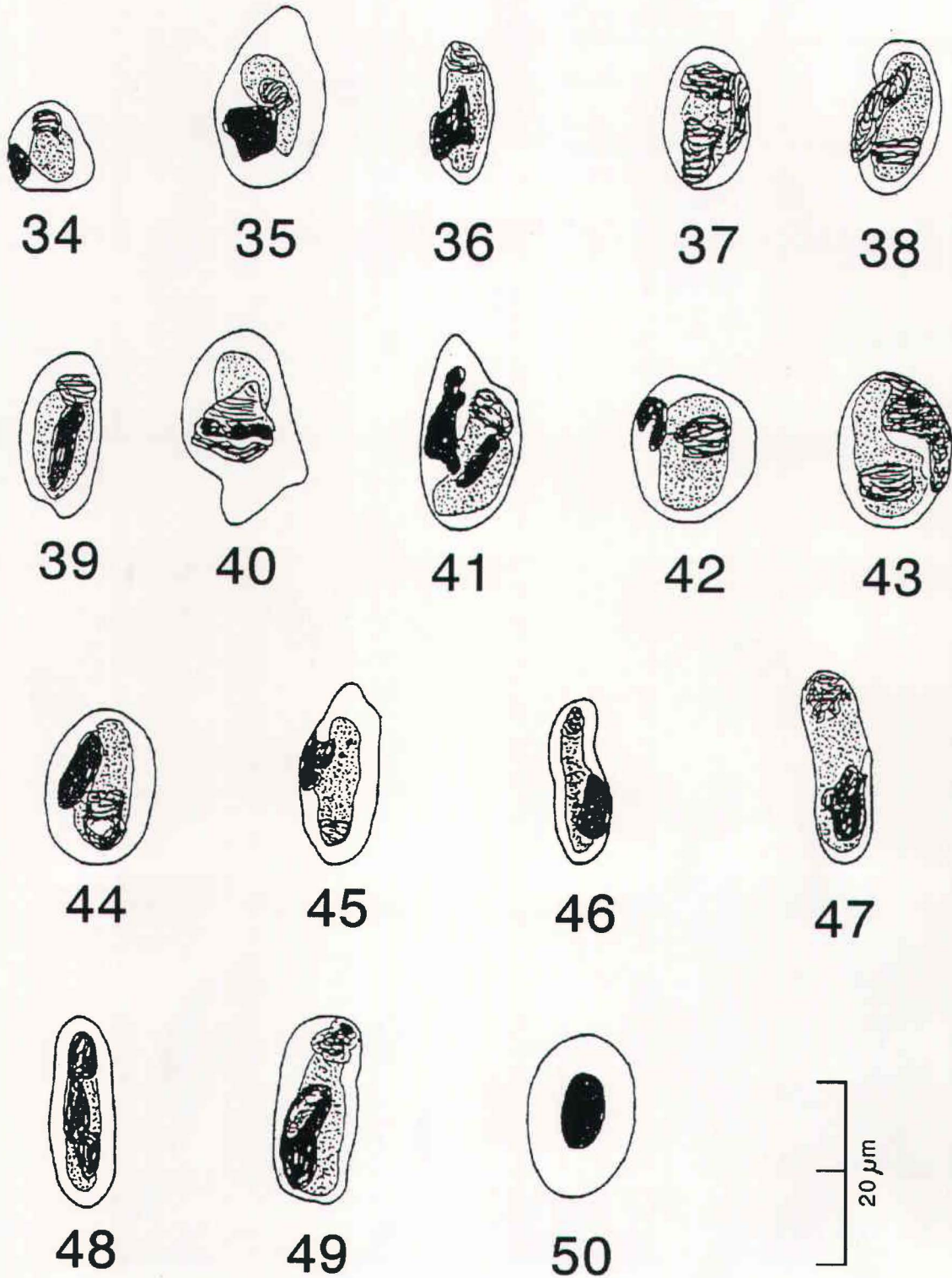


PLATE IV

Haemogregarina aswanensis

Camera lucida drawings of dry-fixed blood films stained with Giemsa's stain.

Figs. 34-36 : Young stages

Figs. 37-45 : Trophozoites

Figs. 46-49 : Gametocytes

Fig. 50 : An uninfected blood corpuscles

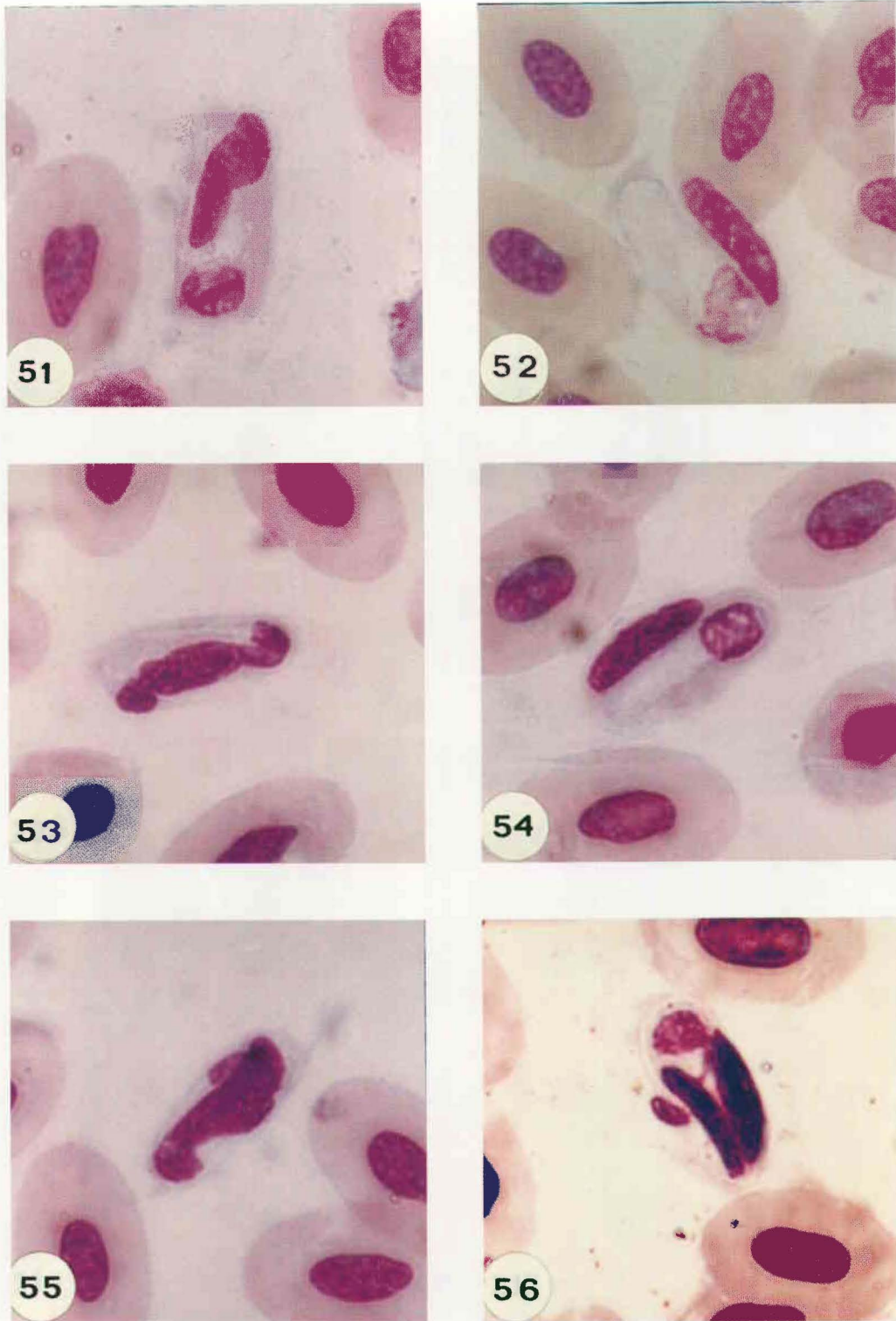


PLATE V

Haemogregarina aswanensis

Photomicrographs of permanent of dry fixed blood films stained with Giemsa's stain.

Figs. 51-53 : Young stages

Figs. 54-55 : Trophozoites

Fig. 56 : Parasite causing the splitting of host-cell nucleus

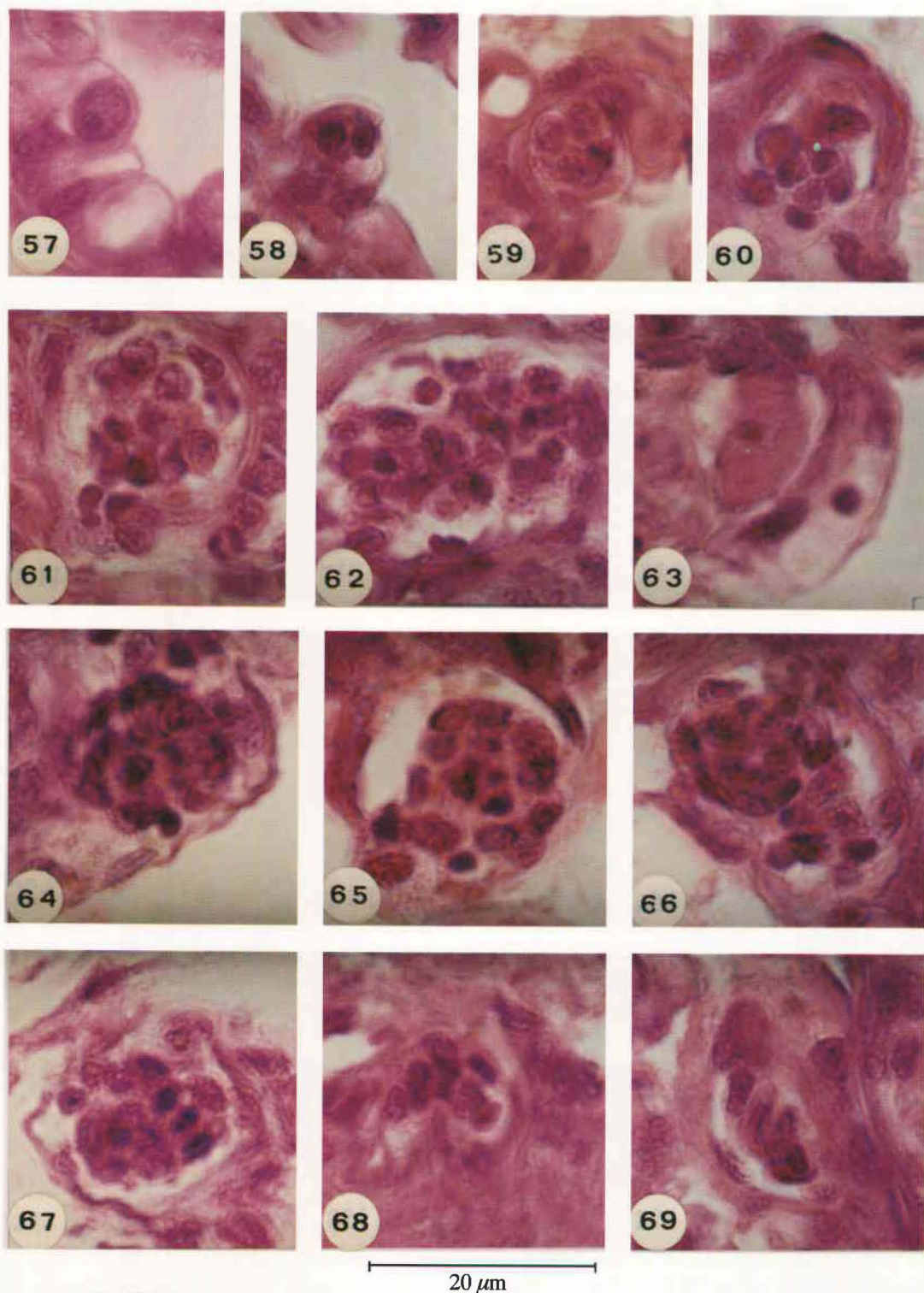


PLATE VI

Haemogregarina aswanensis

Photomicrographs of permanent preparation taken from thin sections of the lung stained with haematoxylin and eosin.

- | | | | |
|---------|---------------------------|-------------|---------------------|
| Fig. 57 | : Uninucleate schizont | Figs. 61-62 | : Macromeroschizont |
| Fig. 58 | : Binucleate schizont | Fig. 63 | : Macromerozoites |
| Fig. 59 | : Quadrinucleate schizont | Figs. 64-66 | : Micromeroschizont |
| Fig. 60 | : Octanucleated schizont | Figs. 67-69 | : Micromerozoites |

though different criteria have been suggested, these genera are best differentiated by the characteristics of their sporogony [21,22]. However, the invertebrate vectors and details of sporogony are not known for the majority of haemogregarine species and accordingly their designation to any of the four genera of the family Haemogregarinidae becomes difficult. Mohammed and Mansour [22] suggested that such blood parasites would be assigned to the genus *Haemogregarina* in its broad sense, *sensu lato*. The same approach was used by Levine [23] who stated: "As a practical matter, unless they are piroplasmids, malaria parasites or related forms, most blood cell parasites of vertebrates are almost automatically called *Haemogregarina*. Later research may warrant shifts in the genus, but until such studies are carried out, the custom is warranted". Recently, the same view was adopted [21,24,25], and accordingly followed in the present work where the observed parasites are included in the genus *Haemogregarina* (*sensu lato*). Future research on the invertebrate vectors and details of sporogony may warrant shifts in the genus [23].

Eight species of haemogregarines have been reported from snakes in Egypt. A comparison of these species with the two species described during the present work is presented in Table (1).

Hg. garnhami n.sp. is described from *Psammophis schokari aegyptius*. Ramadan [13] in her thesis described another species *Hg. matruhensis** from another subspecies of these snakes. Both trophozoites and gametocytes of *Hg. matruhensis* are distinctively larger than the corresponding stages in *Hg. garnhami*. Another important difference is observed in the number of merozoites produced in the micromeroschizont of both species, they are 38 and 25 respectively.

Three more species of haemogregarines were recorded from colubrid snakes in Egypt. These include *Hg. arabi* [13], *Hg. malpoloni* [13] and *Hepatozoon aegypti* [14, 15]. *Hg. malpoloni* differs from *Hg. garnhami* in the size of trophozoites, in addition to the type of schizonts and the number of the produced merozoites. Whereas macro- and micromeroschizonts are known in *Hg. garnhami*, only one type of schizonts is known in *Hg. malpoloni*. Similarly, the presence of much thinner gametocytes, and much smaller micromerozoites clearly distinguish *Hg. garnhami* from *Hg. arabi*. The smaller size of both trophozoites, gametocytes macro- and micromeroschizonts in *Hepatozoon aegypti* also separates it from *Hg. garnhami*.

In the present work *Hg. aswanensis* is described from *Naja haje haje*. Bashtar and Abdel Ghaffar [17] described *Hg. najae* from *Naja nigricollis nigricollis* from Egypt. Trophozoites have not been described in *Hg. najae* but gametocytes of that species are within the same range like those of *Hg. aswanensis*, measuring, 17.5 x 5.4 µm and 12.5-17.5 x 2.5-6 µm respectively. Whereas macro- and micromeroschizonts in *Hg. najae* produce 42 and 12 merozoites respectively, the corresponding numbers are 20 and

up to 22 in *Hg. aswanensis*. Lastly, in *Hg. najae* one type of merozoites, measuring 12 x 2.5 µm, is produced by macro- and micromeroschizonts but in *H. aswanensis* two types of merozoites, measuring 16.2 x 5.4 µm and 5.4 - 7.2 µm x 1.8 - 2.4 µm respectively, are known.

In Egypt, snakes of the family Viperidae are reported to be infected with three species of haemogregarines: *Hg. sp.* in *Cerastes vipera* [16], *Hepatozoon mehlhorni* [20] and *Hepatozoon seurati* [18,19]. *Hg. aswanensis* differs from *Hg. sp.* described by Abdel Ghaffar [16] in having broader trophozoites, smaller and broader gametocytes, a smaller number of merozoites in the macromeroschizont and 2 types of merozoites measuring 16.2 x 5.4 µm and 5.4 - 7.2 µm x 1.8 - 2.4 µm compared with one type of merozoites measuring 10 x 2 - 2.5 µm in the latter species. Similarly, *Hg. aswanensis* differs from *Hepatozoon mehlhorni* mainly in having smaller gametocytes and micromerozoites. Lastly, *Hepatozoon mehlhorni* differs from *Hg. aswanensis* in having a smaller number of macromerozoites in the macromeroschizont and a higher number of micromerozoites in the micromeroschizonts.

H. garnhami is distinguished from *Hg.* described by Abdel Ghaffar [16] in having much less macromerozoites as well as two types of merozoites of different sizes compared with only one type of merozoites in the latter species.

The blood forms of both *Hg. garnhami* and *Hg. aswanensis* are smaller than those of *Hg. zamensis* Laveran, 1902 reported from *Zamenis hippocrepus* in Tunisia, which measure 2.5 - 2.6 x 4 µm and 18 m for trophozoites and gametocytes respectively. Similarly, blood forms of *Hg. aswanensis* are smaller than those of *Hg. musotae* Hoare, 1932 where trophozoites and gametocytes measure 15.12 x 6.6 µm and 17 x 3.3 - 6.6 µm respectively. Whereas no alterations occur in erythrocytes infected with *Hg. musotae*, marked alterations occur in the size, contour and position and shape of the nucleus in erythrocytes infected with either *Hg. garnhami* or *Hg. aswanensis*.

In conclusion, the present writers believe that all the above differences are sufficient to accept *Haemogregarina garnhami* and *Haemogregarina aswanensis* as new species. *Hg. garnhami* is named in the honour of the eminent protozoologist, the late Professor P.C.C. Garnham, formerly Emeritus Professor of Protozoology, University of London.

SPECIFIC DIAGNOSIS OF *HG. GARNHAMI* N.SP.

Both trophozoites and gametocytes infect only red blood corpuscles. Trophozoites sausage-shaped, lie parallel to longitudinal axes of the erythrocytes and measure 10 - 20 x 2 - 5 µm. The nucleus of the trophozoite is mostly central but may lie slightly towards one of the two ends and measures 2.5 - 7.5 µm, while the cytoplasm is granular. The gametocytes are slender and crescent-shaped, blunt at one end while the other end is bent; measuring 15 - 20 µm x 1.5 - 2.5 µm and their cytoplasm is granular. Hypertrophy of infected erythrocytes associated with distortion occur, with the nucleus of the host cell being displaced.

* A new combination *Hepatozoon matruhensis* (Ramadan, 1974) Bashtar *et al.* 1994 [26] was established later

Table 1
A comparison between haemogregarines of snakes in Egypt

Species	Hosts	Measurements μm		Location	Schizonts				Merozoites (μm)		References
		Trophozoites	Gametocytes		Macromeroschizonts		Micromeroschizonts		Macro-	Micro-	
					Measurements (μm)	No. Merozoites	Measurements (μm)	No. Merozoites			
<i>Haemogregarina arabi</i>	<i>Telescopus dhara</i>	14-18 x 5.5-6.5	11-18 x 3-5.5	Lungs & Liver	17-22 diam. 20-32 x 14-20	16	30-32 x 20-23	28	15-17x 3-3.5	10 x 3	Ramadan (1974)
<i>Haemogregarina matruhensis</i>	<i>Psammophis schokari</i>	20-24 x 9-14	18-28 x 2.5-6	Lungs & Liver	18-21 diam. 21-26 x 16-20	12-16	20-28 x 12.14	38	16-18 x 3-3.2	8 x 2	Ramadan (1974)
<i>Haemogregarina malpoloni</i>	<i>Malpolon monspessulanus</i>	17-22 x 8-9	12-25 x 3-5.5	Lungs	One type: 28 x 13	36	-	-	One type: 4 x 1.5		Ramadan (1974)
<i>Hepatozoon aegypti</i>	<i>Spalerosophis diadema</i>	8-10 x 2-3.5	13-16x 2.5 -3	Lungs	27 x 21	15-40	17 x 6.5	15-40	One type: 9 x 2		Bashtar <i>et al.</i> (1984)
<i>Haemogregarina sp.</i>	<i>Cerastes vipera</i>	10-12 x 3-4	16-19 x 3.5-4	Lungs, Liver & Spleen	30 x 23	25-45	19 x 8	8-17	One type: 10 x 2-2.5		Abdel Ghaffar (1985)
<i>Hg. najae</i>	<i>Naja nigricollis</i>	-	17.5 x 5.4	Lungs & Liver	35 x 20	42	20 x 9	12	One type: 12 x 2.5		Bahstar and Abdel Ghaffar (1987)
<i>Hepatozoon mehlhorni</i>	<i>Echis carinatus</i>	14.5 x 4.0	17.5 x 5.4	Lungs, Liver & Spleen	30.2 x 22.6	16-40 (28)	18.2 x 13.5	2-14 (8)	17.2 x 5.0	15.1 x 602	Bashtar <i>et al.</i> (1991)
<i>Hepatozoon seurati</i>	<i>Cerastes cerastes</i>	10 x 3	16.5 x 3.5	Lungs, Liver & Spleen	27.6 x 17.5	20-35 (26)	16.2 x 11.5	3-16 (10)	16.5 x 3.5	12.8 x 5.1	Abdel Ghaffar <i>et al.</i> (1991b)
<i>Hg. garnhami</i>	<i>Psammophis schokari aegyptius</i>	10-20 x 2-5	15-20 x 1.5-2.5	Lungs	27-33 x 11.4-12.6	Limited	17.4-21 x 10.2-14.4	25	16.2-19.2 x 2.4-5.4	2.4-5.5 x 1.2-4.8	Present work
<i>Hg. aswanensis</i>	<i>Naja haje</i>	10-13.5 x 5.5 -8	12.5 - 17.5 x 2.5-6	Lungs & Liver	20.4-32.4 x 14.4-24 or 25.2 diam.	20	16.2-24.0 diam. or 27-30 x 16.8-18	22	16.2 x 5.4	5.4-7.2x 1.8-2.4	Present Work

Schizogony occur in the endothelial lining or the lumen of the blood vessels of lungs, where parasitophorous vacuoles enclose the parasite stages. Two types of schizonts are known: macro- and micro-meroschizonts. The macromeroschizonts measure 27 - 33 x 11.4 - 12.6 μm ; they produce a limited number of merozoites which are sausage-shaped and measure 16.2 - 19.2 x 2.4 - 5.4 μm . The micromeroschizonts measure 17.4 - 21.0 μm x 10.2 - 14.4 μm ; they produce up to 25 merozoites that measure 2.4 - 5.4 x 1.2 - 4.8 μm .

Host : *Psammophis schokari aegyptius*.

Locality : El Bouaty Oasis, Faiyum and Aswan, Egypt.

Syntypes : Deposited in the Protozoological Collection, Department of Zoology, University of Ain Shams, Cairo, Egypt.

SPECIFIC DIAGNOSIS OF *HAEMOGREGARINA ASWANENSIS* N.SP.

Both trophozoites and gametocytes infect only red blood corpuscles. Trophozoites are oval to sausage-shaped, measuring 10.0 - 12.5 x 5.5 - 8 μm . The nucleus is situated nearer to one of the extremities, measures 2.5 - 5.0 x 2.5 - 7 μm and the cytoplasm is granular. Gametocytes are slender elongate forms, measuring 12.5 - 17.5 μm x 2.5 - 6.0 μm , the nucleus lies closer to either ends of the parasite, measuring 3.7 x 2.6 μm and the cytoplasm is granulated. Infected erythrocytes show considerable distortion, become dehemoglobinized with fragmentation of the host's cell nucleus, occasionally observed. Two types of schizonts are observed in the lungs and liver, although they are more common in the former than the latter. The macromeroschizonts may be either rounded, measuring 25.2 μm in diameter or oval measuring 20.4 - 32.4 μm 14.4 - 24 μm . They contain a maximum of 20 nuclei, developing later into macromerozoites measuring 16.2 x 5.4 μm . Micromeroschizonts are either rounded, measuring 16.2-24.0 μm in diameter or oval, measuring 27.0 - 30 x 16.8 - 18 μm and containing a maximum of 22 nuclei or merozoites that measure 5.4 - 7.2 x 1.8 - 2.4 μm . A parasitophorous vacuole surrounds each micromeroschizont.

Host : *Naja haje haje*

Locality : Aswan, Egypt.

Syntypes : Deposited in the Protozoological Collection, Department of Zoology, University of Ain Shams, Cairo, Egypt.

ACKNOWLEDGEMENT

The authors are deeply grateful for Professor A.H. Helmy Mohammed, Emeritus Professor of Protozoology, Faculty of Science, University of Ain Shams who kindly made valuable comments on the draft manuscript.

REFERENCES

[1] Laveran, A., 1902. Sur quelques hemogregarines des ophidiens. C.R. Acad. Sci., 135: 1036-1040.

- [2] Billet, 1904. Sur une hemogregarine karyolysate de la couleuvre viperine. C.R. Soc. Biol., 65: 4840485.
- [3] Sergent, E.T., 1918. Une hemogregarine de *Vipera ibetina* L. d'Algerie. Debut de l'evolution de cette hemogregarine chez un carien. Bull. Soc. Path., 11: 278-281.
- [4] Sambon, L.W. and C. G. Seligmann, 1908. The hemogregarines of snakes. J. Trop. Med. Hyg., 11: 955-358 and 375-377.
- [5] Sambon, L.W. and Seligmann, 1909. The hemogregarines of snakes. J. Trop. Med. Hyg., 12: 22-24, 38-41, 48-55 and 70-75.
- [6] Wenyon, C.M. 1908. Report of traveling pathologist and zoologist. 3rd. Rep. Wellcome Res., Labs. Khartoum, 121-168.
- [7] Hoare, C.A., 1932. On protozoal blood parasites collected in Uganda; with an account of the life cycle of the crocodile hemogregarine. Parasitology, 24: 210-224.
- [8] Garnham, P.C.C., 1950. Blood parasites of the East African vertebrates, with a brief description of exoerythrocytic schizogony in *Plasmodium pitmani*. Parasitology, 40: 328-337.
- [9] Ball, G.H., Y. Chao, and S.R. Jr. Telford, 1967. The life history of *Hepatozoon rarefaciens* (Sambon and Seligmann, 1907), and its experimental transfer to *Constrictor constrictor* (Boidae) J. Parasit., 53: 897-909.
- [10] Landau, Michel, J.C. and A.G. Chabaud, 1972. Cycle biologic d'*Hepatozoon domerguei*, discussion sur les caracteres fondamentaux d'un cycle de coccidie. Z. Parasitenkd., 38: 250-270.
- [11] Pierce, M.A., 1984. Some parasites of reptiles from Zambia and Indian Ocean Islands with a description of *Haemogregarina gambiensis* sp. nov. from *Dispholidus typus* (Colubridae). J. Nat. Hist., 18: 211-217.
- [12] Mohammed, A.H.H. and S.N. Mansour, 1960. A general survey of blood protozoan in some Egyptian amphibians and reptiles. Bull. Zool. Soc. Egypt., 14: (1959): 21-26.
- [13] Ramadan, N.F., 1974. Morphological, experimental and systematic studies on protozoan blood parasites of Egyptian reptiles of Egyptian reptiles. Ph.D. thesis Ain Shams University, Cairo, Egypt.
- [14] Bashtar, A.R., R. Boulos, and H. Mehlhorn, 1984a. *Hepatozoon aegypti* nov. sp. L-Life cycle. Z. Parasitenkd., 70: 29-41.
- [15] Bashtar, A.R., F.A. Ghaffar and H. Mehlhorn, 1984b. *Hepatozoon aegypti* nov. sp. 2-Electron microscope studies on the erythrocytic stages and schizogony inside the snake *Spalerosophis diadema*. Z. Parasitenkd., 70: 43-52.

- [16] **Abdel-Ghaffar, F.A., 1985.** Light and electron microscope studies on a haemogregarine species infecting the viper *Cerastes vipera* in Egypt. Proc. Zool. Soc. A.R. Egypt., **9**: 209-220.
- [17] **Bashtar, A.R., and F.A. Ghaffar, 1987.** Light microscope study on the life cycle of *Haemogregarina najae* infecting the snake *Naja nigricollis nigricollis* (Elapidae, Proteroglypha, Squamata) from Egypt. Proc. Zool. Soc. A.R. Egypt., **14**: 33-44.
- [18] **Abdel-Ghaffar, F.A., A.R. Bashtar, and M.A. Shazly, 1991a.** Life cycle of *Hepatozoon seurati* comb. nov. 1-Gamogony and sporogony inside the vector, *Culex pipiens molestus*. J. Egypt. Ger. Soc. Zool., **3**: 211-226.
- [19] **Abdel-Ghaffar, F.A., A.R. Bashtar, and M.A. Shazly, 1991b.** Life cycle of *Hepatozoon seurati* comb. nov. Erythrocytic stage and merogony inside the viper *Cerastes cerastes*. J. Egypt. Ger. Soc. Zool., **3**: 227-240.
- [20] **Bashtar, A.R., F.A. Ghaffar, and M.A. Shazly, 1991.** Life cycle of *Hepatozoon mehlhorni* sp. nov. in the viper *Echis carinatus* and the mosquito *Culex pipiens*. Parasit. Res., **17**: 402-410.
- [21] **Saoud, M.F.A., N.F. Ramadan, S.H. Mohammed and S.M. Fawzi, 1995.** Haemogregarines of geckos in Egypt, together with a description of *Haemogregarina helmymohammedi* n.sp. Qatar Univ. Sci. J., **15**: 131-146.
- [22] **Mohammed, A.H.H. and N.S. Mansour 1960.** The haemogregarine complex (An analytical systematic review). Bull. Fac. Sci. Cairo Univ., **35**: 39-51.
- [23] **Levine, N.D., 1982.** Some corrections in the haemogregarine (Apicomplexa: Protozoa) nomenclature. J. Protozool., **29**: 601-603.
- [24] **El Wasila, M., 1989.** *Haemogregarina* sp. (Apicomplexa: Adeolorina) from the gecko *Tarentola annularis* in the Sudan: fine structure and life cycle trials. Parasitology Res., **75**: 444-448.
- [25] **Ramadan, N.F., M.F.A. Saoud, S.H. Mohammed and S.M. Fawzi, 1996.** *Haemogregarina damiettae* sp.n., a blood parasite of the lacertid *Acanthodactylus boskianus* in Egypt. Acta Parasitologica, **41**: 76-80.
- [26] **Bashtar, A.; M. A. Shazly; A. K. Ahmed and H. M. Fayed, 1994.** Life cycle of *Hepatozom matruhensis* Camb. Nov. 1. Blood stages and merogony inside the snake *Psammophis schokari*. J. Egypt. Ger. Soc. Zool., **14(D)**: 117-13.

Received 10 June, 1996