

## Case report

# Bilateral adnexal masses: A case report of acute myeloid leukemia presenting with myeloid sarcoma of the ovary and review of literature

Jenci Hawthorne<sup>a,\*</sup>, Hajrunisa Cubro<sup>a</sup>, Elizabeth Farabee<sup>a</sup>, Samer Z. Al-Quran<sup>b</sup>, Mustafa Al-Kawaaz<sup>b</sup>, Semir Vranic<sup>c</sup>, Whitney Goldsberry<sup>a</sup>, Daniel Metzinger<sup>a</sup>, Sarah Todd<sup>a</sup>

<sup>a</sup> Department of Gynecology Oncology, University of Louisville, Department of Obstetrics, Gynecology, and Women's Health, 550 South Jackson Street, Ambulatory Care Building, Second Floor, Louisville, KY 40202, United States

<sup>b</sup> University of Louisville, Department of Pathology, Abell Administration Building, 323 East Chestnut Street, Louisville, KY 40202, United States

<sup>c</sup> College of Medicine, QU Health, Qatar University, 2713 Doha, Qatar



## ARTICLE INFO

## Keywords:

Acute myeloid leukemia  
Ovarian  
Myeloid  
Granulocytic sarcoma  
Extramedullary myeloid tumor  
Chloroma

## 1. Introduction

Here, we report a case of myeloid sarcoma (extramedullary myeloid tumor) of the left ovary in a female with known acute myeloid leukemia (AML), who was discovered to have bilateral adnexal masses during treatment planning and subsequently underwent a total robotic hysterectomy with bilateral salpingo-oophorectomy. Myeloid sarcoma (MS) has been reported in 2–8% of patients with AML and can involve any extramedullary site. MS is most commonly diagnosed simultaneously with AML (Avni and Koren-Michowitz, 2011); however, it can precede or occur after the diagnosis of AML, and may be the sign of transformed/blast crisis of myelodysplastic and/or myeloproliferative neoplasm. In 2008, the World Health Organization (WHO) classified MS as “a tumor mass consisting of myeloid blasts with or without maturation occurring at an anatomic site other than the bone marrow” with an update in 2017 of “myeloid sarcoma” as the terminology used for extramedullary myeloid tumors (Pileri et al.). MS is more common in tumors with monocytic differentiation. There is no consensus on the treatment of MS thus the mainstay of treatment of MS is AML-type chemotherapeutics. The pathogenesis of female reproductive organ involvement with MS is not fully understood; the most common site for myeloid sarcoma is

the skin, subcutaneous tissues, and lymph nodes (Hernández et al., 2002; Wilson and Medeiros, 2015). Neural cell adhesion molecule (NCAM; CD56), which is present in normal ovarian, testicular, and gastrointestinal tissue, is suspected to play a role in the migration of MS to these tissues (Byrd and Weiss, 1994). Additionally, reproductive organs have barriers, which are thought to be sanctuary sites for leukemic cells to proliferate despite systemic therapy such as chemotherapy (Bakst et al., 2011).

## 2. Case report

The patient was a 54-year-old (gravida 2, Para 2002) post-menopausal female with a medical history of thyroid cancer (diagnosed in 2009 and for which she underwent thyroidectomy), hypertension, hyperlipidemia, reflux disease, obstructive sleep apnea, and 27-pack-year tobacco use. She was diagnosed with AML with myelodysplasia related changes (AML-MRC) via bone marrow biopsy during the workup of one month of progressive fatigue and easy bruising. Cytogenetic analysis demonstrated a complex karyotype including 7 metaphase with del(3)(q21), 11 metaphase with del(3)(q21) and additional +X, +3, l(8)(q10), and only 2 normal metaphase. Molecular profiling was positive

\* Corresponding author.

E-mail addresses: [jenci.hawthorne@louisville.edu](mailto:jenci.hawthorne@louisville.edu) (J. Hawthorne), [hajrunisa.cubro@louisville.edu](mailto:hajrunisa.cubro@louisville.edu) (H. Cubro), [elizabeth.farabee@louisville.edu](mailto:elizabeth.farabee@louisville.edu) (E. Farabee), [samer.al-quran@louisville.edu](mailto:samer.al-quran@louisville.edu) (S.Z. Al-Quran), [mustafa.al-kawaaz@louisville.edu](mailto:mustafa.al-kawaaz@louisville.edu) (M. Al-Kawaaz), [svranic@anubih.ba](mailto:svranic@anubih.ba) (S. Vranic), [whitney.goldsberry@louisville.edu](mailto:whitney.goldsberry@louisville.edu) (W. Goldsberry), [daniel.metzinger@uoflhealth.org](mailto:daniel.metzinger@uoflhealth.org) (D. Metzinger), [sarah.todd@UofLHealth.org](mailto:sarah.todd@UofLHealth.org) (S. Todd).

<https://doi.org/10.1016/j.gore.2023.101202>

Received 5 March 2023; Received in revised form 4 May 2023; Accepted 13 May 2023

Available online 18 May 2023

2352-5789/© 2023 The Authors. Published by Elsevier Inc. This is an open access article under the CC BY-NC-ND license (<http://creativecommons.org/licenses/by-nc-nd/4.0/>).

for mutations in NPM-1, FBXW7 and WT1, and low allelic ratio FLT-3 ITD mutation (0.15). During her treatment planning for AML, she was noted to have bilateral pelvic masses on imaging. CT demonstrated a  $16.6 \times 15.0 \times 11.1$  cm right adnexal mass and a  $13.2 \times 10.9 \times 11.7$  cm left adnexal mass, both highly suspicious for cancer, with additional radiologic findings showing peritoneal nodules (measuring up to 2.3 cm in the left upper quadrant) suspicious for peritoneal carcinomatosis, and retroperitoneal and mesenteric lymphadenopathy (see Fig. 1). Mild right hydronephrosis was also noted. Subsequent transvaginal ultrasound demonstrated the bilateral masses to be solid and vascularized. The uterus was not well-visualized. The patient was initiated on high-dose cytarabine induction therapy with 7 + 3 induction therapy as well as midostaurin.

Given concern for a possible second primary malignancy of ovarian origin, the patient was referred to gynecologic oncology for consideration of surgical intervention; however, due to ongoing systemic treatment and resultant myelosuppression, surgical management was initially deferred. A CT urogram was performed one month into treatment. This showed interval resolution of the mild right-sided hydronephrosis as well as interval decrease in size of the right adnexal mass to 13.2 cm and left mass to 9 cm. The patient underwent an ultrasound-guided fine needle biopsy of the right adnexal mass with pathology consistent with fibroadipose tissue and no evidence of malignancy. Of note, this sampling was noted to be limited in interpretation by low cellularity and may not have been representative of the actual adnexal mass. She completed induction therapy with a follow-up bone marrow biopsy negative for malignancy.

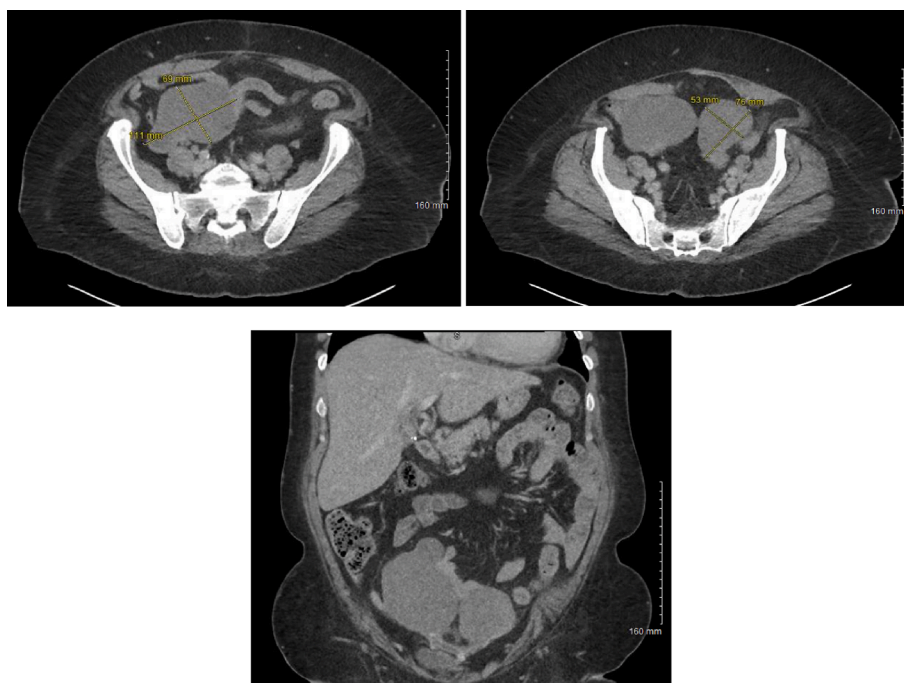
Approximately four months following AML diagnosis, the patient successfully underwent surgical management of the pelvic masses via total robotic hysterectomy, bilateral salpingo-oophorectomy, and extensive enterolysis. Hysterectomy was performed following patient discussion and preference. Surgical findings revealed enlarged ovaries bilaterally with a solid appearance, and no obvious cysts appreciated. The uterus was small and normal appearing, along with the bilateral fallopian tubes. Mesh from a prior ventral hernia repair was noted to be affiliated with numerous intraabdominal adhesions, including

involvement of the left ovarian mass, which was densely adherent to the mesh. Several peritoneal inclusions cysts were also incorporated into this adhesive disease. A gross pathologic evaluation of the specimen revealed the left ovary to be adherent to the uterine body, measuring  $10.0 \times 6.5 \times 4.5$  cm, weighing 112 g, and containing anterior serosal adhesions. The cervix was smooth and pink, measuring  $2.5 \times 2.2$  cm with a 0.8 cm slit-shaped os and a distinct squamocolumnar junction without lesions in the cervix or endocervix. No left or right fallopian tubes were visualized. The right ovary measured  $8.5 \times 6.5 \times 6.0$  cm and was solid, gray-white to tan, and necrotic in appearance. The final histopathologic examination confirmed the presence of myeloid sarcoma in the left ovary with extensive necrosis and fibrosis (Fig. 2A-B) and extensive fibrosis and necrosis in the right ovary (not shown). The endometrium was atrophic, and the myometrium was noted to have leiomyoma without malignancy identified. Immunohistochemical (IHC) studies demonstrated that the neoplastic cells to be strongly positive for CD45, CD43, CD33, and variable CD7 (Fig. 3), with focal and weak immunoreactivity for CD34 and CD117. IHC studies were negative for MPO, CD56, cytokeratin AE1/AE3 and lysozyme. These findings supported the diagnosis of myeloid sarcoma of the left ovary.

The patient's recovery from surgery was uncomplicated. She continued oncologic care with medical oncology and returned to systemic treatment with azacitidine and gilteritinib. Four months after surgery, the patient was seen by the bone marrow transplant team with a plan for total body irradiation followed by stem cell transplantation. Unfortunately, she succumbed to COVID-19 pneumonia within the next two months.

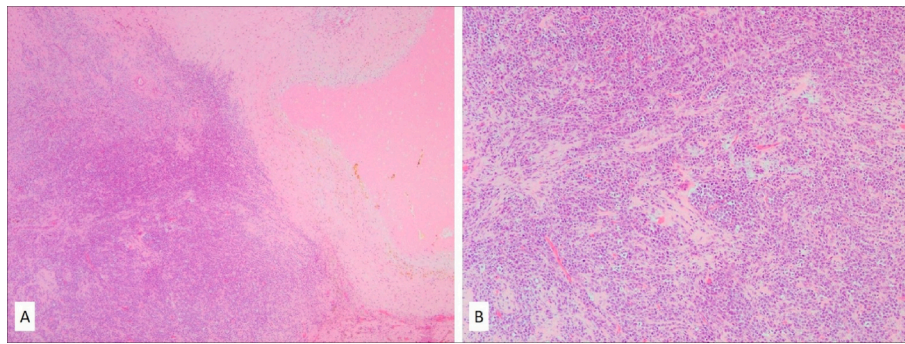
### 3. Methods

This study is a case report with a review of the current literature on the reported cases of ovarian myeloid sarcoma. We searched MEDLINE, using PubMed for all English language articles from 1980 to 2021, with search terms including "acute myeloid leukemia," "ovarian myeloid," "granulocytic sarcoma," and "ovarian chloroma."

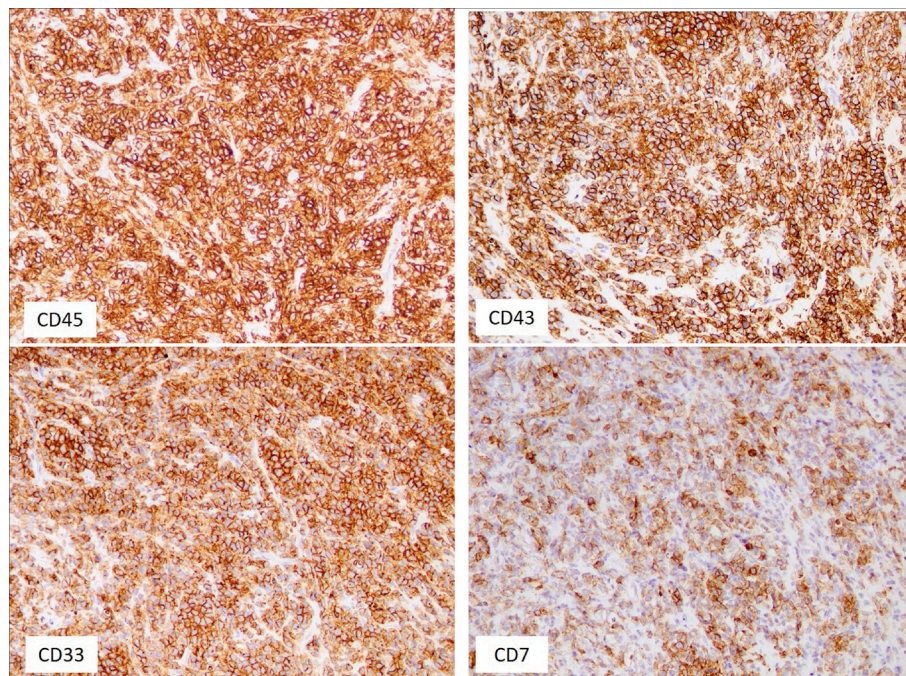


**Fig. 1.** CT of Abdomen/Pelvis obtained after initial AML treatment and prior to total robotic hysterectomy, bilateral salpingo-oophorectomy, and extensive enterolysis. A) Axial image of the right adnexal mass measuring  $6.9 \times 11.1$  cm and B) Axial image of the left ovarian mass measuring  $7.6 \times 5.3$  cm. C) Coronal image demonstrating bilateral adnexal masses.





**Fig. 2.** Low and high-powered view of the ovarian mass histopathology demonstrating myeloid sarcoma with extensive necrosis and fibrosis within the left ovary (A). The tumor diffusely infiltrated ovarian stroma (B) in the form of nests composed of immature mononuclear cell morphologically consistent with myeloid blasts (Hematoxylin and Eosin stain, magnifications 4x and 10x, respectively).



**Fig. 3.** Immunohistochemical studies. The neoplastic cells are diffusely and strongly positive for CD45, CD43, CD33, and variably for CD7 (magnification 20x).

#### 4. Discussion

In this case report, we focus on myeloid sarcoma of the ovary, with only several reports of bilateral ovarian occurrences (see Table 1). It is essential to note that other gynecologic tract organs, such as the mesosalpinx, cervix, uterus, and fallopian tubes, have been documented to have myeloid sarcoma with symptoms ranging from vaginal bleeding, skin rashes, dysmenorrhea, and dysuria (Garcia et al., 2006; Nazer et al., 2012; Oliva et al., 1997). The differential diagnosis for masses of the ovaries includes hematomas and abscesses that can be excluded based on CT and MRI, followed by fine needle aspiration or biopsy for histological analysis (Neiman et al., 1981; Pui et al., 1994). Misdiagnoses have been reported in many cases of myeloid sarcoma given the broad differential, including primary benign tumors (mature teratoma, fibroma, serous adenoma), adult granulosa cell tumors, primary malignant tumors (e.g., dysgerminoma), various hematopoietic malignancies (Hodgkin lymphoma, histiocytic lymphoma, mucosa-associated lymphoid tissue (MALT) lymphoma, diffuse large B-cell lymphoma, lymphoblastic lymphoma, Burkitt lymphoma, blastic plasmacytoid dendritic cell neoplasm, thymoma), soft tissue tumors (Ewing sarcoma and other small round cell tumors), melanoma, or poorly differentiated

carcinoma (Meis et al., 1986; Mukuda et al., 2018). The diagnosis of myeloid sarcoma is challenging and should be on the differential from any atypical cellular infiltrate (Almond et al., 2017). Given a substantial morphologic overlap with a variety of other tumors, a comprehensive immunohistochemical work-up is essential for the proper diagnosis. This is particularly important if the diagnosis of MS precedes AML, and requires cytogenetic and molecular studies, when possible.

First-line treatment for ovarian MS is total hysterectomy and bilateral salpingo-oophorectomy with systemic induction chemotherapy, as surgical excision does not necessarily delay the spread of the disease (Ding et al., 2015) (Almond et al., 2017; Capote et al., 2018; Peloquin et al., 2013; Wang et al., 2017). There is a paucity of literature and no significant prospective data reporting the survival and prognosis of patients with MS, given its rarity (Almond et al., 2017). Shared decision making should also be used when counseling regarding hysterectomy in the setting of ovarian myeloid sarcoma (Hernández et al., 2002). Untreated isolated MS usually transforms to AML within a 10-to-12-month period, and the prognosis varies by site of involvement (Bekkenk et al., 2004; Yamauchi and Yasuda, 2002). Often, once a single location of the extramedullary disease is identified, progression and recurrence to another organ usually occur within one year (Tripathi et al., 2005).

**Table 1**

**Summary of cases reporting myeloid sarcoma of the ovary.** Abbreviations: AML (acute myeloid leukemia), yrs (years), mo (months), PCOS (polycystic ovarian syndrome), BHA (N4-behenoyl-1-β-D-arabinofuranosylcytosine), DIC (Disseminated intravascular coagulation), APL (acute promyelocytic leukemia), DCNP (2,6-dichloro-4-nitrophenol).

Case No	Age (yrs)	Site	Symptoms	History of Hematologic Disease	AML at Diagnosis	Other Sites of Disease at Diagnosis	Reoccurrence	Treatment/ Outcome/ Clinic Follow up	Author	Year
1	48	Bilateral fallopian tubes, left ovary	PCOS follow-up, elevated testosterone, pancytopenia	No	Yes	No	Yes	Subsequently found jejunos and uterine involvement after salvage reinduction with high-dose cytarabine and gemtuzumab. Two months after the diagnosis of relapse, the patient died from cardiopulmonary arrest secondary to disease	Kahn	2019
2	30	Bilateral ovaries	Dry cough, fever, chills	No	No	Pericardial nodules, pleura	No	Treated with chemotherapy and allogeneic hematopoietic stem cell transplantation. No evidence of leukemia at 1 yr follow up	Choi	2019
3	27	Right ovary	Abdominal pain	No	Yes	Left pelvic side wall	Not stated	Treated with right salpingo-oophorectomy, infracolic omentectomy, and chemotherapy, AML after 5 days, cytosine arabinoside and idarubicin chemotherapy	Ding	2015
4	49	Right ovary	Not stated	Not stated	No	Not stated	Yes	Treated with right oophorectomy and chemotherapy, AML after 12 mo; recurrent	Wang	2009
5	59	Uterus, both ovaries	Left lower extremity pain, swelling	No	No	No	Not stated	Died, no evidence of leukemia, two months	Garcia	2006
6	35	Uterus, parametrial soft tissue, left ovary, left fallopian tube	Vaginal bleeding	No	No	Breast	No	Alive, no evidence of leukemia at 17 mo follow up	Garcia	2006
7	25	Right ovary	NA	No	No	No	Pelvic mass, 2 yrs	Treated with chemotherapy, Alive, no evidence of leukemia at 30 mo	Garcia	2006
8	44	Left Ovary	Vaginal bleeding	No	AML-M4Eo	No	No	Alive, no evidence of leukemia, 5 yrs	Garcia	2006
9	17	Uterus, right ovary	Dysmenorrhea, dysuria	No	No	No	AML, 2 mo	Died of leukemia, 5 mo	Garcia	2006
10	42	Ovarian parenchyma, uterine myometrium, the stroma of cervix, endometrium, fallopian tubes	Moderate to heavy vaginal bleeding	No	No	Omentum, peritoneum	AML progression	Laparotomy with biopsies as debulking was considered risky due to dense adhesions, two cycles of chemotherapy (vincristine, cytosine arabinoside, daunorubicin and prednisolone), died from progression of leukemia a few months later	Tripathi	2005
11	19	Right ovary	Abdominal pain	No	No	No	AML, 3 mo	Treated with right oophorectomy and standard chemotherapy, AML M2 after 3 mo	Mehta and Kane	2004

(continued on next page)

Table 1 (continued)

Case No	Age (yrs)	Site	Symptoms	History of Hematologic Disease	AML at Diagnosis	Other Sites of Disease at Diagnosis	Reoccurrence	Treatment/ Outcome/ Clinic Follow up	Author	Year
12	26	Right ovary	Lower abdominal pain	No	No	No	No	Two cycles of induction chemotherapy (daunorubicin/ cytosine arabinoside) and right oophorectomy, Alive with no evidence of leukemia at 12 mo	Sreejith	2000
13	12	Left ovary	Abdominal pain, palpable mass	No	No	No	No	Treatment not stated, Alive with no evidence of leukemia 7 mo	Jung	1999
14	25	Right ovary	Adnexal mass	Initially presenting as clavicular soft tissue mass treated with chemotherapy	Yes	No	Not stated	Right oophorectomy and chemotherapy	Oliva	1997
15	30	Right and left ovary	Abdominal pain	No	Not stated	No	No	Treatment bilateral salpingo-oophorectomy, AML and died 27 months	Oliva	1997
16	31	Right ovary	Massive breast engorgement, right adnexal mass, and small scalp mass	No	Not stated	No	Not stated	Chemotherapy, right oophorectomy and omentectomy, outcome not stated	Oliva	1997
17	31	Ovary	Adnexal mass	No	Not stated	No	Not stated	Treatment not stated, the outcome not stated	Oliva	1997
18	43	Right ovary	Right adnexal mass	No	Yes	No	No	Chemotherapy, right oophorectomy, Alive with no evidence of leukemia at 18 mo	Oliva	1997
19	31	Right ovary	Routine pelvic exam	No	No	No	Yes	Treated with chemotherapy and right oophorectomy, AML-M2, 12 mo; died, 14 mo	Aguiar	1993
20	49	Right ovary	Lower abdominal discomfort	No	No	No	No	Treatment not stated; no evidence of leukemia at 12 mo	Pressler	1992
21	Not stated	Right ovary	Not stated	Not stated	No	Not stated	Yes	High-dose Polychemo/RXT Treatment, Removal of the tumor and subsequent polychemotherapy was followed by remission. A local recurrence was treated with radiation and high-dose polychemotherapy. Complete remission 7 yrs	Stefenelli	1991
22	33	Left ovary, adnexa and uterus	Severe abdominal pain	No	Yes	No	Yes – right ovarian myeloblastoma	Evidence of hematological relapse followed the presentation of the ovarian tumor within a month, left salpingo-oophorectomy and total hysterectomy, subsequently treated with BHAC, acracynomycine, and vincristine	Yamamoto	1991
23	15	Bilateral ovarian and left breast myeloblastoma	Lower abdominal mass and breast mass	Not stated	APL	Breast	Yes	Initially diagnosed with AML, evidence of hematological relapse and chemotherapy followed the presentation of the ovarian tumor and died	Yamamoto	1991

(continued on next page)

Table 1 (continued)

Case No	Age (yrs)	Site	Symptoms	History of Hematologic Disease	AML at Diagnosis	Other Sites of Disease at Diagnosis	Reoccurrence	Treatment/ Outcome/ Clinic Follow up	Author	Year
24	46	Left ovary	Abdominal pain with nausea and vomiting, weight loss	Dysplastic nevus syndrome	Yes, during work-up for an ovarian mass	No	Died shortly after diagnosis	within a month of ovarian tumor diagnosis due to thrombocytopenia leading to gastrointestinal and intracranial bleeding complicated by septicemia due to <i>Pseudomonas aeruginosa</i> and DIC. Deferred surgery due to thrombocytopenia, died of complications of acute myeloid leukemia a few days later after declining chemotherapy	Magliocco	1991
25	3	Bilateral ovaries	Lower abdominal mass, anemia	No	No	No	No	Doxorubicin and cytosine arabinoside began. Complete remission of leukemia occurred following the first course of chemotherapy and the patient was still in remission six months after diagnosis.	Morgan	1981
26	18	Right ovary	Abdominal pain, anorexia, nausea, alternating diarrhea, constipation	Yes	Yes	Two extrapleural masses in the retrosternal space, a third in the region of the tenth thoracic vertebra	Not stated	Not stated	Ballon	1978
27	16	Left ovary	Abdominal pain	No	No	Abdominal serosa and thoracic cavity	Yes	Laparotomy with partial resection of ovary, DCNP therapy induced hematological remission, the tumor showed progressive growth and later diagnosed with AML, died of ileus	Kobayashi	1977
28	36	Left and right ovary, fallopian tube	Intermittent, crampy, lower abdominal pains, fatigue, weakness and persistent fever	No	Yes	Liver, spleen, serosa of the bowel, kidneys	Not stated	Not stated	Castilone	1962

There is robust research testicular involvement following AML secondary to testes serving as a sanctuary site. One possible approach is to have targeted radiotherapy to the testes versus orchiectomy in addition to adjuvant therapy (Dang et al., 2017; Góes et al., 2014). Timely diagnosis and surgical management of an ovarian mass, in the setting of AML, via bilateral salpingo-oophorectomy with total hysterectomy is essential to improving patient outcomes.

**Author contributions**

Jenci Hawthorne MD, Hajrunisa Cubro MD, and Elizabeth Farabee MD performed literature review, discussion, and table formation. Samer Z. Al-Quran MD, Mustafa Al-Kawaaz MD, and Semir Vranic MD, PhD performed pathology review and report. Whitney Goldsberry MD reviewed article, discussion, and IRB submission. Daniel Metzinger MD and Sarah Todd MD performed the surgery and care of this patient and reviewed the manuscript.

**Declaration of Competing Interest**

The authors declare that they have no known competing financial interests or personal relationships that could have appeared to influence the work reported in this paper.

**References**

Almond, L.M., Charalampakis, M., Ford, S.J., Gourevitch, D., Desai, A., 2017. Myeloid Sarcoma: Presentation, Diagnosis, and Treatment. *Clin. Lymphoma Myeloma Leuk* 17 (5), 263–267. <https://doi.org/10.1016/j.clml.2017.02.027>.  
 Avni, B., Koren-Michowitz, M., 2011. Myeloid sarcoma: current approach and therapeutic options. *Ther. Adv. Hematol.* 2 (5), 309–316. <https://doi.org/10.1177/2040620711410774>.  
 Bakst, R.L., Tallman, M.S., Douer, D., Yahalom, J., 2011. How I treat extramedullary acute myeloid leukemia. *Blood* 118 (14), 3785–3793. <https://doi.org/10.1182/blood-2011-04-347229>.  
 Bekkenk, M.W., Jansen, P.M., Meijer, C.J.L.M., Willemze, R., 2004. CD56+ hematological neoplasms presenting in the skin: a retrospective analysis of 23 new

- cases and 130 cases from the literature. *Ann. Oncol.* 15 (7), 1097–1108. <https://doi.org/10.1093/annonc/mdh268>.
- Byrd, J.C., Weiss, R.B., 1994. Recurrent granulocytic sarcoma. An unusual variation of acute myelogenous leukemia associated with 8;21 chromosomal translocation and blast expression of the neural cell adhesion molecule. *Cancer*, 73(8), 2107–2112. doi: 10.1002/1097-0142(19940415)73:8<2107::aid-cncr2820730815>3.0.co;2-w.
- Capote, S., Sánchez-Iglesias, J.L., Cubo-Abert, M., De la Torre, J., Centeno-Mediavilla, C., Pérez-Benavente, A., Gil-Moreno, A., 2018. Myeloid sarcoma as a simulator of advanced ovarian cancer: A case report. *Eur. J. Obstet. Gynecol. Reprod. Biol.* 225, 259–260. <https://doi.org/10.1016/j.ejogrb.2018.03.056>.
- Dang, B.N., De Oliveira, S., Bowles, L., Moore, T.B., 2017. Isolated Testicular Recurrence of AML in Patients With Chronic GVHD >1 Year Following Allogeneic Stem Cell Transplant. *J. Pediatr. Hematol. Oncol.* 39 (8), e423–e425. <https://doi.org/10.1097/mph.0000000000000989>.
- Ding, J., Li, H., Qi, Y.K., Wu, J., Liu, Z.B., Huang, B.C., Chen, W.X., 2015. Ovarian granulocytic sarcoma as the primary manifestation of acute myelogenous leukemia. *Int. J. Clin. Exp. Pathol.* 8 (10), 13552–13556.
- García, M.G., Deavers, M.T., Knoblock, R.J., Chen, W., Tsimberidou, A.M., Manning Jr., J.T., Medeiros, L.J., 2006. Myeloid sarcoma involving the gynecologic tract: a report of 11 cases and review of the literature. *Am. J. Clin. Pathol.* 125 (5), 783–790. <https://doi.org/10.1309/h9mm-21fp-t7yb-l3pw>.
- Góes, L.S., Lopes, R.L., Campos, O.H., Oliveira, L.C., Sant'Anna, A.C., Dall'Oglio, M.F., Srougi, M., 2014. Recurrence of acute myeloid leukemia in cryptorchid testis: case report. *Einstein (Sao Paulo)* 12 (1), 109–111. <https://doi.org/10.1590/s1679-45082014rc2689>.
- Hernández, J.-A., Navarro, J.-T., Rozman, M., Ribera, J.-M., Rovira, M., Bosch, M.-A., Millá, F., 2002. Primary Myeloid Sarcoma of the Gynecologic Tract: A Report of Two Cases Progressing to Acute Myeloid Leukemia. *Leukemia & Lymphoma* 43 (11), 2151–2153. <https://doi.org/10.1080/1042819021000016096>.
- Meis, J.M., Butler, J.J., Osborne, B.M., Manning, J.T., 1986. Granulocytic sarcoma in nonleukemic patients. *Cancer* 58 (12), 2697–2709. [https://doi.org/10.1002/1097-0142\(19861215\)58:12<2697::aid-cncr2820581225>3.0.co;2-r](https://doi.org/10.1002/1097-0142(19861215)58:12<2697::aid-cncr2820581225>3.0.co;2-r).
- Mukuda, N., Fujii, S., Inoue, C., Fukunaga, T., Oishi, T., Harada, T., Ogawa, T., 2018. Bilateral Ovarian Tumors on MRI: How Should We Differentiate the Lesions? *Yonago acta medica* 61 (2), 110–116. <https://doi.org/10.33160/yam.2018.06.003>.
- Nazer, A., Al-Badawi, I., Chebbo, W., Chaudhri, N., El-Gohary, G., 2012. Myeloid sarcoma of the vulva post-bone marrow transplant presenting as isolated extramedullary relapse in a patient with acute myeloid leukemia. *Hematol. Oncol. Stem Cell Ther.* 5 (2), 118–121. <https://doi.org/10.5144/1658-3876.2012.118>.
- Neiman, R.S., Barcos, M., Berard, C., Bonner, H., Mann, R., Rydell, R.E., Bennett, J.M., 1981. Granulocytic sarcoma: a clinicopathologic study of 61 biopsied cases. *Cancer* 48 (6), 1426–1437. [https://doi.org/10.1002/1097-0142\(19810915\)48:6<1426::aid-cncr2820480626>3.0.co;2-g](https://doi.org/10.1002/1097-0142(19810915)48:6<1426::aid-cncr2820480626>3.0.co;2-g).
- Oliva, E., Ferry, J.A., Young, R.H., Prat, J., Srigley, J.R., Scully, R.E., 1997. Granulocytic sarcoma of the female genital tract: a clinicopathologic study of 11 cases. *Am. J. Surg. Pathol.* 21 (10), 1156–1165. <https://doi.org/10.1097/00000478-199710000-00005>.
- Peloquin, G.L., Chen, Y.-B., Fathi, A.T., 2013. The evolving landscape in the therapy of acute myeloid leukemia. *Protein Cell* 4 (10), 735–746. <https://doi.org/10.1007/s13238-013-3057-2>.
- Pileri, S.A., Orazi, A., Falini, B. Myeloid Sarcoma in WHO Classification of Tumours of Haematopoietic and Lymphoid Tissue. Retrieved from.
- Pui, M.H., Fletcher, B.D., Langston, J.W., 1994. Granulocytic sarcoma in childhood leukemia: imaging features. *Radiology* 190 (3), 698–702. <https://doi.org/10.1148/radiology.190.3.8115614>.
- Tripathi, R., Sharma, B., Chaturvedi, K.U., Khurana, N., Mala, Y.M., 2005. Granulocytic sarcoma of the female genital tract: report of a case with an unusual presentation. *Gynecol. Obstet. Invest.* 59 (4), 189–191. <https://doi.org/10.1159/000083896>.
- Wang, P., Li, Q., Zhang, L., Ji, H., Zhang, C.Z., Wang, B., 2017. A myeloid sarcoma involving the small intestine, kidneys, mesentery, and mesenteric lymph nodes: A case report and literature review. *Medicine (Baltimore)* 96 (42), e7934.
- Wilson, C.S., Medeiros, L.J., 2015. Extramedullary Manifestations of Myeloid Neoplasms. *Am. J. Clin. Pathol.* 144 (2), 219–239. <https://doi.org/10.1309/ajcpo58ywibubesx>.
- Yamauchi, K., Yasuda, M., 2002. Comparison in treatments of nonleukemic granulocytic sarcoma: report of two cases and a review of 72 cases in the literature. *Cancer* 94 (6), 1739–1746. <https://doi.org/10.1002/cncr.10399>.