

## Case Report

# Comprehensive genomic profiling of pediatric peritoneal mesothelioma: case report with a literature review

Jasmina Redzepagic<sup>1</sup>, Zlatan Zvizdic<sup>2</sup>, Nuriya Bilalovic<sup>1</sup>, Emir Milisic<sup>2</sup>, Melika Bukvic<sup>3</sup>, Semir Vranic<sup>4,\*</sup>

<sup>1</sup>Department of Pathology, University Clinical Center Sarajevo, 71000 Sarajevo, Bosnia and Herzegovina

<sup>2</sup>Department of Pediatric Surgery, University Clinical Center Sarajevo, 71000 Sarajevo, Bosnia and Herzegovina

<sup>3</sup>Department of Radiology, University Clinical Center Sarajevo, 71000 Sarajevo, Bosnia and Herzegovina

<sup>4</sup>College of Medicine, QU Health, Qatar University, 2713 Doha, Qatar

\*Corresponding author. College of Medicine, QU Health, Qatar University, 2713 Doha, Qatar. E-mail: semir.vranic@gmail.com

### Abstract

Malignant peritoneal mesothelioma is an extremely rare and poorly recognized neoplasm in children. A 5-year-old boy presented with a 1-year history of progressive painless abdominal distension. A CT revealed a  $19 \times 19 \times 11$  cm<sup>3</sup> cystic mass in the right hemiabdomen, without infiltrating the surrounding structures. The tumor was completely removed by surgery. The microscopic and immunohistochemical analyses confirmed peritoneal mesothelioma. Comprehensive genomic profiling revealed no major driving mutations including BAP1, no fusions, but with amplifications of AURKA, AURKC, HLA-1B, ZNF-217, OR5F1 and MEN1 genes. Imaging follow-up 3 months after surgery revealed metastatic disease. The patient died of pneumonia at another hospital shortly after the last follow-up examination at our institution. Pediatric peritoneal mesothelioma is an extremely rare malignancy with limited targeted options and a poor prognosis. Some of the identified molecular genomic biomarkers require further exploration and validation in this cancer.

**Keywords:** peritoneal mesothelioma; children; prognosis; genomic alterations; outcome

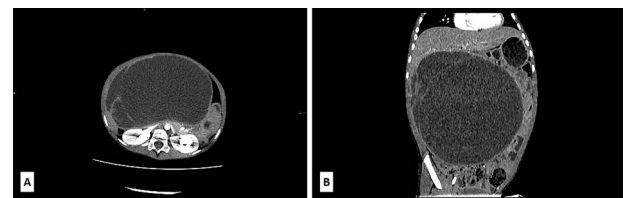
### Introduction

Malignant mesothelioma is an aggressive malignancy, arising from mesothelial cells of peritoneal, pleural, pericardial and tunica vaginalis lining cells [1]. Malignant mesothelioma is an extremely rare tumor in the pediatric population. Its incidence is estimated to be around 0.5–1.0 cases per 10 million per year [2, 3]. It is associated with a poor prognosis with an estimated median survival of only 6–12 months [1]. Pleural mesotheliomas mostly arise in patients with a history of asbestos exposure, whereas the association with asbestos exposure and other carcinogens in peritoneal mesothelioma is less clear, including pediatric peritoneal mesotheliomas, suggesting that genetic alterations could play an important role in their development and progression [4, 5].

Given their poor prognosis and lack of well-established risk factors and treatment options, we attempted to seek driver genetic alterations that define peritoneal mesothelioma and to potentially identify targetable genetic alterations to improve the outcome through next-generation sequencing.

### Case report

A 5-year-old boy presented with a 1-year history of abdominal discomfort and distension. Clinical examination by inspection and palpation revealed the presence of an abdominal mass that



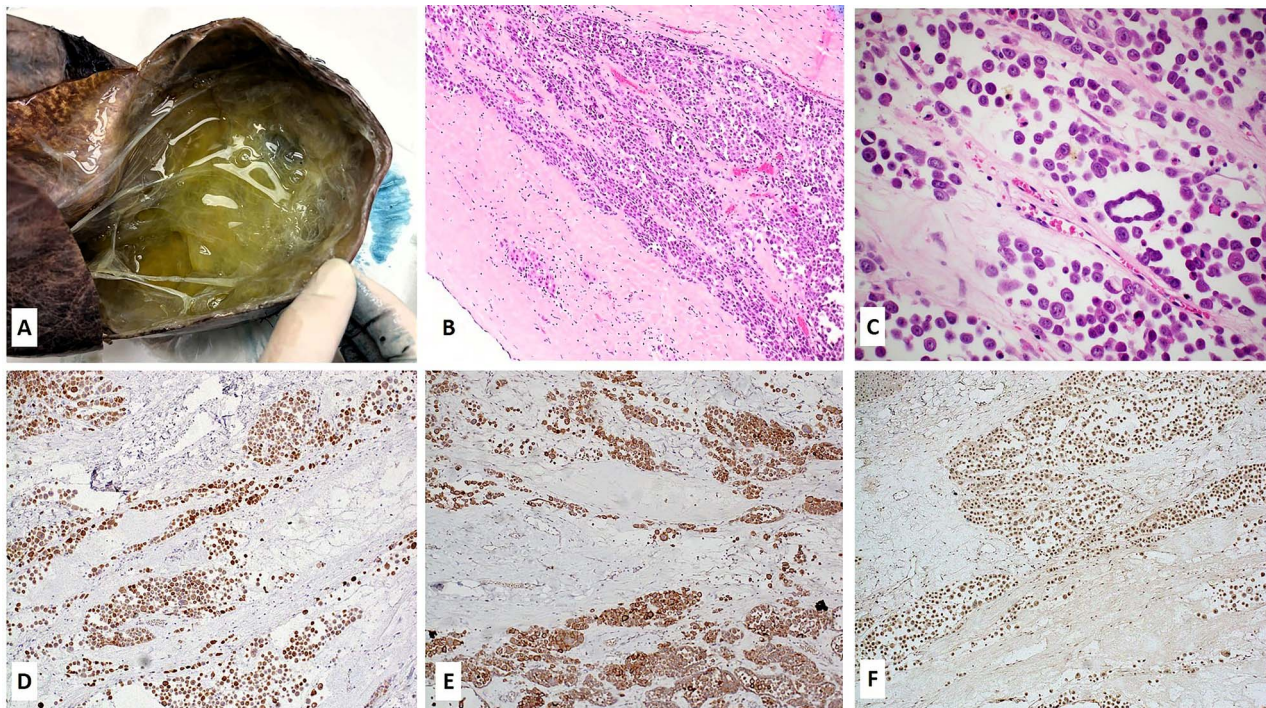
**Figure 1.** (A) Axial low-dose CT scan shows a huge cystic mass with few enhanced thin septa in the lateral aspect. Cystic space contains fluid of density 47–60HU. (B) Sagittal low-dose CT scan revealed that the cystic mass had expansive features with its cranial aspect not differentiated from the lower liver surface. No certain CT signs of liver infiltration were seen.

was confirmed by a CT scan. It revealed a multilocular cystic mass, with septations, filled with dense content (47–60 HU) and measured  $113 \times 190 \times 195$  mm<sup>3</sup> (Fig. 1A). The lesion had an expansive growth but without clear liver infiltration (Fig. 1B). Differential diagnoses included mucinous cystadenoma, mesenteric lymphangioma, and hydatid cyst. A lung CT scan revealed a subpleural node in the right lower lobe, measuring 3.6 mm. Blood count test revealed elevated LDH levels of 391 U/L (range 100–190) and slightly elevated NSE level of 45.1 ng/mL (range 0–16.3) and CA 19–9 39.9 U/L (range 0–37), with normal levels of ferritin, AFP, CEA and  $\beta$ -HCG.

Received: March 27, 2024. Accepted: May 1, 2024

Published by Oxford University Press and JSCR Publishing Ltd. © The Author(s) 2024.

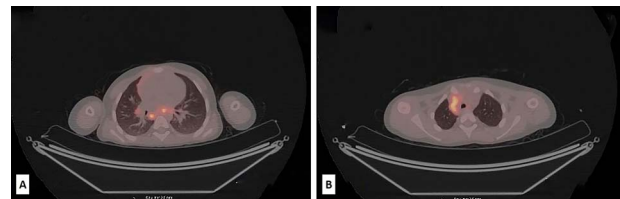
This is an Open Access article distributed under the terms of the Creative Commons Attribution License (<https://creativecommons.org/licenses/by/4.0/>), which permits unrestricted reuse, distribution, and reproduction in any medium, provided the original work is properly cited.



**Figure 2.** Gross, microscopic and immunohistochemical findings of the tumor. (A) Grossly, a multilocular cystic mass was seen, with cysts filled with yellowish-to-green fluid; (B–C) Microscopic features of the tumor (Hematoxylin and Eosin stain, 10X magnification image B and 20X magnification image C); the tumor cells were diffusely positive for calretinin (D), D2.40 (podoplanin) (E) and retained BAP1 protein expression (F) (immunohistochemistry, DAB staining).

The patient underwent surgery and the tumor was completely removed. Grossly, it measured  $190 \times 190 \times 110 \text{ mm}^3$ , showing a multilocular cystic pattern, with cysts filled with yellowish-to-green fluid (Fig. 2A). Microscopically, the neoplasm was composed of the sheets, nests and micropapillary configurations of epithelioid cells within the loose fibromyxoid stroma (Fig. 2B). The epithelioid cells had eosinophilic cytoplasm, opened chromatin, prominent nucleoli and a few with multinucleations (Fig. 2C). Epithelioid cells were cohesive, and showed intercellular 'windows'. Nuclear atypia was marked (Fig. 2C). The tumor cells were positive for wide-spectrum cytokeratins (AE1/AE3), CK19, calretinin, WT-1, podoplanin (D2–40) (Fig. 2D–E), while CK7, HepPar1, SALL4 and CD99 were negative. The tumor cells also retained BAP1 protein expression (Fig. 2F). Morphologic and immunohistochemical findings were consistent with peritoneal mesothelioma. Due to its rarity and challenging diagnosis, the case was also sent for a second opinion, and expert pathologists at another institutions concurred with our diagnosis (see Acknowledgement).

The postoperative course was eventful. Four months later, during the routine follow-up, an abdominal CT scan revealed no residual disease but showed significant lymphadenopathy in the lower abdomen, while PET/CT revealed metabolically active deposits in the retroperitoneal, mediastinal, hilar and neck lymph nodes (Fig. 3A–B). A few suspected small nodes were also found in the left lower lung lobe. Lab tests showed high levels of LDH 548 U/L (range 100–190). Based on the clinical findings and the limited therapeutic options, the tumor board decided to do comprehensive genomic profiling of the tumor. The profiling was performed with the OncoPrint Comprehensive Assay Plus (DNA, 498 genes) and Archer Fusion Plex Pan Solid Tumor v2 Panel (RNA, 137 genes) at the University Hospital Basel (Switzerland) (see Acknowledgement).



**Figure 3.** Low-dose PET/CT scan from the level of upper thoracic aperture revealing enlarged and metabolically active retrocausal and mediastinal lymph nodes, with  $\text{SUV}_{\text{max}}$  8.6 and  $\text{SUV}_{\text{max}}$  up to 6.5 (A). Also, at the level of the carina and subcarinal region metabolically active lymph nodes were seen ( $\text{SUV}_{\text{max}}$  up to 7.6). In the right hilus, metabolically active lymph node  $\text{SUV}_{\text{max}}$  up to 3.5 was also observed (B).

The genomic tests revealed a microsatellite stable tumor, without major driving or targetable mutations including BAP1, with no fusions, but with amplifications of *AURKA*, *AURKC*, *HLA-1B*, *ZNF-217*, *OR5F1* and *MEN1* genes. The tumor had a low mutational burden (1.9 mutations/Mb). Given the results of molecular profiling, the tumor board decided to treat the patient with adjuvant chemotherapy. However, during that period, the patient developed pneumonia and died of it at another hospital. A post-mortem examination was not performed.

## Discussion

Pediatric peritoneal mesotheliomas are very rare malignancies with limited data in the current literature. According to epidemiologic studies and autopsy results, mesotheliomas of children represent 2–5% of all mesotheliomas, with a reported incidence of 0.5–1 case/10 million per year [3]. These cancers may have some distinct clinicopathological features compared with their adult counterparts. There is a striking male-to-female predominance

**Table 1.** Overview of genomic features of peritoneal mesotheliomas in the pediatric population

Year	Author	Patients (n)	Age (range)	Location	Molecular assay (method)	Identified genomic alterations (n)
2021	Argani et al. [18]	5	15 years (mean) (range, 8–16)	Peritoneum and tunica vaginalis testis	FISH, Archer FusionPlex (RNA sequencing) and conventional cytogenetics	STRN-ALK fusion (n = 1), ALK-TPM1 (n = 1) ALK rearrangements (n = 2) t(2;15) (n = 1)
2021	Murumagi et al. [19]	1	5 years	Peritoneum	NGS Foundation One, FISH	STRN-ALK fusion
2021	Sakata et al. [21]	1	14 years	Peritoneum	NGS	STRN-ALK rearrangement
2021	Olmedilla et al. [22]	1	12 years	Peritoneum	FISH, NGS (Impact panel)	TERT promoter translocation
2021	Ren et al. [23]	2	15 years both	Peritoneum and pericardium	RNA sequencing (Illumina TruSight RNA Fusion Panel), FISH	EWSR1-ATF fusion (n = 1) EWSR1 rearrangement (n = 1)
2018	Mijalovsky et al. [20]	1	4 months	Peritoneum	WES	ATM mutation
2016	Loharamtaweethong et al. [32]	1	10 years	Peritoneum	FISH	ALK translocation
2013	Sugalski et al. [10]	1	7 years	Peritoneum	Conventional cytogenetic analysis	trisomy 11, deletion 19q13.33

FISH, Fluorescent In Situ Hybridization; NGS, next-generation sequencing; WES, whole exome sequencing.

in adults (5:1), but in the pediatric population, mesotheliomas have nearly equal gender distribution. Also, there is a nearly equal distribution of peritoneal and pleural mesotheliomas in children compared to adults where pleural mesotheliomas predominate. Other characteristics, including age, the lack of previous asbestos or other carcinogen exposures, negative family history, and the presence of epithelioid morphology, with retained BAP1 expression, are also known clinicopathologic features common in pediatric mesotheliomas [6]. The pathogenesis of pediatric mesotheliomas remains unclear, compared to adult mesotheliomas. Pediatric mesotheliomas are found to harbor different genetic abnormalities, which are not related to asbestos exposure [5]. Most of these characteristics were confirmed in our case [7–14].

There are no unified treatment protocols for peritoneal mesotheliomas, but cytoreductive surgery along with hyperthermic intraperitoneal preoperative surgery is considered the best treatment option. Our patient had surgery and was a candidate for adjuvant chemotherapy and eventually for targeted therapy.

Overall, malignant peritoneal mesothelioma has a poor prognosis, with a 10-year survival of only 9% [15, 16]. Limited targeted therapeutic options are available for these patients. Therefore, we conducted a comprehensive genomic profiling of our case, which revealed no somatic mutations including the BAP1 gene (mutated in 85% of peritoneal mesotheliomas and around 30% of pleural mesotheliomas) [17], but amplifications of AURKA, AURKC, HLA-1B, ZNF-217, OR5F1 and MEN1 gene. Notably, the lack of BAP1 genomic alterations correlated well with its retained protein expression by immunohistochemistry. Our comprehensive literature search on molecular profiling of pediatric peritoneal mesotheliomas revealed only a few studies (summarized in Table 1). The most prevalent genomic alterations included ALK, STRN, TMP1, ATM and TERT mutations, fusions, and rearrangements, with few chromosomal aberrations [18–24]. ALK gene alterations appear to be the most consistent genomic alterations in pediatric peritoneal mesotheliomas (Table 1). Notably, Murumagi et al. found the STRN-ALK rearrangement in disseminated peritoneal mesothelioma from a 5-year-old boy [19]. The patient was subsequently treated with an ALK inhibitor, reaching full remission for 3 years [19]. Several other genomic alterations have also been described in pediatric cases, including EWSR1-ATF1 fusions

and ALK rearrangements [23, 24] (Table 1). However, none of these genomic alterations were found in our case. The reasons for the discrepancies may be related to different genomic platforms for the assessment and panels used for the detection (Table 1).

Much more information on genomic features is available in adult mesotheliomas. Thus, Joseph et al. explored the mutational profile of 13 peritoneal mesotheliomas by NGS. They found the most frequent alteration to be the inactivation of the BAP1 gene, followed by mutations in NF2, SETD2 and DDX3X, homozygous deletion of CDKN2, and MET gene amplification [17]. Offin et al. reported similar genomic alterations among 50 adult peritoneal mesotheliomas (mutations of BAP1, NF2, SETD2 and TP53) [25]. Takeda et al. performed FISH analysis in 54 cases and reported inconsistent and heterogeneous molecular genetic pathways in pleural and peritoneal mesotheliomas [26]. Similar to our case, Takeda et al. also found a predominantly low tumor mutational burden with a median number of mutations of 1.8/Mb [26]. Hung et al. reported additional genomic alterations among adult peritoneal mesotheliomas beyond BAP1 mutations and ALK rearrangements, including TP53, TFAF7 and SUZ1 mutations [27].

One of the interesting findings from our case is AURKA gene amplification. Notably, Guo et al. found that the expression in Aurora kinase A (encoded by the AURKA gene) was significantly higher in malignant mesothelioma than in normal mesothelial cells and identified Aurora A as a potential diagnostic marker in differentiating benign mesothelial proliferation from malignant mesotheliomas [28]. Also, AURKA gene alterations were associated with poor prognosis [28]. The AURKA gene could be a potential therapeutic target with AURKA kinase A inhibitors [28]. Another relevant finding in our study is the Zinc finger protein 217 (ZNF217) gene amplification. ZNF217 is a transcription factor, involved in cancer initiation and progression [29]. Interestingly, Ugurluer et al. detected ZNF217 mutation as a variant of unknown or additional significance in a small cohort of 11 pleural and peritoneal mesotheliomas [30]. Mutation in the MEN1 gene could be related to Multiple endocrine neoplasia syndrome, while OR5F1 alterations have not been reported yet in peritoneal mesotheliomas. Expression of HLA antigens can determine tumor progression and metastatic potential by influencing the immune response [31].

In conclusion, peritoneal mesothelioma in the pediatric population is extremely rare. It is still a fatal and aggressive disease with a poor outcome. Comprehensive genomic profiling may reveal novel therapeutic targets and should be done in such difficult-to-treat malignancies.

## Acknowledgements

We acknowledge Professor Richard L Attanoos, Cardiff and Vale University Health Board; University Hospital of Wales, Health Park, Cardiff, United Kingdom and Univ.-Prof. Dr. Felix Offner from the Institute of Pathology, University Teaching Hospital Feldkirch, Feldkirch, Austria, for their expert opinions in confirming the histopathologic diagnosis for this challenging case. We also appreciate the support from PD Dr. med. Obinna Chijioke and Dr. phill. Ilaria Alborelli (University Hospital Basel, Switzerland) for performing and interpreting NGS results for the case.

Qatar National Library (QNL) funded open access of this article.

## Author contributions

Z.Z. and E.M. treated the patient. J.R., N.B., M.B. and S.V. were involved in the diagnostics. J.R., Z.Z. and S.V. conceived this case presentation and drafted the manuscript. All authors read and approved the final version of the manuscript.

## Conflict of interest statement

The authors declare no conflict of interest.

## Funding

None declared.

## Data availability

Data available from the corresponding authors on a reasonable request.

## Informed consent

The patient's mother consented to publishing this case and accompanying images. A local institutional review board has a policy not to review case reports.

## References

- Bellew E, Lee S, Hirens P, Levy CF, Goldfisher R, Amodio J. Pediatric peritoneal epithelial malignant mesothelioma case report. *Case Rep Radiol* 2021;**2021**:1–7. <https://doi.org/10.1155/2021/5581757>.
- Vermersch S, Arnaud A, Orbach D, Andre N, Berger C, Kepenekian V, et al. Multicystic and diffuse malignant peritoneal mesothelioma in children. *Pediatr Blood Cancer* 2020;**67**:e28286. <https://doi.org/10.1002/xbc.28286>.
- Kashanskiy SV, André N, Andre N. Paediatric mesothelioma: is there such a disease? *Bull Cancer* 2010;**97**:571–6. <https://doi.org/10.1684/bdc.2010.1064>.
- Robinson BW, Lake RA. Advances in malignant mesothelioma. *N Engl J Med* 2005;**353**:1591–603. <https://doi.org/10.1056/NEJMra050152>.
- Liu S, Staats P, Lee M, Alexander HR, Burke AP. Diffuse mesothelioma of the peritoneum: correlation between histological and clinical parameters and survival in 73 patients. *Pathology* 2014;**46**:604–9. <https://doi.org/10.1097/PAT.000000000000181>.
- Attanoos RL, Churg A, Galateau-Salle F, Gibbs AR, Roggli VL. Malignant mesothelioma and its non-asbestos causes. *Arch Pathol Lab Med* 2018;**142**:753–60. <https://doi.org/10.5858/arpa.2017-0365-RA>.
- Coffin CM, Dehner LP. Mesothelial and related neoplasms in children and adolescents: a clinicopathologic and immunohistochemical analysis of eight cases. *Pediatr Pathol* 1992;**12**:333–47. <https://doi.org/10.3109/15513819209023314>.
- Cooper SP, Fraire AE, Buffler PA, Greenberg SD, Langston C. Epidemiologic aspects of childhood mesothelioma. *Pathol Immunopathol Res* 1989;**8**:276–86. <https://doi.org/10.1159/000157156>.
- Fraire AE, Cooper S, Greenberg SD, Buffler P, Langston C. Mesothelioma of childhood. *Cancer* 1988;**62**:838–47. [https://doi.org/10.1002/1097-0142\(19880815\)62:4<838::AID-CNCR2820620433>3.0.CO;2-9](https://doi.org/10.1002/1097-0142(19880815)62:4<838::AID-CNCR2820620433>3.0.CO;2-9).
- Sugalski A, Davis M, Prasannan L, Saldivar V, Hung JY, Tomlinson GE. Clinical, histologic, and genetic features of mesothelioma in a 7-year-old child. *Pediatr Blood Cancer* 2013;**60**:146–8. <https://doi.org/10.1002/xbc.24284>.
- Wolff-Bar M, Dujovny T, Vlodavsky E, Postovsky S, Morgenstern S, Braslavsky D, et al. An 8-year-old child with malignant deciduoid mesothelioma of the abdomen: report of a case and review of the literature. *Pediatr Dev Pathol* 2015;**18**:327–30. <https://doi.org/10.2350/14-06-1511-CR.1>.
- Tsai LY, Yang YL, Lu MY, Lin DT, Huang HY, Lin KH. Deciduoid mesothelioma of the pleura in an adolescent boy. *Pediatr Hematol Oncol* 2010;**27**:132–7. <https://doi.org/10.3109/08880010903447359>.
- Brecht IB, Agaimy A, Besendorfer M, Carbon R, Thiel FC, Rompel O, et al. Malignant peritoneal mesothelioma in a 16-year-old girl: presentation of a rare disease. *Klin Padiatr* 2012;**224**:170–3. <https://doi.org/10.1055/s-0032-1308987>.
- Oberto C, Schwarz KB, Zambidis E, Campbell AB, Paidas C, Lindyberg K, et al. Malignant peritoneal mesothelioma in a pediatric patient mimicking inflammatory bowel disease. *Dig Dis Sci* 2004;**49**:434–7. <https://doi.org/10.1023/B:DDAS.0000020498.50909.54>.
- Rodriguez D, Cheung MC, Housri N, Koniaris LG. Malignant abdominal mesothelioma: defining the role of surgery. *J Surg Oncol* 2009;**99**:51–7. <https://doi.org/10.1002/jso.21167>.
- DeSantis CE, Kramer JL, Jemal A. The burden of rare cancers in the United States. *CA Cancer J Clin* 2017;**67**:261–72. <https://doi.org/10.3322/caac.21400>.
- Joseph NM, Chen YY, Nasr A, Yeh I, Talevich E, Onodera C, et al. Genomic profiling of malignant peritoneal mesothelioma reveals recurrent alterations in epigenetic regulatory genes BAP1, SETD2, and DDX3X. *Mod Pathol* 2017;**30**:246–54. <https://doi.org/10.1038/modpathol.2016.188>.
- Argani P, Lian DWQ, Agaimy A, Metzler M, Wobker SE, Matoso A, et al. Pediatric mesothelioma with ALK fusions: a molecular and pathologic study of 5 cases. *Am J Surg Pathol* 2021;**45**:653–61. <https://doi.org/10.1097/PAS.0000000000001656>.
- Murumagi A, Ungureanu D, Arjama M, Butzow R, Lohi J, Sariola H, et al. STRN-ALK rearranged pediatric malignant peritoneal mesothelioma - functional testing of 527 cancer drugs in patient-derived cancer cells. *Transl Oncol* 2021;**14**:101027. <https://doi.org/10.1016/j.tranon.2021.101027>.

20. Mijalovsky A, Halperin D, Perez Y, Zafarov B, Shaco-Levy R, Kapelushnik J, et al. Malignant peritoneal mesothelioma in an infant with familial ATM mutations. *J Pediatr Hematol Oncol* 2018;**40**:e511–5. <https://doi.org/10.1097/MPH.0000000000001294>.
21. Sakata S, Rees H, Parke S, Carr NJ, Kostadinov D, Ahmadi N, et al. Complete pathological response after ceritinib for anaplastic lymphoma kinase-rearranged epithelioid peritoneal mesothelioma. *ANZ J Surg* 2021;**91**:475–6. <https://doi.org/10.1111/ans.16487>.
22. Olmedilla G, Undaondo C, Vasquez W, Rodriguez N. Metastatic malignant peritoneal mesothelioma mimicking an autoinflammatory syndrome in a 12-year-old boy. *Pediatr Dev Pathol* 2021;**24**:478–83. <https://doi.org/10.1177/10935266211008438>.
23. Ren H, Rassekh SR, Lacson A, Lee CH, Dickson BC, Chung CT, et al. Malignant mesothelioma with EWSR1-ATF1 fusion in two adolescent male patients. *Pediatr Dev Pathol* 2021;**24**:570–4. <https://doi.org/10.1177/10935266211021222>.
24. Mian I, Abdullaev Z, Morrow B, Kaplan RN, Gao S, Miettinen M, et al. Anaplastic lymphoma kinase gene rearrangement in children and young adults with mesothelioma. *J Thorac Oncol* 2020;**15**:457–61. <https://doi.org/10.1016/j.jtho.2019.11.011>.
25. Offin M, Yang SR, Egger J, Jayakumaran G, Spencer RS, Lopardo J, et al. Molecular characterization of peritoneal mesotheliomas. *J Thorac Oncol* 2022;**17**:455–60. <https://doi.org/10.1016/j.jtho.2021.09.012>.
26. Takeda M, Kasai T, Enomoto Y, Takano M, Morita K, Nakai T, et al. Comparison of genomic abnormality in malignant mesothelioma by the site of origin. *J Clin Pathol* 2014;**67**:1038–43. <https://doi.org/10.1136/jclinpath-2014-202465>.
27. Hung YP, Dong F, Watkins JC, Nardi V, Bueno R, Dal Cin P, et al. Identification of ALK rearrangements in malignant peritoneal mesothelioma. *JAMA Oncol* 2018;**4**:235–8. <https://doi.org/10.1001/jamaoncol.2017.2918>.
28. Guo Z, Shen L, Li N, Wu X, Wang C, Gu Z, et al. Aurora kinase a as a diagnostic and prognostic marker of malignant mesothelioma. *Front Oncol* 2021;**11**:789244. <https://doi.org/10.3389/fonc.2021.789244>.
29. Wang Y, Ma C, Yang X, Gao J, Sun Z. ZNF217: an oncogenic transcription factor and potential therapeutic target for multiple human cancers. *Cancer Manag Res* 2024;**16**:49–62. <https://doi.org/10.2147/CMAR.S431135>.
30. Ugurluer G, Chang K, Gamez ME, Arnett AL, Jayakrishnan R, Miller RC, et al. Genome-based mutational analysis by next generation sequencing in patients with malignant pleural and peritoneal mesothelioma. *Anticancer Res* 2016;**36**:2331–8.
31. Christmas TI, Manning LS, Davis MR, Robinson BW, Garlepp MJ. HLA antigen expression and malignant mesothelioma. *Am J Respir Cell Mol Biol* 1991;**5**:213–20. <https://doi.org/10.1165/ajrcmb/5.3.213>.
32. Loharamtaweethong K, Puripat N, Aonjai N, Sutepvarnon A, Bandidwattanawong C. Anaplastic lymphoma kinase (ALK) translocation in paediatric malignant peritoneal mesothelioma: a case report of novel ALK-related tumour spectrum. *Histopathology* 2016;**68**:603–7. <https://doi.org/10.1111/his.12779>.