



Contents lists available at ScienceDirect

Asian Journal of Surgery

journal homepage: [www.e-asianjournalsurgery.com](http://www.e-asianjournalsurgery.com)

## Letter to Editor

## Umbilical cord hernia associated with complete evagination of the patent omphalomesenteric duct and prolapse of adjacent ileal limbs

## Keywords:

Umbilical cord hernia  
Patent omphalomesenteric duct  
Ileal prolapse

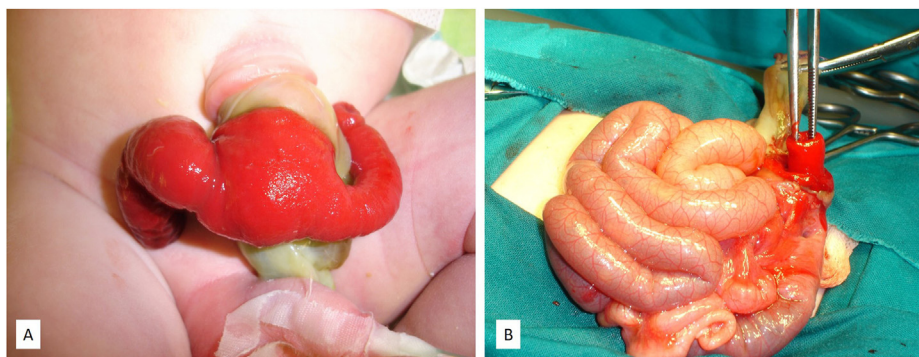
Dear Editor,

An umbilical cord hernia (UCH) [or congenital hernia of the umbilical cord (CHUC)], is a rare postnatal persistence of herniation of variable portions of the intestine into the umbilical cord. It represents normal physiological herniation in the early fetal life.<sup>1</sup> A normal insertion of the cord characterizes UCH into the umbilical ring with intact skin covering the ring. The defect diameter is < 4 cm, containing from intestinal loops to any movable intraperitoneal organs. The etiology of UCH remains unclear, but it is believed to arise from either persistent physiological mid-gut herniation or by a failure of contracture of the umbilical ring. The incidence of UCH is ~1:5000 with a male preponderance (3:1). UCH may be rarely associated with a persistent omphalomesenteric duct (POMD), Meckel's diverticulum, cloacal anomaly, type I colonic atresia, and type IIIb ileal atresia.<sup>1</sup> Clinical symptoms of UCH may vary according to the herniated contents.

A 1-day-old, full-term male newborn was referred to our hospital due to small bowel prolapse through the UCH. Prenatal ultrasonography was normal, and the baby was born from a 25-year-old mother through spontaneous vaginal delivery at 38 weeks

gestation. The Apgar scores at 1 and 5 min were 8 and 9, respectively. The birth weight was 3200 g. The family history was negative for congenital and genetic disorders. Physical examination revealed the UCH, 2.5 cm in diameter with a skin collar of 1.5 cm at its base, and the presence of complete evagination of the POMD with prolapse of adjacent ileal limbs (Fig. 1A). The prolapsed bowel was vital. Once the baby was stabilized, the surgical correction through the caudal portion of UCH was performed on the same day. After reducing the prolapsed bowel (Fig. 1B), resection of the POMD and adjacent ileum with an end-to-end anastomosis and umbilicoplasty were performed. The baby was extubated successfully on day one and started with enteral feeding the next day. Histopathological examination of the resected specimen revealed a small bowel diverticulum lined by enteric mucosa without ectopic (gastric or pancreatic) content. The postoperative course was uneventful, and the baby was discharged from the hospital on the 6th day. The patient was doing well at the 10-year follow-up.

This report highlights the importance of considering UCH in the differential diagnosis of congenital abdominal wall defects and the possible association of UCH with the POMD. UCH is a rare midline abdominal defect characterized by an intact abdominal wall, a complete umbilical ring, a presence of skin collar fold, and a sac comprising of outer amnion and inner peritoneal lining. Failure of the abdominal wall closure followed by a return of the physiologically eviscerated abdominal contents to the umbilical coelom during the fetal period causes this anomaly. Due to its poor understanding, the diagnosis of UCH may be easily missed or mis-categorized as a small omphalocele.<sup>1</sup> The management of UCH starts in the delivery room by preventing umbilical cord clamping with possible damage to its contents in any suspected abnormal



**Fig. 1.** A–B. A: Picture on presentation. Both the proximal and distal ileal limbs prolapsed through the patent omphalomesenteric duct; B: Patent omphalomesenteric duct following reduction of prolapsed ileal limbs.

<https://doi.org/10.1016/j.asjsur.2021.05.022>

1015-9584/© 2021 Asian Surgical Association and Taiwan Robotic Surgery Association. Publishing services by Elsevier B.V. This is an open access article under the CC BY-NC-ND license (<http://creativecommons.org/licenses/by-nc-nd/4.0/>).

Please cite this article as: Z. Zvizdic, E. Milisic, A. Jonuzi *et al.*, Umbilical cord hernia associated with complete evagination of the patent omphalomesenteric duct and prolapse of adjacent ileal limbs, *Asian Journal of Surgery*, <https://doi.org/10.1016/j.asjsur.2021.05.022>

thickening of the base of the umbilical cord.<sup>2</sup>

POMD is one of the rarest forms of OMD and is usually presents with a minimal but persistent discharge of intestinal contents or stool at the umbilicus. Cases of prolapsed POMD itself in UCH in the neonatal period are rarely reported.<sup>3</sup> Furthermore, an associated prolapse of the ileum through a POMD, as in our patient with UCH, is extremely rare.<sup>4,5</sup>

The UCH prognosis is excellent following early surgery, as confirmed in our case. However, familiarity and understanding of this uncommon condition could lead to timely diagnosis, proper treatment and excellent outcome.

#### Declaration of competing interest

The authors have no conflict of interest to declare.

#### Acknowledgment

The authors thank the patient's family for permitting us to report this interesting case.

#### References

1. Pal K. Congenital hernia of the umbilical cord associated with extracelomic colonic atresia and perforation of gut in a newborn. *Afr J Paediatr Surg.* 2014;11:74–76.
2. Zvizdic Z, Milisic E, Vranic S. Intestinal obstruction caused by a clamped

persistent omphalomesenteric duct in congenital hernia into the umbilical cord. *Pediatr Int.* 2021;63(5):608–609. <https://doi.org/10.1111/ped.14598>.

3. Singh S, Kaur D. *Achromobacter xylosoxidans* infection in a patient with acute leukemia: characteristics and options for antibiotic therapy for a rare highly virulent gram-negative bacterium. *Journal of Clinical Neonatology.* 2018;7:102–104.
4. Raicevic M, Filipovic I, Sindjic-Antunovic S. Hernia of the umbilical cord associated with a patent omphalomesenteric duct. *J Postgrad Med.* 2017;63:58–59.
5. Ono K, Kikuchi A, Takikawa KM, et al. Hernia of the umbilical cord and associated ileal prolapse through a patent omphalomesenteric duct: prenatal ultrasound and MRI findings. *Fetal Diagn Ther.* 2009;25:72–75.

Zlatan Zvizdic, Emir Milisic, Asmir Jonuzi  
Clinic of Pediatric Surgery, University Clinical Center Sarajevo,  
Sarajevo, Bosnia and Herzegovina

Semir Vranic\*  
College of Medicine, QU Health, Qatar University, Doha, Qatar  
Biomedical and Pharmaceutical Research Unit, QU Health, Qatar  
University, Doha, Qatar

\* Corresponding author. College of Medicine, QU Health, Qatar  
University, PO Box 2713, Doha, Qatar.  
E-mail addresses: [semir.vranic@gmail.com](mailto:semir.vranic@gmail.com), [svranic@qu.edu.qa](mailto:svranic@qu.edu.qa) (S.  
Vranic).

6 May 2021  
Available online xxx