

EMBRYONIC DEVELOPMENT OF THE OLFACTORY ORGAN IN MICE

By

M. I. MICHAEL, S. H. KHALIL and T. A. RIZK

Department of Zoology, Faculty of Science, Alexandria University, Egypt.

التطور الجنيني لعضو الشم في الفئران

ميلاد اسحق ميخائيل و شكري حبيب خليل و تهاني عبد السيد رزق

تمت دراسة التطور الجنيني لعضو الشم في المراحل الجنينية للفئران (Patch Balb/c طبيعي) . واختيرت ثمانية أطوار لهذه الدراسة وهي عمر ٩، ١٠، ١١، ١٢، ١٣، ١٤، ١٦، ١٨ يوما من فترة الحمل .

تبدأ الحرشفة الشمية في الظهور في اليوم التاسع من فترة الحمل كجزء سميك من البشرة ، وفي اليوم العاشر تظهر فتحة الأنف الداخلية الأولية حيث يتم قفلها في اليوم الحادي عشر لتكون الزعنفة الأنفية . ثم تضمحل غالبية هذه الزعنفة تدريجيا ويحل محلها خلايا ميزنشيمية فيما عدا الجزء الخلفي منها لتكون الغشاء الأنفي القمي وعنده تتكون فتحة الأنف الداخلية الثانوية في اليوم الثاني عشر .

تتبعج ثلاثية منطقة وسط الحاجز الأنفي المتوسط في اليوم الحادي عشر من فترة الحمل لتكون عضو ميكعي أنفي كلوي الشكل ، ثم ينفصل هذا العضو عن غطائه الغضروفي اليوم السادس عشر بواسطة طبقة سميكة من نسيج متكيف .

تتبعج ثلاثية جدار الأنف الجانبية مكونة صماخ أوسط كما يوجد انبعاجين من الجدار الأنفي الجانبي وهما الفجوة المصفوية والفجوة الفكية وتحتوي الأخيرة على عناصر غذية بينما لا تحتوي الأولى على هذه العناصر .

تشغل مختلف الغدد الأنفية معظم المنطقة التنفسية للجدار الأنفي وتنمو الغدد الجانبية أسرع وبطريقة مكثفة عن الغدد الوسطية للحاجز الأنفي الأوسط .

Key Words: Embryonic development, Olfactory organ, Mice, Nasal fin, Choanae, Nasal glands, Vomeronasal organ.

ABSTRACT

The development of the olfactory organ in the prenatal stages of mice (Patch/normal Balb/c) was studied. Eight stages were selected for this study; they are 9, 10, 11, 12, 13, 14, 16 and 18 days of gestation.

At 9 days of gestation, the olfactory placodes begin to appear as two thickenings of epidermis, latero-ventral to the prosencephalon. At 10 days, the primary choanae appear; each lies between the lateral and medial nasal swellings. At 11 days, the epithelia of these swellings fuse (closing the primary choanae) to form the nasal fin. This fin is mostly regressed and becomes replaced by mesenchymal cells except in its most posterior part to form the bucconasal membrane. As development proceeds and at 12 days, the secondary choanae are formed.

At 11 days, the epithelium of the middle septal region evaginates to form the vomeronasal organ which is kidney-shaped. At 16 days and thereafter, this organ becomes separated from its cartilagenous envelope by a thick layer of cavernous tissue and the vomeronasal glands appear.

At 12 days, the lateral nasal epithelium evaginates into the lateral nasal wall to form the middle meatus. In addition, and at 14

days, there are two evaginations from the lateral nasal epithelium; the ethmoidal recesses and the maxillary recesses. Unlike the maxillary recesses, the ethmoidal recesses possess no glandular elements in their submucosa.

The different nasal glands occupy most of the respiratory area. The glands of the lateral and medial nasal walls develop in a different chronological sequence. The lateral glands progress faster and more extensive than the septal glandular system.

INTRODUCTION

It is generally known that the anlage of the vertebrate olfactory organ develops as a thickening, the olfactory placode on both sides of the head. These thickenings invaginate giving rise to the olfactory pits, which progressively become deeper and extend backwards and downwards towards the nasal groove. Each nasal groove is flanked by two prominences, the medial and lateral nasal processes or swellings (as termed by Gaare & Langman, [1]). The nasomedial processes of both sides eventually merge with each other to form the medial portion of upper lip and the septum of the nose [2], while the nasolateral processes become the alae of the nose.

Trasler [3], Lejour [4] and Portois [5] mentioned that as development proceeded, the epithelia of the medial and lateral swellings fused to form the nasal fin [1, 6] or Hochstetter's membrane [7]. Gaare & Langman [1] reported that during development, this fin regressed and was replaced by mesenchyme except for its most posterior portion, which remained as the oronasal membrane. Failure of fusion between the nasal swellings on one or both side (s) causes the unilateral or bilateral cleft lip.

In the embryonic development, formation of the nasal passages follows the morphogenetic sequence: the olfactory canals eventually communicate with the stomodaeum, forming the primary choanae. Later, the elevation and fusion of the palatal shelves create the internal nares to assume a more posterior position as the secondary choanae [8, 9].

A survey on the adult morphology of the olfactory organs in adult anurans was provided by Michael [9]. Doucetter *et al.* [10] stated that the olfactory epithelium was the only part of the nervous system in the adult mammals in which neurones died and were regularly replaced. The neurones in the rat and mouse have short life spans from 30 to 40 days [11]. Basal cells divide and differentiate into receptor cells and their axons then grow to the olfactory bulb where they form synapses within glomeruli [12].

The nasal passage of mammals is divided into three regions: the vestibular, the respiratory and the olfactory regions. Adams [13] and Gross *et al.* [14] have reviewed and tabulated the anatomical informations of the nasal cavity.

The vomeronasal organ is present in amphibians, reptiles and most mammals but it is absent in birds. Harrison [15] nominated the mammals which lacked the vomeronasal organs such as the Cetacea and Sirenia (dugong and manatee) which possessed no olfactory epithelium. Members of order Proboscidae which include the two elephant species and the primitive ungulate, the (aardvark) *Orycteropus afer* possess no vomeronasal organ.

Harrison [15] also reported that in rodents the vomeronasal organ played an essential role in the control of reproduction. It is thought to be a sensor for sexual pheromones [16, 17]. Also,

the organ probably plays a role in feeding [15, 18].

The anatomical structure of the vomeronasal organ of various mammalian species has been widely studied by many authors [15, 19]. Among the authors who described the histology of this organ, one may refer to Vacarezza *et al.* [20], Taniguchi & Mochizuki [21, 22], Adams & Niekamp [23]. However, studies on the organ's histogenesis during its development are very few. Among those authors so far known Vidic *et al.* [24], Garrosa *et al.* [25] worked on rat and Taniguchi & Mochizuki [21] on hamster.

Concerning the nasal glands, their structure and distribution have been studied in the rat and in a number of other mammals: [26], in the mouse [27] in the hamster [28], in the pig [29], in the dog [30, 31] and in marsupials [32]. The glands are classified into three broad regional groups: glands of wide distribution, associated with types of epithelium including mucous goblet cells; glands of the lateral nasal walls and glands of the nasal septum (medial nasal glands).

The aim of this study is to investigate the embryonic development of the olfactory organ in mice. This study is pre-requisite for any future experimental studies on the olfactory organs of this species.

MATERIALS AND METHODS

The embryos were collected from mating mice of Patch strain (CBA/C₅₇ BL) with normal Balb/c mice at 9, 10, 11, 12, 13, 14, 16 and 18 days of intrauterine life. At each age, four embryos were taken from two litters.

Embryos were staged and surgically removed from the uterus [33] to be fixed in Bouin's fluid and prepared for histological studies.

RESULTS

9 days Gestation Stage: The olfactory placode (Fig. 1, OP) arises as a thickening of the epidermis, lateroventral to the prosencephalon. The placode invaginates to form the olfactory or nasal pit (Fig. 2, NP), which extends inwards and upwards creating at 10 days a deep depression, the nasal groove and the internal nasal opening or the primary choana. Each nasal groove is flanked by the medial and lateral nasal swellings.

11 days Gestation Stage: The two epithelial borders of the medial and lateral nasal swellings fuse more posteriorly. The initial contact between the cells of the medial and lateral swellings is made by short projection of epithelial cells of these opposing nasal swellings (Fig. 3a, arrow) or by the so called choanal fold as mentioned by Khalil [34]. This contact gives rise to an epithelial plate in the line of fusion, which is known as the nasal fin (Fig. 3b, NF), and transform the nasal groove into the primitive nasal cavity (PNC). Posteriorly, the nasal fin merges into

dissociated mesenchyme cells (Fig. 3c), while more posteriorly they are continued into a distinct bucconasal membrane (Fig. 3d, arrow).

Also at this stage, the epithelium of the middle septal zone evaginates into the subepithelium to form the vomeronasal organ (Fig. 4, VNO), the lumen of which is slit-like being surrounded by thick epithelium.

12 days Gestation Stage: The nasal cavity becomes expanded and its epithelium begins to be differentiated into thick vestibular, thin respiratory and olfactory epithelia. At this stage, the palates are vertical in position and the secondary choanae are formed. At the anterior level of the nasal organ, the lateral nasal epithelium evaginates into the lateral nasal wall to form the middle meatus. The nasal capsule and the intermedial septum begin to appear as a condensation of mesenchymal cells that surround the nasal organ. Also at the most anterior level, the nerve fibers (Fig. 5, ON) arise from the sensory olfactory epithelium, being directed toward the olfactory lobe (OL).

13 days Gestation Stage: At the posterior level of the nasal organ the main lateral nasal glands or the so-called Steno's gland (Fig. 6, LNG) appears as one single duct. The vomeronasal organ (Fig. 7, VNO) is kidney-shaped with its concavity laterally located. The lateral wall is thin and has smaller and densely packed cells, while the medial wall is thick and has more flattened cells. During development, the lateral wall becomes thinner gradually, while the medial wall becomes thicker (Figs. 8 & 9). Also, at this stage, the vomeronasal organ becomes surrounded medially and ventrally by condensed mesenchymal cells at a predifferentiative phase (Fig. 7).

14 days Gestation Stage: The nasal cavity is expanded and its epithelium becomes well differentiated (Fig. 10). Due to the expansion of the nasal cavity, the vomeronasal organ is displaced ventrally and communicates the nasal fossa (Fig. 10).

In addition to the presence of the well developed middle meatus (Fig. 11, MM), which opens in the vestibule, there are other evaginations from the lateral nasal epithelium. These evaginations extend parallel to the middle meatus, at a lower level posteriorly, into the nasal cavity. Dorsally, the ethmoidal meatus or recesses (Fig. 12, ER) expand posteriorly as a blind pouch. While ventrally the maxillary recesses (MR) extend in the lateroposterior direction. The posterior maxillary gland (PMG) begins to appear, in some embryos, in the submucosa of maxillary recesses as one or two ducts that may increase in number during development (Figs 13 & 14).

The main lateral nasal gland, which appeared at the posterior level of the nasal organ in the previous stage, extends anteriorly as well as posteriorly to form the future long anterior and short postero-lateral nasal glands respectively (Fig. 11). In addition, there is a small excretory duct in the interseptal sub-epithelium which is known as anterior medial gland of the nasal septum or the anterior septal gland (ASG).

The nasolacrimal duct (Fig. 11, NLD) is faintly delimited at the ventral border of the nasal capsule. During development, this duct ramifies into several acini, extending latero-dorsally

(Fig. 15). The nasal capsule and the internasal septum become cartilagenous, while the nasoturbinates and maxilloturbinate remain mesenchymatous.

16 days Gestation Stage : The vestibule extends rostrally till it opens to the outside forming the external nasal opening (Fig. 16, arrow), which contains the mucous and horny materials. The respiratory epithelium becomes ciliated and well differentiated with many goblet cells. The vomeronasal organ (Fig. 9) is still kidney-shaped and its concavity facing laterally. The medial wall is thick, while the lateral wall is thin and its cellular rows become progressively reduced during development. The mesenchymal tissue that surround the medial and ventral part of the vomeronasal organ becomes well differentiated to form the semi circular cartilage or the so called vomeronasal cartilage (Fig. 15, VC).

From this stage and thereafter, the vomeronasal organ becomes separated from its cartilaginous envelope (Fig. 17) by a large thick layer of cavernous tissue (see Vidic *et al.*, 1972). Also the nasoturbinates and maxilloturbinate become completely chondrified. The posterior maxillary glands open into the epithelium of the maxillary recesses.

DISCUSSION

During the embryonic development of the mammalian olfactory organ, the mesenchymal tissue which surrounds the nasal pits proliferates rapidly, so that the pits are deepened both, by their own progressive invagination and by forward growth of the surrounding rostral region.

In the present study it was found that as development proceeds, the epithelia of the medial and lateral nasal swellings fuse to form the nasal fin at the 11th day of gestation. This finding coincides with that of Trasler [3], Lejour [4], Pourtois [5] and Gaare & Langman [1, 6]. Shortly after its formation, the nasal fin mostly regresses and is replaced by mesenchyme, with the exception of its most posterior part which remains as the bucconasal membrane. This region is characterized by the presence of a large amount of degenerated cells, which was considered as the "cell death zone" [1, 6]. These findings are concordant with those of Gaare & Langman [1, 6] on the mouse.

It had been shown above that the nasal glands occupy most of the respiratory area of the nasal organ. The glands which are related to the lateral nasal wall and to the maxillary sinus appear as early as the 14 days gestation stage in mice embryos. This finding agrees with that of Vidic [35] and Evans [30]. However, the anterior and posterior medial glands appear in later prenatal stages; a finding that coincides with that of Vidic *et al.* [24] and Garrosa *et al.* [25].

The structure of the vomeronasal complex includes the vomeronasal organ, the underlying connective tissue, the vomeronasal glands, nerves and blood supply. In the present study, it was found that the first sign of the developing vomeronasal organ appears by 11 days gestation. This age is considerably much earlier than the one described by Vidic *et al.* [24] and Garrosa *et al.* [25] in rat and by Taniguchi & Mochizuki [21] in hamster.

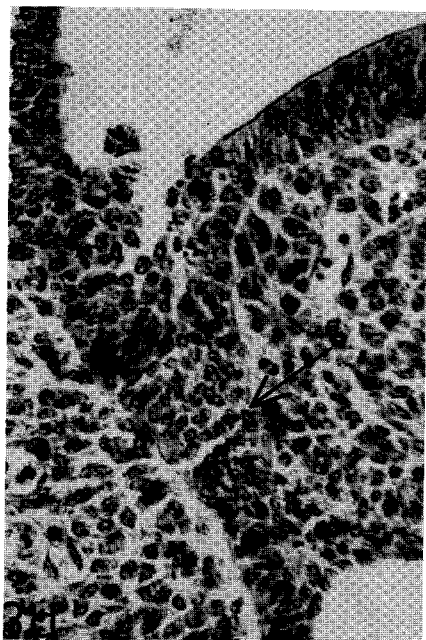
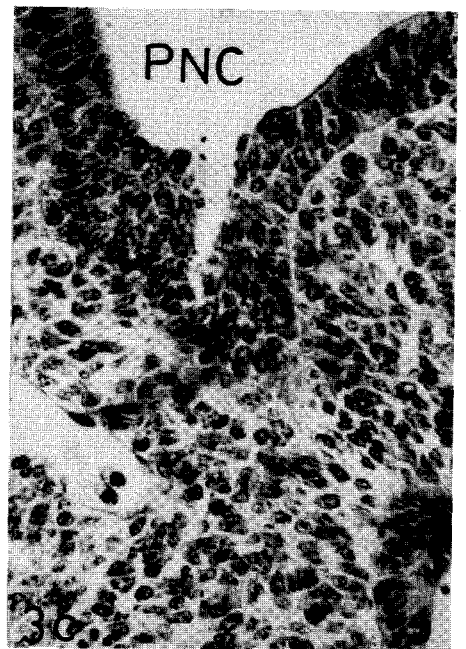
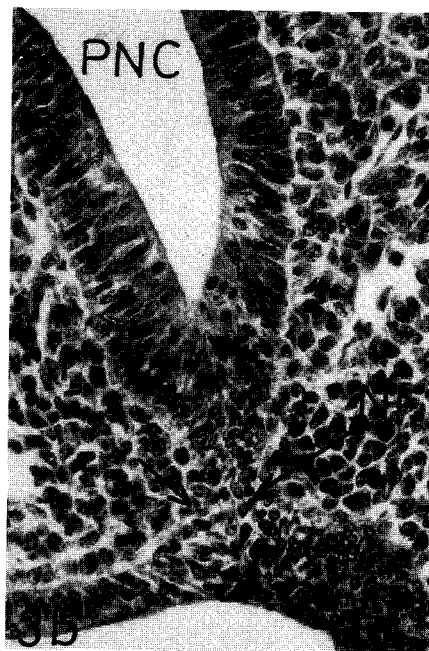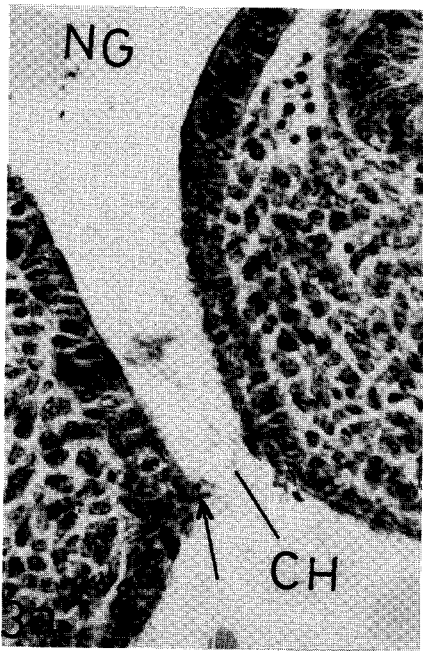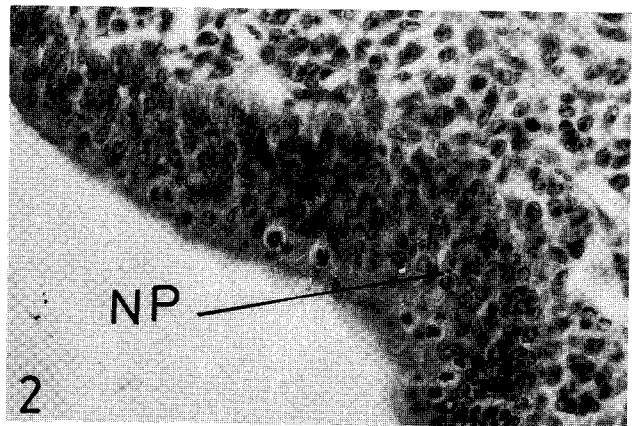
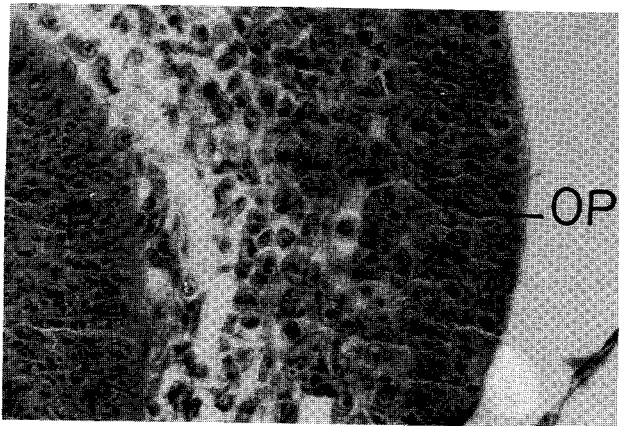


Fig. 1: A photomicrograph of a transverse section of the mouse embryo at 9 days, showing the olfactory placode (OP). H-E stain, X 200.

Fig. 2: A photomicrograph of a transverse section of the mouse embryo at 9 days showing the nasal pit (NP). H-E stain, X 200.

Fig. 3: Series of transverse sections from anterior to posterior through the nasal region of 11 days gestation stage mouse embryo to demonstrate the sequence in the fusion process between the medial and lateral nasal swellings (closure of the primary choana). H-E stain, X 200.

- (a) Prior to the epithelial contact of the medial and lateral nasal swellings in the nasal groove.
- (b) Contact between the epithelial linings of the nasal swellings had produced the nasal fin (NF) and primitive nasal cavity (PNC).
- (c) The nasal cavity is replaced by mesenchyme.
- (d) The nasal fin, in the most posterior part of the primitive nasal cavity, remains as the buconasal membrane (arrow).

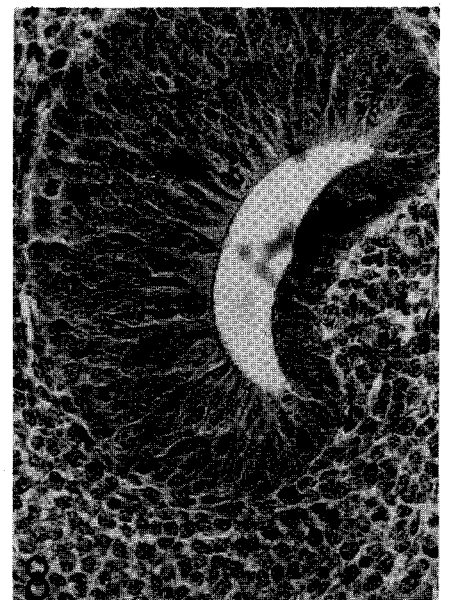
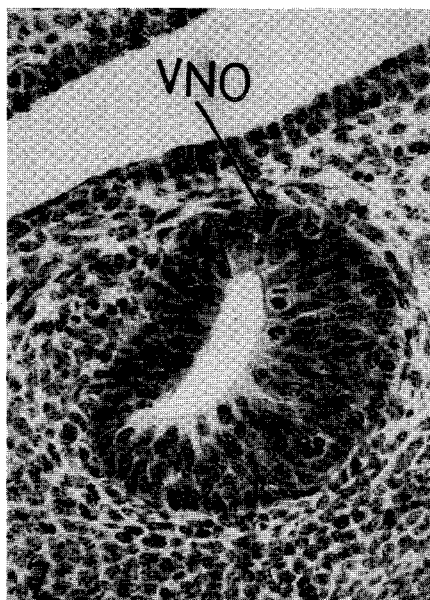
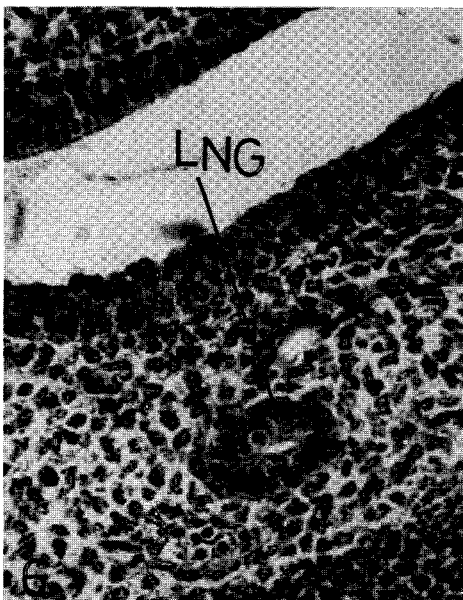
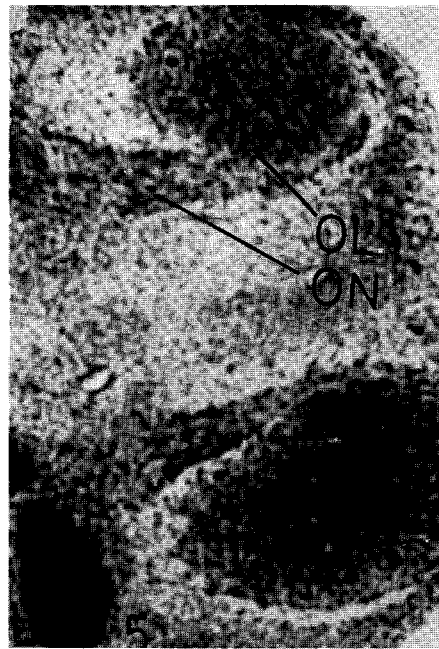
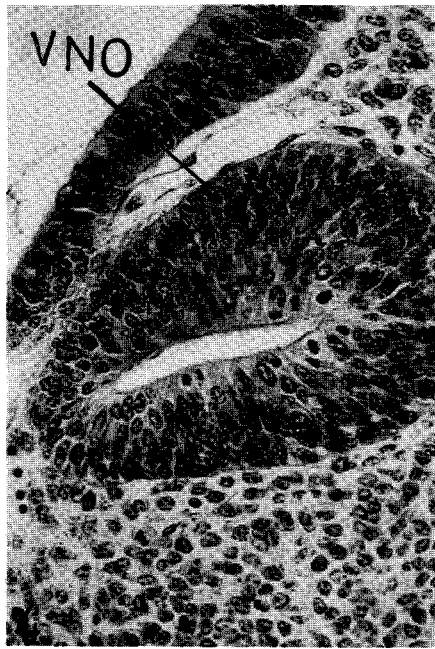


Fig. 4: A photomicrograph of a transverse section of the mouse embryo at 11 days, showing the vomeronasal organ (VNO). H-E stain, X 200.

Fig. 5: A photomicrograph of a transverse section of the mouse embryo at 12 days, showing the nerve bundles from the olfactory organ directed to the olfactory lobe. H-E stain, X 200.

Fig. 6: A photomicrograph of a transverse section of the mouse embryo at 13 days, showing the lateral nasal gland (LNG). H-E stain, X 200.

Fig. 7: A photomicrograph of a transverse section of the mouse embryo at 13 days, showing the vomeronasal organ. H-E stain, X 200.

Fig. 8: A photomicrograph of a transverse section through the nasal region of the mouse embryo at 14 days, showing the vomeronasal organ (VNO). H-E stain, X 200.

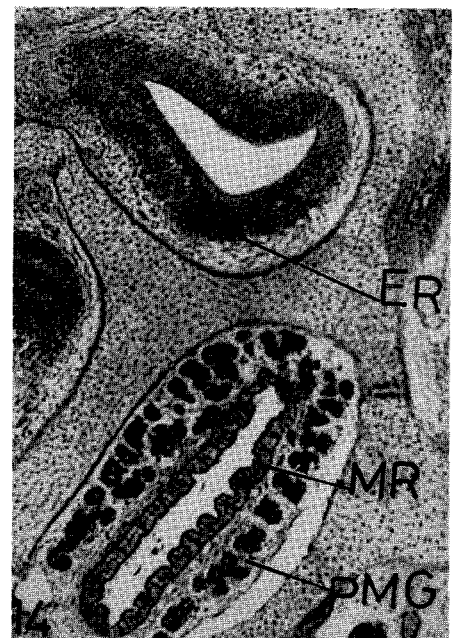
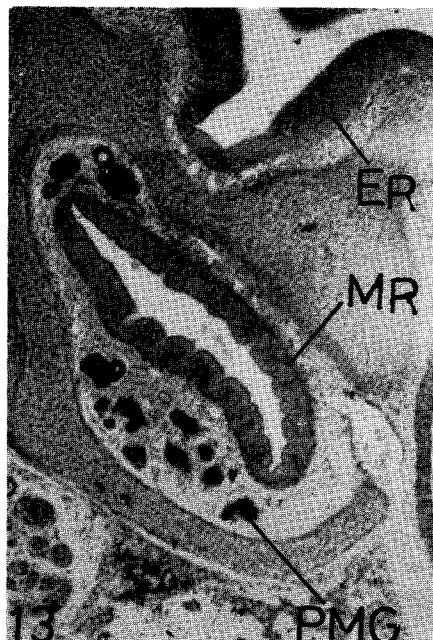
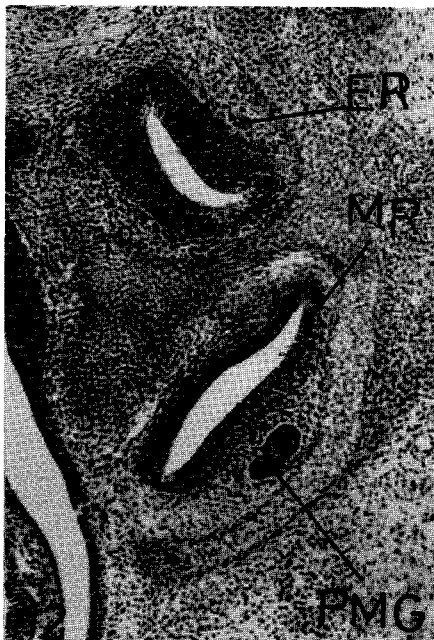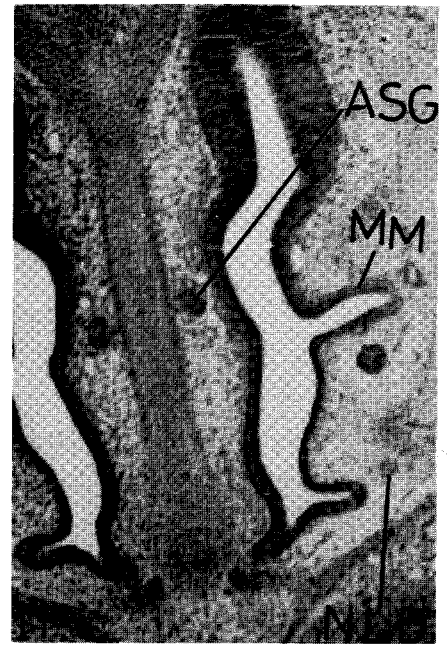
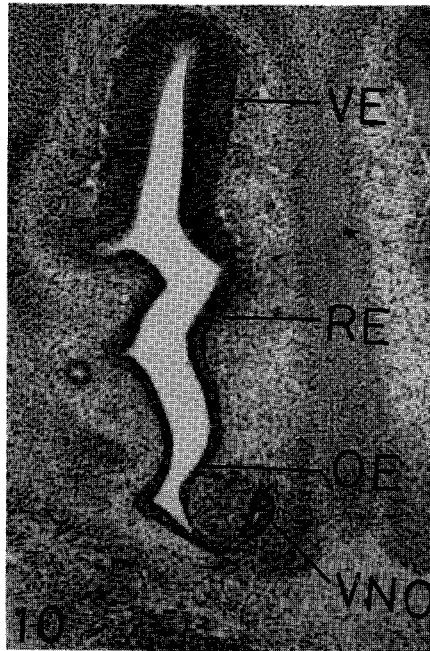
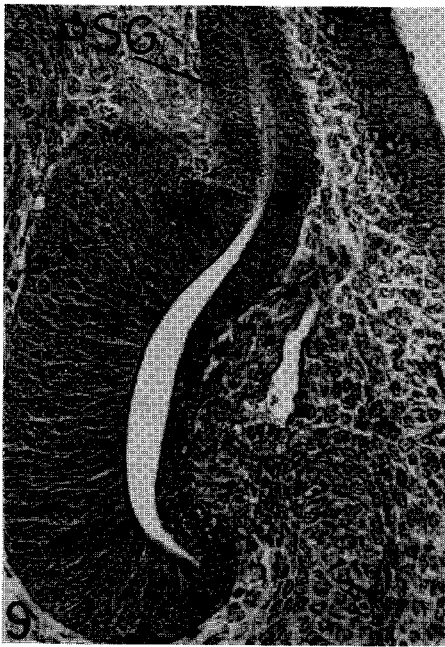


Fig. 9: A photomicrograph of a transverse section through the nasal region of the mouse embryo at 16 days, showing the vomeronasal organ. H-E stain, X 200.

Fig. 10: A photomicrograph of a transverse section through the nasal region of the mouse embryo at 14 days, showing the connection between the nasal fossa and the vomeronasal cavity. H-E stain, X 200.

Fig. 11: A photomicrograph of a transverse section through the nasal region of the mouse embryo at 14 days, showing the anterior septal gland (ASG) and the nasalacral duct (NLD). H-E stain, X 200.

Fig. 12: A photomicrograph of a transverse section through the nasal region of the mouse embryo at 14 days, showing the ethmoidal (ER) and maxillary recesses (MR). H-E stain, X=50.

Fig. 13: A photomicrograph of a transverse section through the nasal region of the mouse embryo at 16 days, showing the maxillary recesses with associated posterior maxillary glands (PMG). H-E stain, X=50.

Fig. 14: A photomicrograph of a transverse section through the nasal region of the mouse embryo at 18 days, showing ethmoidal (ER) and maxillary recesses (MR) with posterior maxillary glands (PMG). H-E stain, X=50.

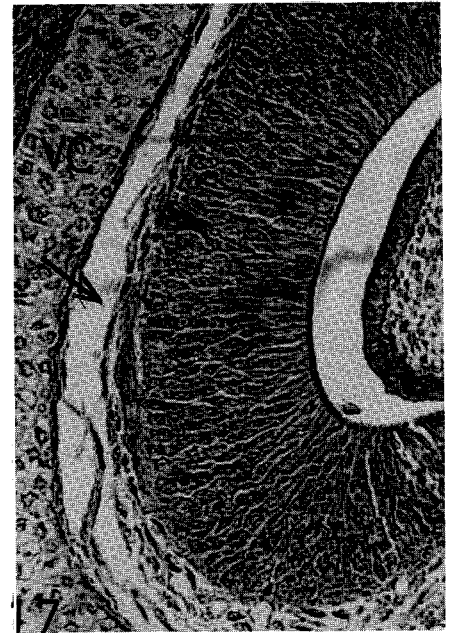
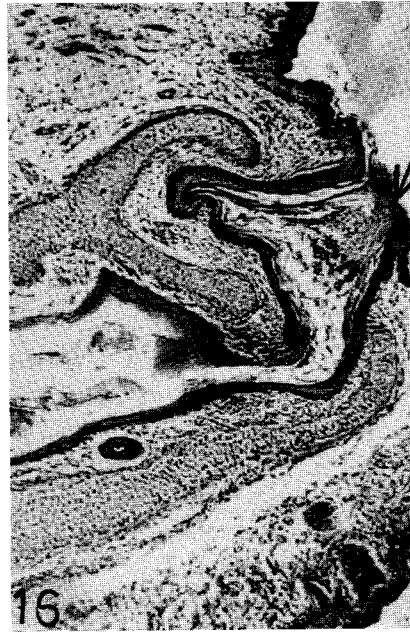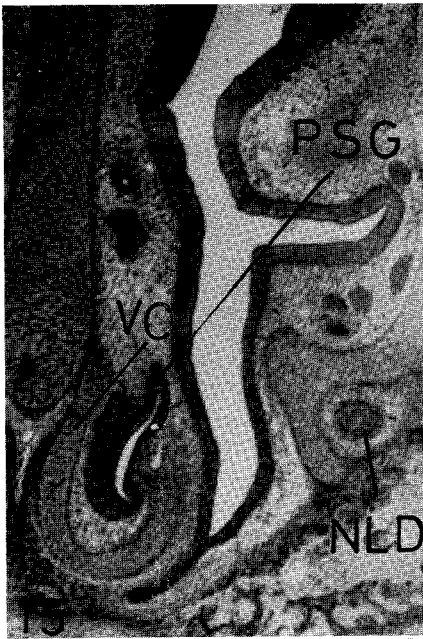


Fig. 15: A photomicrograph of a transverse section through the nasal region of the mouse embryo at 16 days, showing the posterior septal gland (PSG) and vomeronasal cartilage (VC). H-E stain, X=50.

Fig. 16: A photomicrograph of a longitudinal section through the head region of the mouse embryo at 16 days, showing the external nasal opening (arrow). H-E stain, X=200.

Fig. 17: A photomicrograph of a transverse section through the nasal region of the mouse embryo at 18 days, showing the cavernous tissue (arrow). H-E stain, X=200.

At late embryonic stages, a thick layer of cavernous tissue which intervenes between the cartilagenous envelope and the vomeronasal organ was regarded as a regulator of inspiration and expiration by Negus [36].

In the present study it was found that the vomeronasal organ of mice communicates with the nasal fossa and opens directly into the nasal passage. This finding agrees with that of Vidic *et al.* [24], Garrosa *et al.* [25] and Kratzing & Woodall [37]. On the other hand, the vomeronasal organ communicates directly with the oral cavity in cow and hippopotamus [38], in marsupials [37] and in the insectivore *Hemiechinus auritus* [39].

ABBREVIATIONS

ASG: Anterior septal glands; CH: Primary choana; ER: Ethmoidal recesses; LNG: Lateral nasal gland; MM: Middle meatus; MR: Maxillary recesses; NF: Nasal fin; NG: Nasal groove; NLD: Nasolacrimal duct; NP: Nasal pit; OE: Olfactory epithelium; OL: Olfactory lobe; OP: Olfactory lobe; ON: Olfactory nerve; P: Prosencephalon; PMG: Posterior maxillary gland; PNC: Primitive nasal cavity; PSG: Posterior septal gland; RE: Respiratory epithelium; VC: Vomeronasal cartilage; VE: Vestibular epithelium; VNO: Vomeronasal organ.

REFERENCES

- [1] Gaare, J. D. and J. Langman, 1977. Fusion of nasal swellings in the mouse embryo: Regression of the nasal fin, *Amer. J. Anat.*, 150:477-500.
- [2] de Beer, G. R., 1937. The development of the Vertebrate Skull. London.
- [3] Trasler, D. G., 1968. Pathogenesis of cleft lip and its relation to embryonic face shape in A/J and C₅₇BL mice, *Teratology*, 1:33-50.
- [4] Lejour, M., 1970. Cleft lip induced in the rat, *Cleft palate J.*, 7:169-186.
- [5] Pourtois, M., 1972. Morphogenesis of the primary and secondary palate. In: 'Development Aspects of Oral Biology'. (H. S. Slavkin and L. A. Bavetta, eds), Academic press, New York.
- [6] Gaare, J. D. and J. Langman, 1977. Fusion of nasal swellings in the mouse embryo: Surface coat and initial contact, *Amer. J. Anat.*, 150:461-476.
- [7] Tamarin, A., 1982. The formation of the primitive choanae and the junction of the primary and secondary palates in the mouse. *Amer. J. Anat.*, 165:319-337.
- [8] Hyman, L. H., 1942. Comparative Vertebrate Anatomy. Univ. Chicago Press. Chicago.
- [9] Michael, M. I. 1961: The morphology of the olfactory organs of the Egyptian toad, *Bufo regularis* Reuss, *J. Morph.*, 109:1-18.
- [10] Doucette, J. R., J. A. Keirnan, and B. A. Flumerfelt, 1983. Two different patterns of retrograde degeneration in the olfactory epithelium following transection of primary olfactory axons, *J. Anat.*, 136:673-689.
- [11] Graziadei, P. P. and G. A. Monti Graziadei, 1979. Neurogenesis and neuron regeneration in the olfactory system of mammals. I. Morphological aspects of differentiation and structural organization of the olfactory sensory neurons, *J. Neurocytology*, 8:1-18.
- [12] Patten, B. A. and B. M. Carlson, 1974. *Foundation to Embryology*. Third ed. McGraw-Hill Book Comp., New York.
- [13] Adams, D. R., 1972: Olfactory and non-olfactory epithelia in the nasal cavity of the mouse, *Peromyscus*, *Amer. J. Anat.*, 133:35-50.
- [14] Gross, E. A., J. A., Swenberg, S. Fields and J. A. Popp, 1982. Comparative anatomy of the nasal cavity in rats and mice, *J. Anat.*, 135:83-88.
- [15] Harrison, D., 1987. Preliminary thoughts on the incidence, structure and function of the mammalian vomeronasal organ, *Acta Otolaryngol.* (Stockh), 103:489-495.
- [16] Estes, R. O., 1972. The role of the vomeronasal organ in mammalian reproduction, *Mammalia*, 36:315-341.
- [17] Jarvis, J. U., 1981. Eusociality in a mammal: cooperative breeding in naked mole rat colonies, *Science*, 212:571-573.
- [18] Cooper, J. G. and K. P. Bhatnagar, 1976. Comparative anatomy of the vomeronasal organ in bats, *J. Anat.*, 122:571-601.
- [19] Wöhrman-Repenning, A., 1984. Phylogenetische Aspekte zur Topographie der Jacobsenschen Organe und der Ductus nasopalatini bei Insectivora, Primates, Tupaia und Didelphis, *Anat. Anz.*, 157:137-149.
- [20] Vacarezza, O. L., L. N. Sepich, and J. H. Tramezzani, 1981. The vomeronasal organ of the rat, *J. Anat.*, 132:167-185.
- [21] Taniguchi, K. and K. Mochizuki, 1982. Developmental studies on the vomeronasal organ in the golden hamster, *Jpn. J. Vet. Sci.*, 44:709-716.
- [22] Taniguchi, K. and K. Mochizuki, 1983. Comparative morphological studies on the vomeronasal organ in rats, mice and rabbits, *Jpn. J. Vet. Sci.*, 45:67-76.
- [23] Adams, D. R. and M. D. Wiekamp, 1984. The canine vomeronasal organ, *J. Anat.*, 138:771-787.
- [24] Vidic, B., H. G. Greditzer and W. J. Litchy 1972. The structure and prenatal morphogenesis of the nasal septum in the rat, *J. Morph.*, 137:131-148.
- [25] Garrosa, M., S. Coca and O. A. Mora, 1986. Histological development of the vomeronasal complex in the pre- and postnatal rat, *Acta Otolaryngol.* (Stockh), 102:291-301.
- [26] Bojsen-Moller, F., 1964. Topography of the nasal glands in rats and some other mammals, *Anat. Rec.*, 150:11-24.

- [27] **Cushieri, A. and L.H. Bannister, 1974.** Some histochemical observations on mucosubstances of nasal glands of the mouse, *Histochem. J.*, 6:543-558.
- [28] **Adams, D. R., 1982.** Hamster nasal glands: their structure, sialic acid content and vulnerability to actinomycin D. *J. Morph.*, 174:79-94.
- [29] **Bojsen-Moller, F., 1967.** Topography and development of the anterior nasal glands in pigs, *J. Anat.*, 101:321-331.
- [30] **Evans, H. E. 1977.** Topography of the lateral nasal gland and its duct in the dog, *Anat. Rac.*, 187:574-575.
- [31] **Adams, D. R., D. W. Deyoung and R. Griffith, 1981.** The lateral nasal gland of dog: its structure and secretory content, *J. Anat.*, 132:29-37.
- [32] **Kratzing, J. E., 1984.** The structure and distribution of nasal glands in four marsupial species, *J. Anat.*, 139:553-564.
- [33] **Michael, M. I., S. H. Khalil, C. A. Matta and T. A. Rizk, 1987.** Normal development of the prenatal mouse eye, *Folia Morph.*, 35:228-236.
- [34] **Khalil, S. H., 1978.** Development of the olfactory organ of the Egyptian toad, *Bufo regularis* Reuss, *Folia Morph.*, 26:69-74.
- [35] **Vidic, B., (1971):** The prenatal morphogenesis of the lateral nasal wall in the rat (*Mus rattus*), *J. Morph.*, 133:303-318.
- [36] **Negus, V. E., 1956.** The organ of Jacobson, *J. Anat.*, 90:515-519.
- [37] **Kratzing, J. E. and P. F. , Woodall, 1988.** The rostral nasal anatomy of two elephant shrews, *J. Anat.*, 157:135-143.
- [38] **Ciges, M., T., Labella, M., Gayoso and G., Sanchez, 1977.** Ultrastructure of the organ of Jacobson and comparative study with olfactory mucosa, *Acta Otolaryngol.* (Stockh), 83:47-58.
- [39] **Hegazy, M. M., 1990.** A contribution to the anatomy of the vomeronasal organ of Jacobson of mammals with special reference to the insectivore *Hemiechinus auritus* (Gmelin), *Proc. Zool. Soc. A. R. Egypt*, 19:33-50.