



# Resin bonded bridges in patients with hypodontia: Clinical performance over a 7 year observation period

Lamyia Anweigi<sup>a,b,\*</sup>, Ambreen Azam<sup>b</sup>, Cristiane de Mata<sup>c</sup>, Ebtissam AlMadi<sup>d</sup>, Samar Alsaleh<sup>e</sup>, Alhanooof Aldegheishem<sup>b</sup>

<sup>a</sup> College of Dental Medicine, QU Health, Qatar University, Doha, Qatar

<sup>b</sup> Department of Clinical Dental Sciences, Princess Nourah Bint Abdul Rahman University, Riyadh, Saudi Arabia

<sup>c</sup> Restorative Dentistry, Cork University Dental school and hospital, University College Cork, Ireland

<sup>d</sup> Department of Restorative Dental Sciences, King Saud University, Riyadh, Saudi Arabia

<sup>e</sup> Department of Prosthodontics, College of Dentistry, King Saud University, Riyadh, Saudi Arabia

Received 29 April 2019; revised 27 October 2019; accepted 29 October 2019

Available online 11 December 2019

## KEYWORDS

Resin-bonded bridge (RBB);  
Hypodontia

**Abstract Purpose:** Resin bonded bridges (RBBs) are considered a conservative option in the management of hypodontia. This study targeted to analyze the survival of resin bonded bridges provided to patients with Hypodontia by staff and students at the Department of Restorative Dentistry, University Dental School and Hospital Cork, Ireland. It was also to determine the factors that may influence the survival of RBBs in patients with hypodontia.

**Methods:** Forty patients with hypodontia who received 65 RBBs from 2001 to 2007 were identified and contacted to be recruited for this study. Of these, nine were not contactable, and five failed to attend. Accordingly, 26 patients (65%) participated in the study, with a total of 51 RBBs.

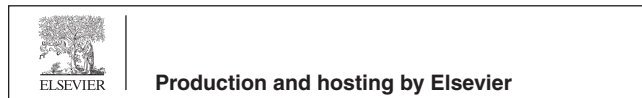**Results:** Of the 51 RBBs evaluated, 44 (86%) were still in situ and functional and 7 (14%) failed. The main reason for failure was repeated debonding. The effect of age, gender, the grade of operator and experience, bridge location, design of the bridge, span length and moisture control during cementation, could not be demonstrated.

**Conclusion:** The effect of age, gender, the grade of operator and experience, bridge location, design of the bridge, span length and moisture control on RBB survival could not be demonstrated. Majority of patients with hypodontia showed satisfaction with resin bonded bridges. In replacing congenitally missing teeth in patients with hypodontia, resin-bonded bridges would be an acceptable treatment option.

© 2019 The Authors. Production and hosting by Elsevier B.V. on behalf of King Saud University. This is an open access article under the CC BY-NC-ND license (<http://creativecommons.org/licenses/by-nc-nd/4.0/>).

\* Corresponding author at: Department of Clinical Dental Science, Princess Nourah Bint Abdul Rahman University, Riyadh, Saudi Arabia.  
E-mail address: [lmanweigi@pnu.edu.sa](mailto:lmanweigi@pnu.edu.sa) (L. Anweigi).

Peer review under responsibility of King Saud University.



## 1. Introduction

The treatment of patients with congenitally missing teeth or hypodontia requires a multidisciplinary team approach to provide the best functional, phonetic and aesthetic outcome (Lauwers et al., 2009).

The management options for patient with hypodontia range from no treatment and accepting the space (Jepson et al., 2003), to orthodontically closing (Shroff et al., 1996; Robertsson and Mohlin, 2000), or opening the space and maintaining or redistributing spaces for replacement (Carter et al., 2003). The management is influenced by the patient's choice, age and expectations. Other factors as the type of occlusion, level of malocclusion, aesthetic requirements, the presence of any soft tissue defects, and the psychological status of the patient (Meechan et al., 2003, Nunn et al., 2003, Hobkirk et al., 2006).

Resin bonded bridges are a conservative option for the restoration of missing teeth. Studies reported the long-term success of well-planned RBBs in non-hypodontia patients (Djemal et al., 1999; Hill et al., 2009). An 88% survival rate after five years was reported in a clinical trial (Creugers et al., 1997) and a meta-analysis (Pjetursson et al., 2008).

The selected abutment/s should be un-restored and modified with minimal preparation retentive features (grooves, full lingual/palatal wrap around and occlusal or cingulum rest) (Creugers et al., 1998; De Kanter et al., 1998). However, a modified tooth preparation did not improve the survival of resin-bonded bridges in a meta-analysis (Verzijden et al., 1994), while another meta-analysis indicated minimal preparation improves longevity (Pjetursson, et al. 2008). Two-unit cantilevered resin bonded bridges reported a better success than resin bonded bridges with fixed-fixed design in non-hypodontia patients (Botelho et al., 2000). Moisture control and parafunctional activity and the operator's experience seem to affect the success of resin-bonded bridges (Briggs et al., 1996; Hussey and Linden 1996; Ibbetson, 2004; Audenino et al., 2006).

In hypodontia patients, teeth are often smaller, with a relatively small surface area for bonding. The data related to RBB survival may not accurately reflect the situation in patients with hypodontia. However, in a recent prospective study, RBBs for patients with hypodontia, who were followed for up to 24 months, with recall visits at 6, 12 and 24 months; 63 out of 65 bridges were still in function, satisfying the criteria for success and survival (Allen et al., 2016).

The objective of this retrospective study was to evaluate the long-term survival of resin bonded bridges in patients with hypodontia. It was also to determine factors that may influence the survival of RBBs and satisfaction with treatment in hypodontia patients.

## 2. Materials and methods

Patients with congenitally missing teeth who received resin bonded bridges at Cork Dental School and Hospital, Ireland between 2001 and 2007 were contacted and invited to participate in the study. The study protocol was reviewed and approved by the Clinical Research Ethics Committee of the Cork Teaching Hospitals, Republic of Ireland. All participants

gave informed consent, and patient confidentiality was strictly observed.

### 2.1. Participant selection

The inclusion criteria were patients with hypodontia who received resin bonded bridges to restore missing teeth at Cork University Dental School and Hospital, Ireland. Patients were invited to participate between 2007 and 2008 for evaluation. A total of 40 eligible patients were identified and invited for a clinical review. Nine of these were not contactable, and five failed to attend. Accordingly, 26 patients (a response rate of 65%) who had been provided with a total of 51 RBBs agreed to participate in the study.

### 2.2. Data collection

A full clinical examination of abutments and contralateral control teeth were carried out and the following data recorded:

- Patient gender, age, date of bonding, span length, design and location in the arch.
- Orthodontic details; skeletal and incisor relationships, history of orthodontic treatment, type of appliance used, and if orthodontic treatment was for single or both arches and the duration of treatment. Post-orthodontic retention type of appliance and duration.
- RBB details; the design, evidence of preparation before bonding and the moisture control used.
- The number of debonds, rebonds or remakes and the reason/s for failure.
- Presence or absence of primary or secondary caries.
- Margin adaptation of the retainers.
- Occlusal assessment
- Experiences of the operator; student or senior member of staff.

The principal investigator (LA) conducted the clinical examination, calibrated against an experienced examiner, representing the gold standard, with a 100% agreement.

### 2.3. Clinical assessment of teeth & retainer adaptation criteria

The abutments and contralateral control teeth submit to the same assessment. All surfaces of abutments were examined for the presence of primary or secondary caries. Retainer margins were checked circumferentially, and this criteria for adaptation as follows:

1. All margins are closed and continuous with the tooth.
2. Clinical visual marginal gap (minor voids or defects).
3. Probe tip catches in the margin of the resin-bonded bridge.
4. Cement is clearly visible between the margin and tooth structure.

These were dichotomised into; 1 indicates the bridge that had good marginal adaptation. 2 or 3 or 4 indicate that the bridge would be considered to have inadequate marginal adaptation.

#### 2.4. Assessment of occlusal contacts

An articulating paper (GHM paper) used to indicate the position of occlusal contacts. The teeth were dried using compressed air and cotton wool roll isolation. Then the articulating paper was held in a Miller's forceps and placed between the teeth. The mandible was then guided into intercuspal position, excursive and protrusive movements to mark the points of contacts. Any signs and symptoms of pain or uneven occlusal wear, mobility or fractures, or pain on chewing were evaluated and recorded.

#### 2.5. Assessment of patient habits and satisfaction

The survey was designed to assess the presence of habits (e.g. clenching) and patients' satisfaction with the overall treatment. A Visual Analogue Scale (VAS) was used to assess patient satisfaction with the lowest score indicated extreme dissatisfaction and the highest, extreme satisfaction. To present the data, measurements on the 100 mm VAS were converted to a percentage scale.

#### 2.6. Data analysis

The data were checked manually and entered into a statistical software spreadsheet (Microsoft Excel and SPSS).

The analysis was performed using SPSS for Windows V10.0TM. "Success" was defined as the resin bonded bridge still in situ and had not debonded on more than one occasion (12). The survival time was calculated in months, from the bonding to the date of data gathering. Following data collection, the failure rate was decided to be reported descriptively. This included failed and in situ RBBs and a qualitative assessment of the effects of the different factors on bridge failure.

### 3. Results

There were 16 (62%) females and 10 (38%) males with a median age of 23 years, and age range of 17 to 34 years. The majority (69%) had one or two missing teeth (mild hypodontia), and 31% had more than four missing teeth (moderate to severe hypodontia).

The missing maxillary lateral incisor was the most common, with the symmetrical distribution. The second common was the second premolar, followed by the first premolar a small number of cases presented with congenitally missing mandibular anterior teeth, maxillary canines and first molars.

The resin bonded bridges were of the non-perforated nickel-chromium retainers design, sandblasted with 50- $\mu$ m alumina and luted with adhesive resin, PANAVIA™ 21 (Kuraray-Noritake).

51 RBBs were evaluated on 26 hypodontia patients; thirteen (50%) patients received one bridge, ten (39%) received two bridges, two (8%) received five bridges and one (3%) had eight bridges.

#### 3.1. Resin bonded bridges evaluation

At the time of evaluation, 44 (86%) bridges were still in service, 7 (14%) debonded on one occasion. There were seven

definite failures (14%) of the fifty-one bridges. The main reason for failure was debonding in at least one occasion since insertion, of which three were due to blunt trauma and four for other reasons (see Table 1).

The marginal adaptation of the retainers was deemed satisfactory with no marginal defects or voids found in the successful bridges.

#### 3.2. Duration of clinical service

The median duration of clinical service for the survival bridges was 28 months, with a 12 to 84 months range. The majority of survival bridges (41; 80%) had been in place for 12–36 months, and these were termed short service bridges. The remaining 10 (20%) had a more extended period (48–84 months) and were termed long service bridges (see Fig. 1).

#### 3.3. Factors influencing resin bonded bridge survival

##### 3.3.1. Operator experience

Thirty-five bridges were provided by undergraduate students, four by postgraduate students and 12 by staff. Bridges made by postgraduate students appeared to have had the highest survival time (see Table 2). Due to large variance in the number of cases amongst operators, the effect of the operator grade on survival cannot be demonstrated in this study.

##### 3.3.2. Orthodontic treatment

All the patients (26) received orthodontic treatment. The orthodontic treatment time ranged between 9 and 48 months, with a mean treatment time of 28 months. A removable appliance was the appliance of choice for post-orthodontic retention. The retention time ranged 3 to 24 months, with a mean duration of 13.5 months. The effects of occlusal relationship, or orthodontic treatment, or post-orthodontic retention time or post-orthodontic retention appliances, did not seem to influence survival in this study.

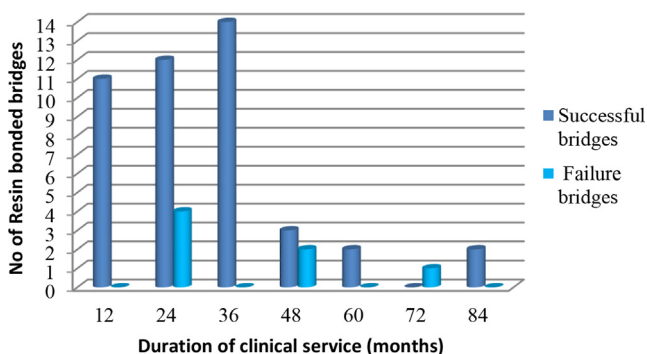
##### 3.3.3. Bridge design

Twenty-seven (53%) bridges utilized a cantilever design, while twenty-four (47%) were of the end abutments design. Of the seven failed bridges; five were cantilevered, and two were of the end abutments design.

Forty-one bridges had their details for tooth preparation documented, and three of them have failed. The remaining ten were not possible to determine if tooth preparation modification were carried out. In the other four that failed, there was no visible modified preparation carried out on the abutments.

**Table 1** Success, debonding, failure of resin-bonded bridges.

	N = 51	(%)
Survived resin-bonded bridge	44	86
Failed Resin-bonded bridge	7	14
<b>Possible reason for failure n = 7</b>		
Trauma	3	43
Other	4	57



**Fig. 1** The length of clinical service of the resin-bonded bridges.

### 3.3.4. Moisture control

The use of rubber dam was evident in 16 (31%) bridges and for the majority (35, 69%); it was not clear from the patients' records and could not be recalled by these patients. The bridges that failed were in the group that was not possible to identify if moisture control was used.

### 3.3.5. Bridge location and span

Forty-four (86%) bridges were in the anterior, seven (14%) in the posterior region. 44 (86%) were in the maxilla and 7 (14%) in the mandibular region. The success rate for the anterior maxillary bridges was 92% (33), the posterior maxillary bridges 75% (6) and the mandibular posterior bridges 71% (5).

There were 24 (47%) two-unit bridges (cantilever design), 18 (35%) three-unit bridges (resin bonded bridges with end abutments design) and 9 (18%) were four-unit bridges (resin bonded bridges with end abutments design). The bridges that were in situ at the time of data gathering were, 22 of the two unit cantilever design, 13 were three units, and 9 were four-unit bridges. In the seven that failed, two bridges were three units, and five bridges were two-units.

### 3.3.6. Pontic contact

Of the forty-four successful bridges, 38 had contact with the pontic in the intercuspal position. Twelve had contact in excursive lateral movement and 5 in protrusive movement. Twenty-nine (67%) bridges had no occlusal contact on the pontic with

one, two, or three shimstock foils. One (10%) bridge had occlusal contact on the pontic with two shimstock foils, and ten (23%) had occlusal contact with one shimstock foil.

The pain was reported around two abutments, and in 11 abutments occlusal wear was evident, and there were no mobility or fractures. The effect of the nature of pontic contact on survival cannot be demonstrated in the current study since at the time of evaluation; the failed bridges were replaced already by alternative treatment.

### 3.3.7. Patient habits and satisfaction

Seventeen (33%) bridges were placed on patients with a history of a habit; either clenching or grinding, nail-biting or pen chewing. In these patients, 100% of the RBBs were *still* in situ, and the mean and median survival times were 76.4 and 95 months. Thirty-four (67%) bridges were placed on patients with no history of a habit; 27 (79%) of these were still in situ, and 7 (21%) failed.

The VAS showed that hypodontia patients with resin-bonded bridges were generally satisfied with their treatment showing a median satisfaction rate of 90% (range from 75% to 100%).

## 4. Discussion

This retrospective study aimed to evaluate the performance of resin bonded bridges in hypodontia patients with a follow-up time of up to 7 years. One study related to the clinical performance of resin-bonded bridges in hypodontia patients, 30 bridges out of 73 debonded on at least one occasion (41.1%). The recruited hypodontia patients had only congenitally missing maxillary lateral incisors. (Garnett et al., 2006). The success rate in the current study was 86% a rate higher than that reported. The success rate was at a significantly lower rate than reported by the same group (Allen et al., 2016), at the same center. However, the Allen et al. study was more structured, since it was a prospective study. This certainly contributed to the differences in outcomes, given the controlled procedures and methodology in the delivery of the RBBs in the study.

This study has limitations; by nature of being retrospective, since it relied on the interpretation of the clinical notes.

**Table 2** Operator experience and resin-bonded bridge survival.

Length of the clinical service for successful bridges (months)	Person who inserted bridge			Total
	Staff	Undergraduate students	Postgraduate students	
12	2	9	0	11
24	5	7	0	12
36	2	10	2	14
48	0	3	0	3
60	0	0	2	2
84	0	2	0	2
<b>Total</b>	9	31	4	44
Length of the clinical service for failed bridges (months)	Staff	Undergraduate students	Postgraduate students	Total
24	3	1	0	4
48	0	2	0	2
72	0	1	0	1
<b>Total</b>	3	4	0	7

Nevertheless, some points raised were of significance to discuss. There was a 65% response rate, which may reflect patient's satisfaction with their resin bonded bridges and hence happy to attend for a review appointment. On the other hand, since the main reason for loss to follow-up was the inability to contact patients as they travelled abroad to study or work rather than non-cooperation, especially in this particular young age group. It can also be argued that the patients, who did not attend, were dissatisfied with their resin bonded bridges and may have received alternative treatment elsewhere. The sample size was relatively low, and this is generally due to the low prevalence of hypodontia and the required length of the treatment process, the multiplicity of treatment experience involved, which may lead to loss of patients. This is compounded by the fact that the patients request to participate was a long time after they received their bridges.

Females were almost 1.6 times the number of male participants, similar to other studies (Shafi, 2008; Hashem et al., 2010). The effect of age and gender on the performance of resin bonded bridges in this study did not seem to influence survival, and similar observations were reported previously (el-Mowafy and Rubo 2000; Abuzar et al., 2018). The participants in the present study were of the same age group (young group), and hence, the effect of age on bridge survival in hypodontia patients is challenging to evaluate. However, that younger patients have short clinical crowns, minimizing surface area for bonding, as well their enamel having a higher content of fluoride, might have accounted for the higher failure rate of resin bonded bridges provided in younger patients (Hansson and Bergstrom 1996; Audenino et al., 2006). This may be even more concern in hypodontia patients. The margin adaptation of the retainers for all the survived bridges was good and no void or gaps detected, like previous reports (Hansson and Bergstrom 1996; Rashid et al., 1999).

Studies reported RBBs provided by junior staff and students to have a significantly lower survival rate compared to those made by senior staff (Djemal et al., 1999; Garnett et al., 2006). The operator experience in the current study had no noticeable effect on survival due to unequal number of case distribution amongst different operators. It is recommended to explore it in future study with adequate sample to make it statistically significant.

Orthodontic tooth movement is prone to relapse, adversely affecting resin bonded bridge survival (Garnett et al., 2006). Zalkind et al. reported higher rates of resin-bonded bridges debonding in patients following orthodontic treatment. They suggested extend the orthodontic retention period after orthodontic treatment for space retention stability (Zalkind et al., 2003). Orthodontic movement of abutments such as in space closure in the absence of crowding, de-rotation, space redistribution/creation, and overbite reduction in the absence of a stable occlusal stop, are particularly susceptible to relapse (Melrose and Millett, 1998; Carter et al., 2003). Post-orthodontic retention is hugely beneficial since it prevents relapse of the abutment teeth. Some authors suggest a six months full-time retention with a removable retainer, to be an acceptable protocol (Carter et al., 2003). This is a reasonable time, since periodontal and gingival tissues need at least six months after treatment to re-organize, due to a "considerable residual may remain in the tissues of the periodontium after tooth movement" (Reitan, 1967; Moss, 1980).

Several studies reported cantilever resin bonded bridges replacing single missing teeth to perform better than resin bonded bridges with end abutment design (Gilmour and Ali, 1995; Djemal et al., 1999). In the current study, there was no difference in success between the two designs, in agreement with other studies (Chai et al., 2005; Wyatt, 2007; Allen et al., 2016).

As previously highlighted RBB was provided for these patients as a final restoration; accordingly, 41 out of 51 bridges had some form of tooth preparation made, with ten cases no documentation to that effect. Success seems to increase if tooth preparation were performed; and might further explain the higher failure rate in the current study as compared to the Allen et al. study (Allen et al., 2016). A recent cohort study reported a survival rate for anterior RBB with described tooth preparation designs (Abuzar et al., 2018).

The bridges that failed in this study did not show evidence of moisture control (not specified patients' records). Rubber dam use during the bonding procedure has a detrimental effect on performance (Chan and Barnes 2000; Morgan et al., 2001). However, placement of rubber dam in a young patient maybe awkward, due to short clinical crowns, minimal undercuts or immature gingival architecture and might hence explain why it was not used in these cases (Garnett et al., 2006).

Regarding the bridge design previous and current study recommends cantilever resin bonded bridges replacing single missing teeth perform better than resin bonded bridges with end abutment design (Gilmour and Ali, 1995; Djemal et al., 1999; Chan and Barnes, 2000; Durey et al., 2011). In some patient with hypodontia sufficient surface area for retention can only be gained by using one abutment at either end of the span as the abutment teeth are small, accordingly a fixed-fixed design may be the most appropriate (Garnett et al., 2006), and it is essential that the contact in excursive movements and intercuspation should be on the retainer only (Djemal et al., 1999).

Success seems to increase if tooth preparation were performed as surface area for retention is increased (Durey et al., 2011; Allen et al., 2016) It is accepted that 180° wrap-around retainers constitute the ideal design, but it must be followed with the aesthetic demands. Retainers on posterior teeth may be extended to include coverage of the palatal and lingual cusps and a proportion of the occlusal surface (Walls et al., 2002; Durey et al., 2011).

The location of a resin bonded bridges has an impact on success; mandibular bridges had been reported to have a higher failure (Creugers et al., 1998; De Kanter et al., 1998; Pjetursson et al., 2008). The effect of location could not be demonstrated in this study; since most of the bridges were located in the maxillary anterior region, in agreement with other studies (Probster and Henrich, 1997; Djemal et al., 1999). Similarly, the influence of span length on success did not seem to affect. Occlusal factors and para functional activity effects have also been emphasized (Boening, 1996; Morgan et al., 2001); the present study reports no significant adverse effects of pontic occlusal contacts on survival.

Patients' satisfaction evaluation is essential since it allows patients to express their views regarding treatment. It also gives the profession an insight into the suitability and acceptance of treatment from the patient perspective. Generally, there was a high level of satisfaction in agreement with

Djemalet al. (1999). Furthermore, resin bonded bridges have been reported to have a positive impact on oral health-related quality of life of patients with hypodontia (Anweigi et al., 2013). Patients with failed bridges were dissatisfied with the treatment and indicated that they would not like to go through this treatment again, and this was clear in the VAS. Therefore, patients' satisfaction with resin bonded bridges was directly influenced by failure.

This study also considered resin-bonded bridges as an adequate treatment option for replacing congenitally missing teeth in agreement with Abuzar and the study group who supported using the anterior RBB as a long-term restoration to replace anterior teeth in both arches (Abuzar et al., 2018).

## 5. Conclusions

Within the limitations of this study over seven-year period, the overall survival of resin bonded bridges in patients with hypodontia was 86%. The effect of age, gender, operator and experience, bridge location, design of the bridge and span length and moisture control, could not be demonstrated.

The effect of post-orthodontic retention, the presence of occlusal contacts on the pontic, or habits, could not be demonstrated.

A higher percentage of patients with hypodontia expressed satisfaction with resin bonded bridges. Thus, in replacing congenitally missing teeth for patients with hypodontia resin-bonded bridges would be an acceptable treatment option.

## Acknowledgement

The authors gratefully acknowledge the intellectual support given by Prof. Allen. P.F and Dr Ziada.H towards the development of this manuscript.

## Declaration of Competing Interest

None of the authors that were a part of the study in any capacity has any shape, size or form of conflict of interest to declare.

## Funding Sources

This research did not receive any specific grant from funding agencies in the public, commercial, or not-for-profit sectors.

## References

- Abuzar, M., Locke, J., Burt, G., Clausen, G., Escobar, K., 2018. Longevity of anterior resin-bonded bridges: survival rates of two tooth preparation designs. *Aust. Dent. J.*
- Allen, P.F., Anweigi, L., Ziada, H., 2016. A prospective study of the performance of resin bonded bridgework in patients with hypodontia. *J. Dent.* 50, 69–73.
- Anweigi, L., Allen, P.F., Ziada, H., 2013. The use of the Oral Health Impact Profile to measure the impact of mild, moderate and severe hypodontia on oral health-related quality of life in young adults. *J. Oral Rehabil.* 40 (8), 603–608.
- Audenino, G., Giannella, G., Morello, G.M., Ceccarelli, M., Carossa, S., Bassi, F., 2006. Resin-bonded fixed partial dentures: ten-year follow-up. *Int. J. Prosthodont.* 19 (1), 22–23.
- Boening, K.W., 1996. Clinical performance of resin-bonded fixed partial dentures. *J. Prosthet. Dent.* 76 (1), 39–44.
- Botelho, M.G., Nor, L.C., Kwong, H.W., Kuen, B.S., 2000. Two-unit cantilevered resin-bonded fixed partial dentures—a retrospective, preliminary clinical investigation. *Int. J. Prosthodont.* 13 (1), 25–28.
- Briggs, P., Dunne, S., Bishop, K., 1996. The single unit, single retainer, cantilever resin-bonded bridge. *Br. Dent. J.* 181 (10), 373–379.
- Carter, N.E., Gillgrass, T.J., Hobson, R.S., Jepson, N., Eechean, J.G., Nohl, F.S., Nunn, J.H., 2003. The interdisciplinary management of hypodontia: orthodontics. *Br. Dent. J.* 194 (7), 361–366.
- Chai, J., Chu, F.C., Newsome, P.R., Chow, T.W., 2005. Retrospective survival analysis of 3-unit fixed-fixed and 2-unit cantilevered fixed partial dentures. *J. Oral Rehabil.* 32 (10), 759–765.
- Chan, A.W., Barnes, I.E., 2000. A prospective study of cantilever resin-bonded bridges: an initial report. *Aust Dent J.* 45 (1), 31–36.
- Creugers, N.H., De Kanter, R.J., Van't Hof, M.A., 1997. Long-term survival data from a clinical trial on resin-bonded bridges. *J. Dent.* 25 (3–4), 239–242.
- Creugers, N.H., De Kanter, R.J., Verzijden, C.W., Van't Hof, M.A., 1998. Risk factors and multiple failures in posterior resin-bonded bridges in a 5-year multi-practice clinical trial. *J. Dent.* 26 (5–6), 397–402.
- De Kanter, R.J., Creugers, N.H., Verzijden, C.W., Van't Hof, M.A., 1998. A five-year multi-practice clinical study on posterior resin-bonded bridges. *J. Dent. Res.* 77 (4), 609–614.
- Djemalet al., Setchell, D., King, P., Wickens, J., 1999. Long-term survival characteristics of 832 resin-retained bridges and splints provided in a post-graduate teaching hospital between 1978 and 1993. *J. Oral Rehabil.* 26 (4), 302–320.
- Durey, K.A., Nixon, P.J., Robinson, S., Chan, M.Y., 2011. Resin bonded bridges: techniques for success. *Br Dent J.* 211 (3), 133–138.
- El-Mowafy, O., Rubo, M.H., 2000. Resin-bonded fixed partial dentures—a literature review with presentation of a novel approach. *Int J Prosthodont* 13 (6), 460–467.
- Garnett, M.J., Wassell, R.W., Jepson, N.J., Nohl, F.S., 2006. Survival of resin-bonded bridgework provided for post-orthodontic hypodontia patients with missing maxillary lateral incisors. *Br. Dent. J.* 201 (8), 527–534. discussion 525.
- Gilmour, A.S., Ali, A., 1995. Clinical performance of resin-retained fixed partial dentures bonded with a chemically active luting cement. *J. Prosthet. Dent.* 73 (6), 569–573.
- Hansson, O., Bergstrom, B., 1996. A longitudinal study of resin-bonded prostheses. *J. Prosthet. Dent.* 76 (2), 132–139.
- Hashem, A.A., O'Connell, B., Nunn, J., O'Connell, A., Garvey, T., O'Sullivan, M., 2010. Tooth agenesis in patients referred to an Irish tertiary care clinic for the developmental dental disorders. *J. Ir Dent Assoc* 56 (1), 23–27.
- Hill, H.K., Landwehr, D., Armstrong, S., 2009. A moderately favorable five-year success rate for resin-bonded bridges. *J. Am. Dent. Assoc.* 140 (6), 706–707.
- Hobkirk, J.A., Nohl, F., Bergendal, B., Storhaug, K., Richter, M.K., 2006. The management of ectodermal dysplasia and severe hypodontia. International conference statements. *J. Oral Rehabil.* 33 (9), 634–637.
- Hussey, D.L., Linden, G.J., 1996. The clinical performance of cantilevered resin-bonded bridgework. *J. Dent.* 24 (4), 251–256.
- Ibbetson, R., 2004. Clinical considerations for adhesive bridgework. *Dent Update* 31 (5), 254–256. 258, 260 passim.
- Jepson, N.J., Nohl, F.S., Carter, N.E., Gillgrass, T.J., Meechan, J.G., Hobson, R.S., Nunn, J.H., 2003. The interdisciplinary management of hypodontia: restorative dentistry. *Br. Dent. J.* 194 (6), 299–304.
- Lauwers, L., Wojcik, T., Delbarre, A., Movaghar, R., Ferri, J., 2009. Hypodontia: therapeutic strategy elaborated from 30 cases. *Rev. Stomatol. Chir. Maxillofac.* 110 (5), 263–268.

- Meechan, J.G., Carter, N.E., Gillgrass, T.J., Hobson, R.S., Jepson, N.J., Nohl, F.S., Nunn, J.H., 2003. Interdisciplinary management of hypodontia: oral surgery. *Br. Dent. J.* 194 (8), 423–427.
- Melrose, C., Millett, D.T., 1998. Toward a perspective on orthodontic retention?. *Am. J. Orthod. Dentofacial. Orthop.* 113 (5), 507–514.
- Morgan, C., Djemal, S., Gilmour, G., 2001. Predictable resin-bonded bridges in general dental practice. *Dent Update* 28 (10), 501–506. 508.
- Moss, J.P., 1980. The soft tissue environment of teeth and jaws. Experimental malocclusion: Parts 2 and 3. *Br. J. Orthod.* 7 (4), 205–216.
- Nunn, J.H., Carter, N.E., Gillgrass, T.J., Hobson, R.S., Jepson, N.J., Meechan, J.G., Nohl, F.S., 2003. The interdisciplinary management of hypodontia: background and role of paediatric dentistry. *Br. Dent. J.* 194 (5), 245–251.
- Pjetursson, B.E., Tan, W.C., Tan, K., Bragger, U., Zwahlen, M., Lang, N.P., 2008. A systematic review of the survival and complication rates of resin-bonded bridges after an observation period of at least 5 years. *Clin Oral Implants Res* 19 (2), 131–141.
- Probster, B., Henrich, G.M., 1997. 11-year follow-up study of resin-bonded fixed partial dentures. *Int. J. Prosthodont.* 10 (3), 259–268.
- Rashid, S.A., Al-Wahadni, A.M., Hussey, D.L., 1999. The periodontal response to cantilevered resin-bonded bridgework. *J. Oral Rehabil.* 26 (11), 912–917.
- Reitan, K., 1967. Clinical and histologic observations on tooth movement during and after orthodontic treatment. *Am J Orthod* 53 (10), 721–745.
- Robertsson, S., Mohlin, B., 2000. The congenitally missing upper lateral incisor. A retrospective study of orthodontic space closure versus restorative treatment. *Eur. J. Orthod.* 22 (6), 697–710.
- Shafi, I., Phillips, J.M., Dawson, M.P., Broad, R.D., Hosey, M.T., 2008. A study of patients attending a multidisciplinary hypodontia clinic over a five year period. *Br. Dent. J.* 205 (12), 649–652.
- Shroff, B., Siegel, S.M., Feldman, S., Siegel, S.C., 1996. Combined orthodontic and prosthetic therapy. Special considerations. *Dent. Clin. North Am.* 40 (4), 911–943.
- Verzijden, C.W., Creugers, N.H., Van't Hof, M.A., 1994. A meta-analysis of two different trials on posterior resin-bonded bridges. *J. Dent.* 22 (1), 29–32.
- Walls, A.W., Nohl, F.S., Wassell, R.W., 2002. Crowns and other extra-coronal restorations: resin-bonded metal restorations. *Br. Dent. J.* 193 (135–135), 141–142.
- Wyatt, C.C., 2007. Resin-bonded fixed partial dentures: what's new?. *J. Can. Dent. Assoc.* 73 (10), 933–938.
- Zalkind, M., Ever-Hadani, P., Hochman, N., 2003. Resin-bonded fixed partial denture retention: a retrospective 13-year follow-up. *J. Oral Rehabil.* 30 (10), 971–977.