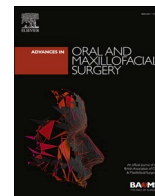



Contents lists available at ScienceDirect

## Advances in Oral and Maxillofacial Surgery

journal homepage: [www.sciencedirect.com/journal/advances-in-oral-and-maxillofacial-surgery](http://www.sciencedirect.com/journal/advances-in-oral-and-maxillofacial-surgery)

Case report

## Pathological fracture of mandible associated with an asymptomatic cholesterol granuloma

N. Usman<sup>a</sup>, M.U. Akhtar<sup>a</sup>, K. Ali<sup>b,\*</sup><sup>a</sup> Oral and Maxillofacial Surgery, de' Montmorency College of Dentistry, Lahore, Pakistan<sup>b</sup> Qatar University College of Dental Medicine, Qatar

## ARTICLE INFO

## Keywords:

Granuloma  
Mandible  
Fracture

## ABSTRACT

Cholesterol granuloma is a rare lesion in the maxillofacial and is often associated with benign cysts or tumors. It is caused by reaction to the foreign body and inadequate drainage of cholesterol crystals. We report here are case of cholesterol granuloma, identified following a pathological mandibular fracture in an adult male.

## 1. Introduction

Cholesterol granuloma (CG) is a benign lesion characterized by collection of numerous cholesterol clefts associated with foreign body giant cells, foam cells and hemosiderin-filled macrophages. CG commonly occurs in middle ear, lungs, brain, kidneys, mastoid process, breast, testis and apex of temporal bone pyramid [1,2]. The common reported sites for CG to occur in facial skeleton include maxillary antrum and frontal sinus [3,4]. Most cases occur in adult males and often there is a history of trauma. The clinical symptoms are nonspecific and depend on the location and size of the lesion. Although few cases of CG are reported in the maxilla, occurrence in the mandible is even rarer.

## 2. Case report

A 40-year-old male patient presented with discomfort on the lower jaw after he accidentally hit his face against a partially open door. Clinical examination showed a firm, tender swelling involving the left mandible body. A step deformity was palpable on the lower left mandibular border. The lower left second premolar (35) and first molar (36) were not present in the mouth. Orthopantomogram revealed well defined unilocular radiolucency with a radiolucent line extending to the inferior border of the mandible indicating a fracture of lower border of the mandibular body (Fig. 1).

The mandibular fracture was treated with open reduction and internal fixation using a five-hole titanium miniplate. An incisional biopsy of the radiolucent lesion was done at the same time the cystic cavity was marsupialized. Histopathological examination confirmed the diagnosis

of a benign cholesterol granuloma with cholesterol clefts, chronic inflammation and diffuse foreign body giant cells (Fig. 2). The lesion was enucleated 8 weeks later, and the postoperative healing was uneventful.

## 3. Discussion

CG is a rare lesion in the mandible and till now only eight cases of CG in the mandible have been reported in the literature, the first being reported by Hirschberg et al., in 1982 [5]. Kaffe et al., in 1984 reported a case of cholesterol granuloma in association with a maxillary odontoma [6]. CGs have also been found in association with several odontogenic pathologies such as radicular cyst, dentigerous cyst, odontogenic keratocyst or ameloblastoma [7]. However, this is perhaps the first case which reports a cholesterol granuloma of the mandible presenting as a pathological mandibular fracture. It has been suggested that CG is formed due to irritant effect of accumulated cholesterol crystals as a result of breakdown of blood, inflammatory tissue or exudate [8]. When hemorrhage occurs, erythrocyte disintegration produces cholesterol crystals, which accumulates within a confined space due to inadequate lymphatic drainage. If the hematoma is not cleared away, it may result accumulation to cholesterol crystals. Yamazaki et al. suggest that CG formation could be related to the presence of abundant perlecan, a basement membrane heparin sulfate proteoglycan, in the cystic wall of immature granulation tissue [9]. The patient discussed in this case report did not recall any previous history of trauma other than the facial injury following impact against a door. Therefore, it is not possible to ascertain if trauma was an etiological factor in the pathogenesis of this

\* Corresponding author. Qatar University College of Dental Medicine, Qatar.  
E-mail address: [ali.kamran@qu.edu.qa](mailto:ali.kamran@qu.edu.qa) (K. Ali).

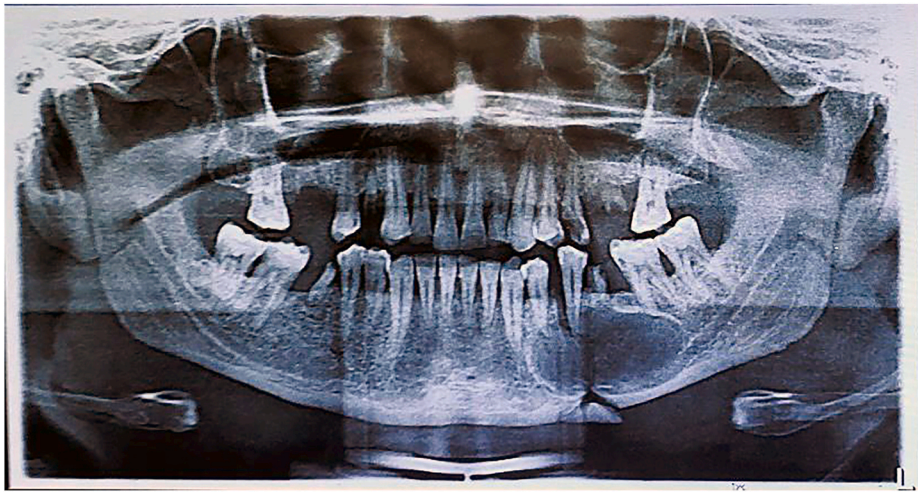
<https://doi.org/10.1016/j.adoms.2021.100197>

Received 3 October 2021; Accepted 4 October 2021

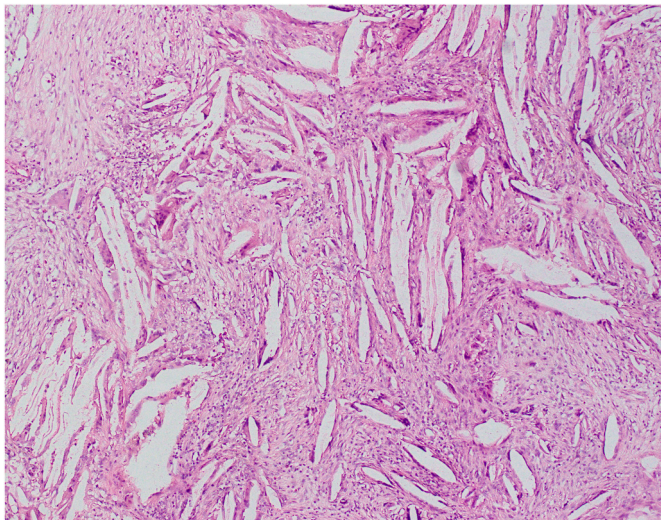
Available online 11 October 2021

2667-1476/© 2021 The Authors. Published by Elsevier Ltd on behalf of British Association of Oral and Maxillofacial Surgeons. This is an open access article

under the CC BY-NC-ND license (<http://creativecommons.org/licenses/by-nc-nd/4.0/>).



**Fig. 1.** Orthopantomogram (OPG) showing a pathological fracture of the left mandibular body secondary to the presence of large radiolucent lesion extending from the lower left first premolar to the lower left second molar.



**Fig. 2.** Photomicrograph of the histology of the mandibular lesion depicting typical features of a cholesterol granuloma with needle-shaped spaces (where cholesterol crystals have been dissolved during tissue processing), surrounded by chronic inflammation, giant cells. Hematoxylin and eosin (H&E). Magnification  $\times 100$ .

lesion. CG is amenable to conservative surgical enucleation and recurrence is not reported.

#### 4. Conclusion

CG is an uncommon benign lesion and represents a nonspecific

pathological reaction to cholesterol crystals rather than distinct a clinical or pathological entity. Although definitive diagnosis can be made only after histopathologic examination, correlation with clinical and radiographic features is warranted. The report also highlights the importance of regular dental visits for early identification of pathological jaw lesions.

#### References

- [1] Angeletti D, Pace A, Iannella G, Rossetti V, Colizza A, Di Gioia C, Magliulo G. Tympanic cholesterol granuloma and exclusive endoscopic approach. *Am J Case Rep* 2020;21:e925369.
- [2] Isaacson B. Cholesterol granuloma and other petrous apex lesions. *Otolaryngol Clin* 2015;48(2):361–73.
- [3] Paik SW, Lee YS, Park DJ, Hwang CS. Cholesterol granuloma of the maxillary sinus presenting as an antrochoanal polyp. *Ear Nose Throat J* 2021;100(5):340–2.
- [4] Marco M, Ida C, Francesco Luigi P, Giampiero M, Domenico L, Giuseppe B, Giuseppe P, Giulia Anna Carmen V. Cholesterol granuloma of the frontal sinus: a case report. *Case Rep Otolaryngol* 2012;2012:515986.
- [5] Hirshberg A, Dayan D, Buchner A, Freedman A. Cholesterol granuloma of the jaws: report of a case. *Int J Oral Maxillofac Surg* 1988 1;17(4):230–1.
- [6] Kaffe I, Littner MM, Buchner A, Friedman M. Cholesterol granuloma embedded in an odontoma of the maxilla. *J Oral Maxillofac Surg* 1984;42(5):319–22.
- [7] Lee JH, Alrashdan MS, Ahn KM, Kang MH, Hong SP, Kim SM. Cholesterol granuloma in the wall of the mandibular dentigerous cyst: a rare case report. *J Clin Exp Dent* 2010;2(2):e88–90.
- [8] Shrirao N, Mukherjee B, Krishnakumar S, Biswas J. Cholesterol granuloma: a case series & review of literature. *Graefes Arch Clin Exp Ophthalmol* 2016 Jan;254(1): 185–8.
- [9] Yamazaki M, Cheng J, Hao N, Takagi R, Jimi S, Itabe H, Saku T. Basement membrane-type heparan sulfate proteoglycan (perlecan) and low-density lipoprotein (LDL) are co-localized in granulation tissues: a possible pathogenesis of cholesterol granulomas in jaw cysts. *J Oral Pathol Med* 2004 Mar;33(3):177–84.