



Contents lists available at ScienceDirect

Journal of Pediatric Surgery Case Reports

journal homepage: www.elsevier.com/locate/epsc

Successful minimally invasive management of nonvascular grade IV blunt renal trauma with complete transection in a 7-year-old girl

Zlatan Zvizdic^a, Emir Milisic^a, Asmir Jonuzi^a, Melika Bukvic^b, Sanela Vesnic^b,
Lejla Milisic^b, Irmina Sefic Pasic^b, Semir Vranic^{c,*}

^a Clinic of Pediatric Surgery, University Clinical Center Sarajevo, Sarajevo, Bosnia and Herzegovina

^b Department of Radiology, University Clinical Center Sarajevo, Sarajevo, Bosnia and Herzegovina

^c College of Medicine, QU Health, Qatar University, Doha, Qatar

ARTICLE INFO

Keywords:

Grade IV renal Trauma
Complete renal transection
Minimally invasive management
Children

ABSTRACT

Non-operative treatment of high-grade renal trauma in hemodynamically stable children is gaining increasing acceptance nowadays. However, the management of isolated grade IV injuries, particularly those with complete renal fracture and separation of the poles with intact blood supply, is still controversial. Although such injuries have a decreased likelihood of spontaneous resolution, not all require open operative repair. They can be treated with a minimally invasive combination of internal and external drainage. Herein, we report a case of a 7-year-old girl who presented with a nonvascular grade IV blunt renal trauma with a complete renal transection, successfully treated with ureteral stent placement and ultrasound-guided percutaneous drainage of the perinephric urinoma. We also present a brief literature review on this rare lesion in children.

1. Introduction

Although rare (1–5% of all trauma patients), renal trauma is the most common urological injury and encompasses a wide range of injuries from parenchymal and vascular to collecting system lacerations [1]. Renal trauma is more likely to occur in children than in adults due to several anatomical features such as less perirenal fat, thinner abdominal muscles, lack of ossification of the rib cage, larger kidney size, and fetal kidney lobulations [2,3]. The predominant mechanism for renal injury in the pediatric population is blunt trauma (85–90% of cases), while the remaining result from penetrating injuries [4]. Blunt renal trauma usually results from sudden deceleration of the child's body during sports accidents, falls, or contact with blunt objects [5]. The American Association for the Surgery of Trauma (AAST) injury scale, most recently updated in 2018, classifies renal trauma into five grades of increasing severity [6]. While successful conservative management of low-grade (grade I–III) renal injuries is well established, consensus regarding the management of high-grade blunt renal trauma (HGBRT) has not been achieved [7]. HGBRT (grades IV–V) was traditionally treated surgically. However, the management of HGBRT has become increasingly conservative, with the objective of renal preservation [4]. Nowadays, surgical treatment is needed in approximately 5–10% of all renal injuries, and this rate is steadily declining due to the increased availability of minimally invasive treatment procedures and their usefulness in treating frequent complications of HGBRT, such as acute renal hemorrhage, persistent urinary extravasation, and/or symptomatic urinoma.

Abbreviations: AAST, American Association for the Surgery of Trauma; CT, Computed tomography; HBRT, High-grade blunt renal trauma; MRI, Magnetic resonance imaging; NOM, Non-operative management; RAE, Renal artery embolization; USG, Ultrasonography.

* Corresponding author. College of Medicine, QU Health, Qatar University, PO Box 2713, Doha, Qatar.

E-mail addresses: semir.vranic@gmail.com, svranic@qu.edu.qa (S. Vranic).

<https://doi.org/10.1016/j.epsc.2022.102455>

Received 29 August 2022; Accepted 3 September 2022

Available online 8 September 2022

2213-5766/© 2022 The Authors. Published by Elsevier Inc. This is an open access article under the CC BY license (<http://creativecommons.org/licenses/by/4.0/>).

Herein, we report a rare nonvascular grade IV blunt renal trauma with complete transection in a 7-year-old girl successfully managed with minimally invasive procedures.

2. Case report

A 7-year-old girl presented to our emergency department 3 h after falling on the curb with complaints of left-sided flank abdominal pain since the time of injury and with a history of passing red-colored urine. On physical examination, she was hemodynamically stable (blood pressure, 100/60 mmHg) and tachypneic (respiratory rate, 25 times/minute). A urethral catheter was inserted. No gross hematuria was observed. Microscopic hematuria was seen on urinalysis. Laboratory tests revealed normal hemoglobin (12.4 g/dl) and blood urea (24 mg/dl). Total and differential leukocyte counts and serum electrolytes were normal. The child was graded by emergency abdominal computer tomography (CT) with intravenous contrast medium at presentation. CT scan revealed complete right renal transection with the distraction of upper and lower poles (Fig. 1A). CT also documented contrast extravasation on the transection site with a substantial perinephric urinoma (Fig. 1B). There was no evidence of ureteropelvic junction injury. It was classified as a grade IV injury according to the AAST grading system [6].

The patient was initially managed conservatively by closely monitoring vital signs, abdominal girth, serial hemoglobin measurements, and broad-spectrum antibiotic cover. Over the next day, the girl developed abdominal distension and increased left flank abdominal tenderness. Due to the expanded left perinephric collection seen on ultrasonography (USG) (Fig. 2A), a 4.5 French ureteral double-J stent was passed retrogradely into the left renal pelvis under general anesthesia. The upper and lower pole moiety remained perfused via a branch vessel of the left renal artery, shown by the color Doppler USG (Fig. 2A). Symptoms gradually decreased in the following days, with USG finding that the left perinephric collection was not increasing in size. Microscopic hematuria improved and did not recur over the subsequent period. The child's general condition allowed the resumption of oral feeding and withdrawal of total parenteral nutrition. However, due to the worsening left flank, abdominal pain, and fevers on the eleventh day after the trauma, USG and CT urography were performed and showed enlargement of the perirenal urinoma, as well as a coiled stent, which migrated into urinoma (Fig. 2B). The ureteral stent was replaced with a new one, which was placed adequately (Fig. 2C). Ultrasound-guided percutaneous drainage of the perinephric urinoma with pigtail catheter insertion was immediately performed, and approximately 900 ml of amber-colored fluid was drained. In the next 12 days, the drainage rate gradually decreased, and the pigtail ceased to drain and was removed after 14 days. The girl was discharged on day 28 and readmitted three weeks later when the ureteral stent was removed. Follow-up magnetic resonance imaging (MRI) urography (Fig. 3A) and color Doppler USG (Fig. 3B) showed a slightly less perfused left kidney but functional without contrast extravasation. No signs of hypertension or hydronephrosis were noted on follow-up examinations.

3. Discussion

This case highlights successful, minimally invasive management of nonvascular grade IV blunt renal trauma with complete transection in a pediatric patient. It also summarizes the evidence regarding the clinical effectiveness of minimally invasive management rather than open surgery in pediatric higher grades nonvascular renal injuries not responding to non-operative management (NOM).

A growing body of evidence shows that a primary non-operative approach to the management of HGBRT can be effective in salvaging renal units, resulting in a reduced nephrectomy rate [4,8]. Hemodynamic status is the most important parameter for deciding on surgical intervention in children with renal trauma. In case of hemodynamic instability or concurrent penetrating intra-abdominal injury, emergency surgical interventions may be required [9]. In all other cases, a conservative approach should be the first preferred method of treatment in every grade of renal trauma that can occur in children [10]. In a systematic review that analyzed 95 pediatric patients with grade IV renal trauma, Umbreit et al. found that a non-operative approach was possible in 72% of cases [7].

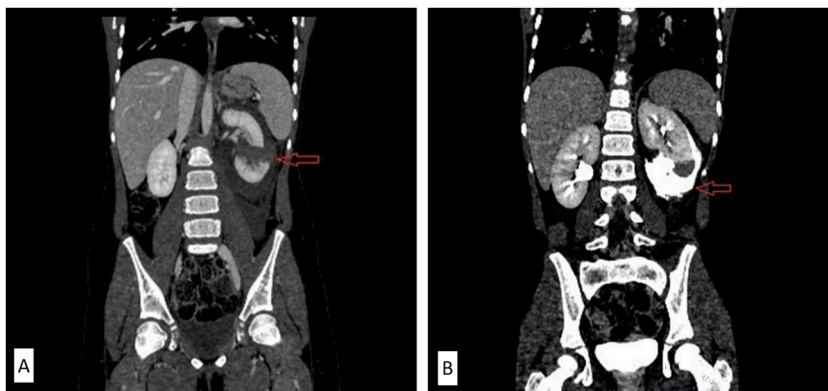


Fig. 1. A–B: A: Initial coronal CT in portal venous phase revealed a complete transection of the left kidney with the distraction of the poles (red arrow); B: Delayed phase at initial CT was done to assess the injury of the collecting system of the left kidney and showed extravasation of contrast with the presence of perinephric urinoma (red arrow). (For interpretation of the references to color in this figure legend, the reader is referred to the Web version of this article.)

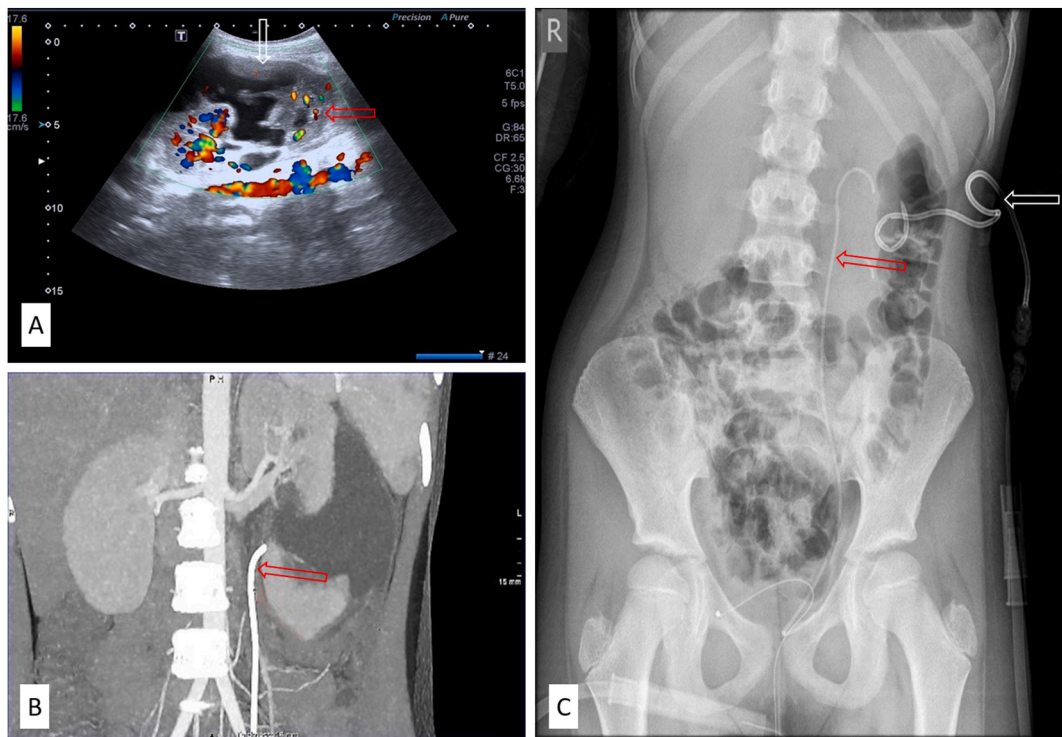


Fig. 2. A–C: (A): Follow-up was done by color Doppler ultrasonography, revealing a perinephric collection/urinoma (white arrow) with preserved vascularization of both poles of the left kidney (red arrow); (B): CT urography was also done, and migration of the stent was observed; (C): Percutaneous drainage catheter was inserted to evacuate enlarged urinoma. The stent was reinserted. (For interpretation of the references to color in this figure legend, the reader is referred to the Web version of this article.)

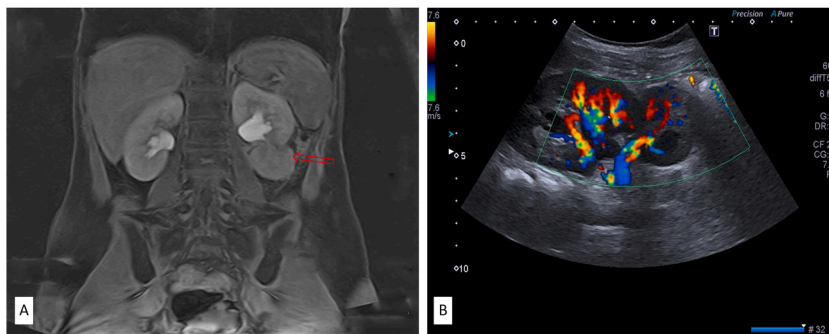


Fig. 3. A–B: (A): MRI urography was done with a post-contrast MR image showing mild hypoperfusion of the lower pole of the left kidney (red arrow); (B): A subsequent color Doppler ultrasonography confirmed the MRI urography findings. (For interpretation of the references to color in this figure legend, the reader is referred to the Web version of this article.)

Similarly, on a sample of 10 injured children with grade IV renal trauma, Rogers et al. reported a success rate of NOM of 80% [11]. More recently, LeeVan et al. pooled data from 27 studies and found that 204 of 234 (87%) children with grade IV renal injuries were initially managed conservatively with a 90% success rate without the need for subsequent surgical intervention [12]. A definition of conservative management varies in the literature, with minimally invasive procedures being variably defined as conservative or operative/interventional management [12]. However, the prevailing opinion is that minimally invasive procedures such as percutaneous drainage, ureteral stent placement, and therapeutic renal artery embolization (RAE) belong to conservative management, as well as observation itself [12].

There is currently no consensus on the optimal timing of minimally invasive interventions, particularly in isolated grade IV renal injuries. According to limited data from the literature, extremely rare cases of grade IV renal injuries with complete fracture and separation of the poles but with intact blood supply, as in our case, should be treated with early minimally invasive interventions due to the low probability of spontaneous resolution of this subgroup of renal traumas [13]. We confirm the effectiveness of this approach in our case.

Due to documented residual morphological changes in almost all children with high-grade renal injury with no late functional loss, a prolonged follow-up is warranted to assess the risk of progression of these abnormalities [14].

In conclusion, isolated grade IV renal injuries with complete fracture and separation of the poles but with intact blood supply can be successfully treated with early minimally invasive procedures. A prolonged follow-up is warranted due to the timely detection of possible progression of residual morphological changes in the affected kidneys.

Patient consent

Consent to publish the case report was obtained from the patient's mother.

Authorship

All authors attest that they meet the current ICMJE criteria for authorship.

Funding

The article-processing fee was covered by the Qatar National Library (QNL).

Declaration of competing interest

The authors declare that they have no known competing financial interests or personal relationships that could have appeared to influence the work reported in this paper.

References

- [1] Serafetinides E, Kitrey N.D, Djakovic N, Kuehhas F.E, Lumen N, Sharma D.M, et al. Review of the current management of upper urinary tract injuries by the EAU Trauma Guidelines Panel. *Eur Urol* 2015;67(5):930–6.
- [2] Brown S.L, Elder J.S, Spirmak J.P. Are pediatric patients more susceptible to major renal injury from blunt trauma? A comparative study. *J Urol* 1998;160(1): 138–40.
- [3] Grimsby G.M, Voelzke B, Hotaling J, Sorensen M.D, Koyle M, Jacobs M.A. Demographics of pediatric renal trauma. *J Urol* 2014;192(5):1498–502.
- [4] Buckley J.C, McAninch J.W. Pediatric renal injuries: management guidelines from a 25-year experience. *J Urol* 2004;172(2):687–90. ; discussion 90.
- [5] Radmayr C, Oswald J, Muller E, Holtl L, Bartsch G. Blunt renal trauma in children: 26 years clinical experience in an alpine region. *Eur Urol* 2002;42(3): 297–300.
- [6] Kozar R.A, Crandall M, Shanmuganathan K, Zarzaur B.L, Coburn M, Cribari C, et al. Organ injury scaling 2018 update: spleen, liver, and kidney. *J Trauma Acute Care Surg* 2018;85(6):1119–22.
- [7] Umbreit E.C, Routh J.C, Husmann D.A. Nonoperative management of nonvascular grade IV blunt renal trauma in children: meta-analysis and systematic review. *Urology* 2009;74(3):579–82.
- [8] Henderson C.G, Sedberry-Ross S, Pickard R, Bulas D.I, Duffy B.J, Tsung D, et al. Management of high grade renal trauma: 20-year experience at a pediatric level I trauma center. *J Urol* 2007;178(1):246–50. ; discussion 50.
- [9] Zvizdic Z, Popovic N, Milisic E. Primary operative renal salvage of grade-4 blunt renal injury: a case report. *Eastern J Med* 2013;18(2):81–3.
- [10] Pirincci N, Kaba M, Gecit I, Gunes M, Tanik S, Ceylan K. Conservative approach in the treatment of renal trauma in children. *Urol Int* 2014;92(2):215–8.
- [11] Rogers C.G, Knight V, MacUra K.J, Ziegfeld S, Paidas C.N, Mathews R.I. High-grade renal injuries in children--is conservative management possible? *Urology* 2004;64(3):574–9.
- [12] LeeVan E, Zmora O, Cazzulino F, Burke R.V, Zagory J, Upperman J.S. Management of pediatric blunt renal trauma: a systematic review. *J Trauma Acute Care Surg* 2016;80(3):519–28.
- [13] Healy C, Hobeldin M, Mahomed A. Conservative management of grade 1V renal injury with complete transection: a case report. *Cases J* 2008;1(1):129.
- [14] El-Sherbiny M.T, Aboul-Ghar M.E, Hafez A.T, Hammad A.A, Bazeed M.A. Late renal functional and morphological evaluation after non-operative treatment of high-grade renal injuries in children. *BJU Int* 2004;93(7):1053–6.